



PATIENT PRESENTING CLINICAL SIGNS

Maverick Abad History: V/D lethargy
Abnormal PE/Chem/CBC/UA Results: K 5.9 Chlor 127 Glob 2.0 ALP 229 Retics 139.7

SPECIES ULTRASONOGRAPHIC EXAMINATION OF THE ABDOMEN

Canine

Urinary System

BREED

The urinary bladder wall is normal in thickness, and the mucosal surface is smooth. The bladder is moderately distended. Luminal contents are mostly anechoic. No cystic calculi are observed. The region of the trigone and the proximal urethra, visible to a depth of 2 cm, are normal.

Mixed

SEX

The prostate is normal in size (0.63 cm in width) and shape. Parenchyma is homogenous. The prostatic urethra appears normal without evidence of dilation or obstruction.

Intact Male

AGE

The left kidney is normal in size (4.99 cm in length) with a normal shape, architecture and smooth peripheral margins. There is a normal 1:3 cortex to medulla ratio with normal corticomedullary distinction. There is no evidence of pyelectasia, nephroliths, infarcts or hydroureter. Renal vasculature is normal.

6 mo

WEIGHT

The right kidney is subjectively normal-in-size with a normal shape, architecture and smooth peripheral margins. There is a normal 1:3 cortex to medulla ratio with normal corticomedullary distinction. There is no evidence of pyelectasia, nephroliths, infarcts or hydroureter. Renal vasculature is normal.

19.2

Adrenal Glands

INTERPRETED BY

The left adrenal gland is subjectively normal in length with a slightly flattened contour (0.42 cm at cranial pole) (0.43 cm at caudal pole). Glandular echogenicity and detail are normal. The phrenicoabdominal vein and surrounding vasculature are normal.

Andrea Nicastro DVM
Diplomate ACVIM
(Sm Animal Internal Med)

The right adrenal gland is normal in size (1.02 cm at cranial pole) (0.47 cm at caudal pole) with a normal shape and homogenous parenchyma. The glandular echogenicity and detail are unremarkable. Capsule, cortex, and medullary definition are normal. The phrenicoabdominal vein and surrounding vasculature are normal.

IMAGING PERFORMED BY

Jenn

Spleen

HOSPITAL NAME

The spleen is normal in size (1.29 cm in width at the level of the hilus) with a normal capsular contour. There is appropriate echogenicity and echotexture. No focal lesions are observed. Splenic vasculature is normal.

Rockaway AH

Liver

REFERRING VET

The liver is subjectively normal in size with normal contours and structure. There is appropriate echogenicity and echotexture. No overt structural evidence of inflammatory, infiltrative, or regenerative pathology is evident. Vascular and biliary tracts are of normal volume with no evidence of congestion.

Dr Maniar

INVOICE

The gallbladder lumen is moderately distended. The wall is thin and smooth. Luminal contents are mostly anechoic. The cystic and common bile ducts are normal/not seen.

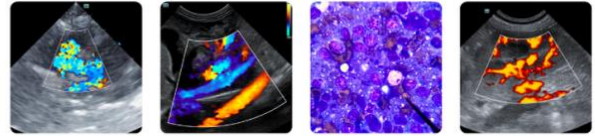
22511

Gastrointestinal

DATE

The gastric lumen is not distended. The gastric wall and pylorus are normal in thickness with a normal layering pattern. The pyloric outflow tract is patent. The small intestinal lumen is not dilated. The small intestinal wall is normal in thickness with a normal layering pattern and appropriate mural detail. Discreet masses are not identified. The colonic wall is normal. There is no evidence of an obstructive pattern.

2-5-26



PATIENT *Pancreas*

Maverick Abad

The region of the pancreas is isoechoic relative to surrounding omental fat. No obvious parenchymal abnormalities are observed. There is no evidence of regional inflammation or effusion.

SPECIES *Lymph nodes*

Canine

A few prominent mesenteric lymph nodes are visualized (one measuring 0.95 x 0.48 cm).

Free Abdomen

BREED

There is no obvious evidence of free fluid.

Mixed

ULTRASONOGRAPHIC FINDINGS

SEX

- The abdominal lymphadenopathy could be consistent with immunologic immaturity, reactive lymphadenitis or lymphoid hyperplasia. Infiltrative neoplasia is possible but considered unlikely.

Intact Male

- The slightly flattened left adrenal gland may be a normal variant for this patient or may be secondary atrophy (i.e., resulting from early hypoadrenocorticism).

AGE

6 mo

*An obvious cause for the patient's clinical signs is not definitively identified in this study. Considerations include dietary indiscretion, toxicity, infectious/parasitic disease, food allergy/intolerance, inflammatory bowel disease, underlying metabolic issue, other.

WEIGHT

19.2

INTERPRETATION OF THE FINDINGS & FURTHER RECOMMENDATIONS

INTERPRETED BY

Andrea Nicastro DVM
Diplomate ACVIM
(Sm Animal Internal Med)

- A fecal evaluation for ova and Giardia, along with parvovirus testing are recommended (if not already performed). Also consider prophylactic deworming with fenbendazole.
- A resting cortisol level to screen for hypoadrenocorticism. If resting cortisol level is < 2.0 mcg/dL, an ACTH stimulation test is recommended.
- Supportive care for gastroenteritis is recommended. If clinical signs persist despite medical management, further work-up may be indicated.

IMAGING PERFORMED BY

Jenn

HOSPITAL NAME

Rockaway AH

REFERRING VET

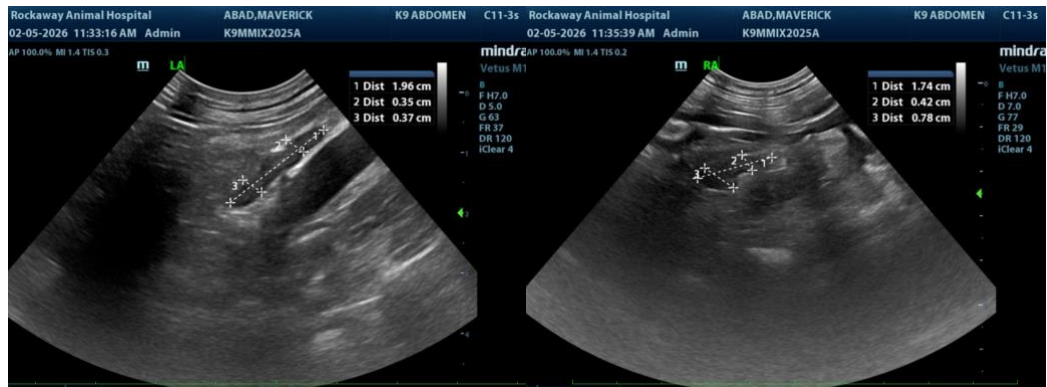Dr Maniar

INVOICE

22511

DATE

2-5-26





PATIENT

Maverick Abad

SPECIES

Canine

BREED

Mixed

SEX

Intact Male

AGE

6 mo

WEIGHT

19.2

INTERPRETED BY

Andrea Nicastro DVM
Diplomate ACVIM
(Sm Animal Internal Med)

IMAGING PERFORMED BY

Jenn

HOSPITAL NAME

Rockaway AH

REFERRING VET

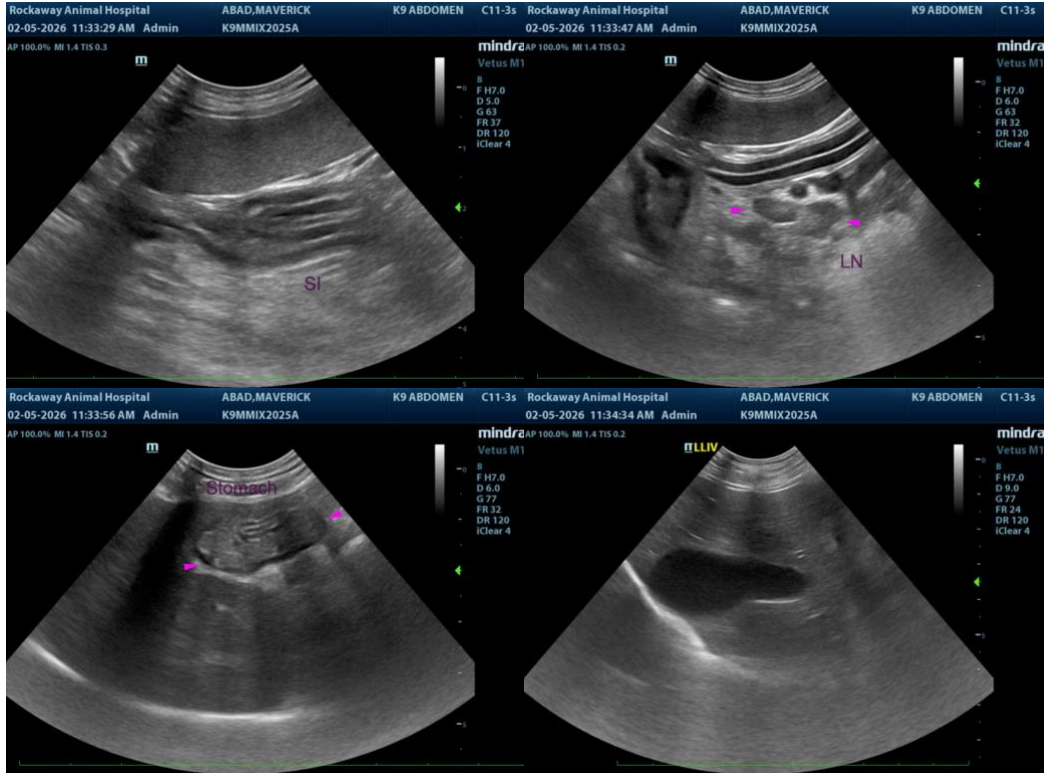
Dr Maniar

INVOICE

22511

DATE

2-5-26



The information and recommendations provided are based on the images presented by the referring veterinarian/sonographer. No evaluation can be communicated regarding pathology that was not visible in the image/video clips provided.

Thank you for this referral. If the clinical or image interpretation does not parallel your findings or if I can be of any further assistance, please contact me.

Andrea Nicastro, MPH, DVM, Diplomate DACVIM (Small Animal Internal Medicine)
info@SonoPath.com