

DATE PRESENTING CLINICAL SIGNS

2/4/2022 History: History of eating foreign material, may have ingested rubber bands and/or caulk.

PATIENT

Date of Previous IntraPet Ultrasound: 10-11-2021.
Sedation: Not required to complete full diagnostic ultrasound.
Stat Report: Not requested.

Murray Brill

Imaging Performed By: Andi Parkinson, RDMS.

SPECIES

Feline

ULTRASONOGRAPHIC EXAMINATION OF THE ABDOMEN

BREED

DSH

Urinary System

The urinary bladder, trigone, and pelvic urethra are normal in thickness and the mucosal surface is smooth. The bladder is moderately distended. A small amount of aggregated echogenic debris is suspended within the lumen. No masses, inflammatory changes or calculi are observed. Ureteral papillae and visualized portion of the proximal urethra, visible to a depth of 2 cm, are normal.

SEX

Male Neutered

The left kidney is normal size (4.08 cm in length); normal shape and architecture with smooth peripheral margins. There is a normal 1:3 cortex to medulla ratio with normal corticomedullary distinction. There is no evidence of pyelectasia, nephroliths, infarcts or hydroureter.

AGE

9-17-2019

The right kidney is normal size (4.24 cm in length); normal shape and architecture with smooth peripheral margins. There is a normal 1:3 cortex to medulla ratio with normal corticomedullary distinction. There is no evidence of pyelectasia, nephroliths, infarcts or hydroureter.

WEIGHT

9 Lbs.

Adrenal Glands

The region of the adrenal glands is evaluated. No obvious pathology is observed.

Spleen

The spleen is normal in size (0.90 cm in width at the level of the hilus) with a normal capsular contour. There is appropriate echogenicity and echotexture. No focal lesions are observed. Splenic vasculature is normal.

INTERPRETED BY

Andrea Nicastro,
DMV, Diplomate
DACVIM (Small
Animal
Internal Medicine)

Liver

The liver is subjectively normal in size with normal contours and structure. There is appropriate echogenicity and echotexture. No overt structural evidence of inflammatory, infiltrative, or regenerative pathology is evident. Vascular and biliary tracts are of normal volume with no evidence of congestion. No pathological hepatic lymphadenopathy observed.

HOSPITAL NAME

Timonium Animal
Hospital

The gall bladder lumen is moderately distended. The wall is thin and smooth. Luminal contents are anechoic. The cystic and common bile ducts are normal.

REFERRING VET

Dr. Stephens

Gastrointestinal

The stomach and intestine are free of stasis and exhibit normal peristaltic activity. The gastric lumen is not distended. The gastric wall and pylorus are normal in thickness with a normal layering pattern. The pyloric outflow tract is patent. The small intestinal lumen is not dilated. The small intestinal wall is diffusely thickened (up to 0.31 cm) with retention of the normal layering. There is disruption in the normal normal 1:3 muscularis to mucosal ratio with a >1: 1 ratio in some segments. Discreet masses are not identified. The ileoceocolic junction and colonic wall are normal. There is no evidence of an obstructive pattern.

INVOICE

10291

Pancreas

The pancreas is normal in size with normal peripheral contours. The pancreatic duct is normal. The base and limbs of the pancreas are isoechoic to surrounding omental fat. No focal lesions are observed. There is no evidence of peripancreatic inflammation or effusion.

Free Abdomen

The peritoneal cavity is normal. There is no evidence of inflammation or effusion. A few prominent mesenteric lymph nodes are normal visualized, the largest measuring 2.09 cm in length

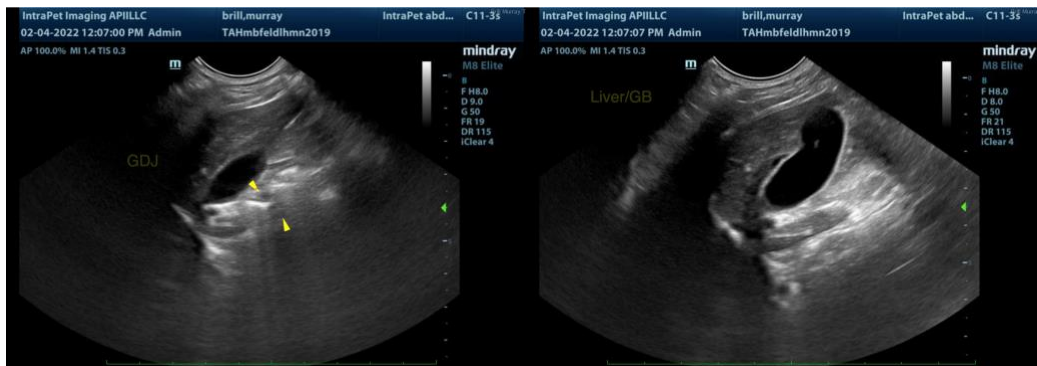ULTRASONOGRAPHIC FINDINGS

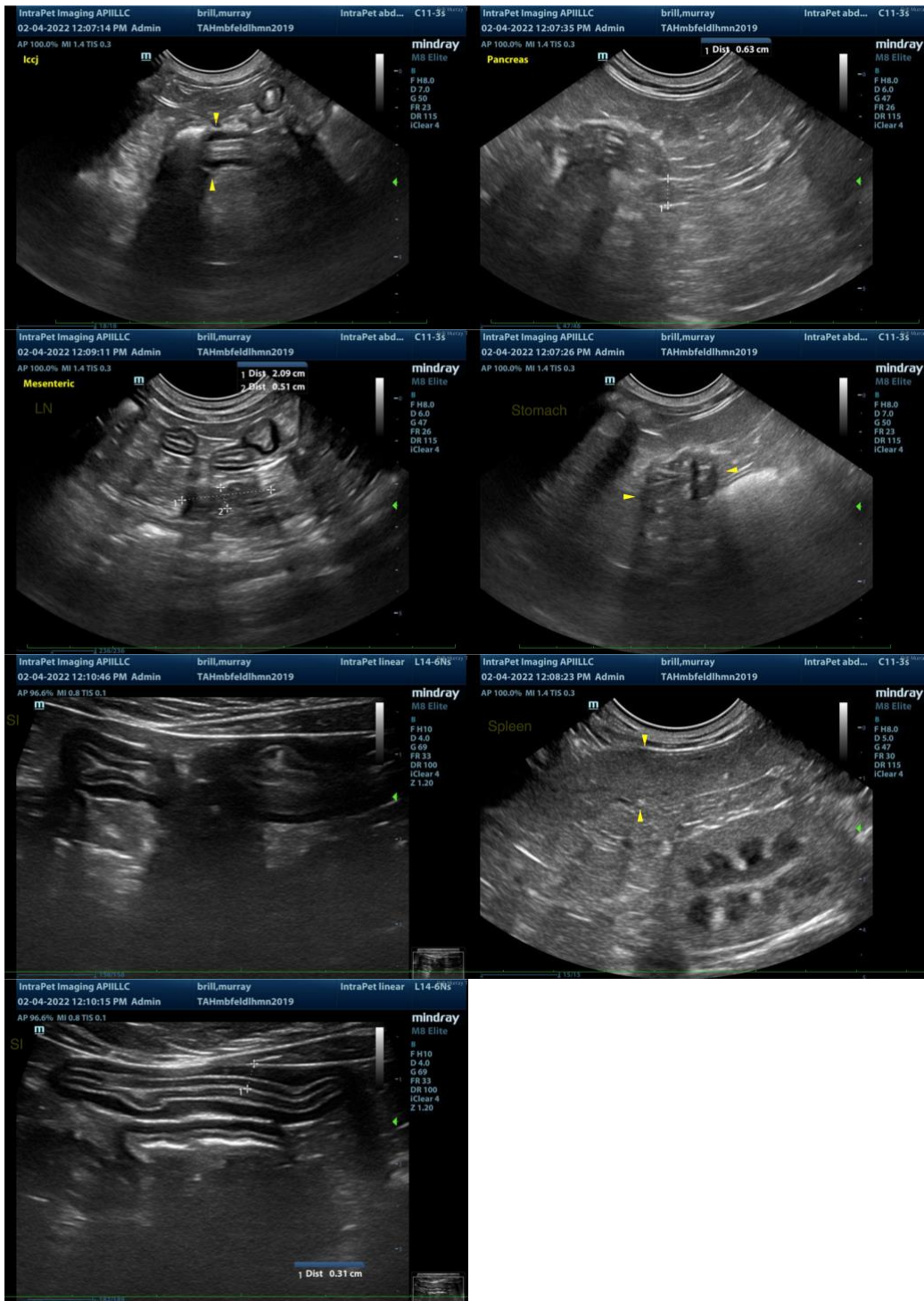
Primary Findings

- Small intestinal pattern consistent with inflammatory bowel disease or emerging lymphoma
- The prominent abdominal lymph nodes are most consistent with reactive lymphadenitis or lymphoid hyperplasia. Neoplastic infiltration is considered less likely.
- There is no obvious evidence of a foreign body/obstruction.

INTERPRETATION OF THE FINDINGS & FURTHER RECOMMENDATIONS

- If the patient is exhibiting chronic gastrointestinal signs, consider the following:
 1. GI Panel (send to Texas A&M)
 2. Fecal evaluation for ova and Giardia
 3. 6-week limited antigen diet trial +/- GI biopsies (endoscopic or surgical)





The information and recommendations provided are based on the images presented by the referring veterinarian/sonographer. No evaluation can be communicated regarding pathology that was not visible in the image/video clips provided.

Thank you for this referral. If the clinical or image interpretation does not parallel your findings or if I can be of any further assistance, please contact me.

Andrea Nicastro, DVM, Diplomate DACVIM (Small Animal Internal Medicine)
info@SonoPath.com