

DATE PRESENTING CLINICAL SIGNS

2/4/2022 History: ventral neck mass - 1 week duration.

PATIENT

Kai Shannahan

Current Medications: Clavamox 312.5mg PO q 12 hrs
Carprofen 50mg PO q 12 hrs.
Radiographs: Pending.
Date of Previous IntraPet Ultrasound: No previous IntraPet scans.
Sedation: Patient sedated with Dexdomitor.
Stat Report: Not requested.
Imaging Performed By: Andi Parkinson, RDMS.

SPECIES

Canine

**This study was limited to the thyroid region. There is a potential for pathology in organs that were not visualized.

BREED

Border Collie

LIMITED ULTRASONOGRAPHIC EXAMINATION

SEX

Male Neutered

A 4.77 x 3.83 cm well-circumscribed mildly heterogenous vascular mass is infiltrating the left thyroid lobe. The mass does not appear to grossly invade into the trachea. The right thyroid lobe is normal in size (2.81 x 0.44 cm), with normal curvilinear peripheral contours and homogenous parenchyma.

AGE

9-1-2014

An ultrasound-guided fine-needle aspirate of the thyroid mass was performed without incident.

ULTRASONOGRAPHIC FINDINGS

WEIGHT

43.6 Lbs.

- Left thyroid mass. Adenocarcinoma is the top differential.

INTERPRETATION OF THE FINDINGS & FURTHER RECOMMENDATIONS

INTERPRETED BY

Andrea Nicastro, DMV,
Diplomate DACVIM
(Small Animal
Internal Medicine)

- Three-view thoracic radiographs are recommended to assess for pulmonary metastases.
- Fine-needle aspirate of the draining lymph node is also recommended to assess for metastatic disease, particularly if cytology results confirm neoplasia.
- For further recommendations, consultation with a board-certified oncologist and surgeon should be considered.

HOSPITAL NAME

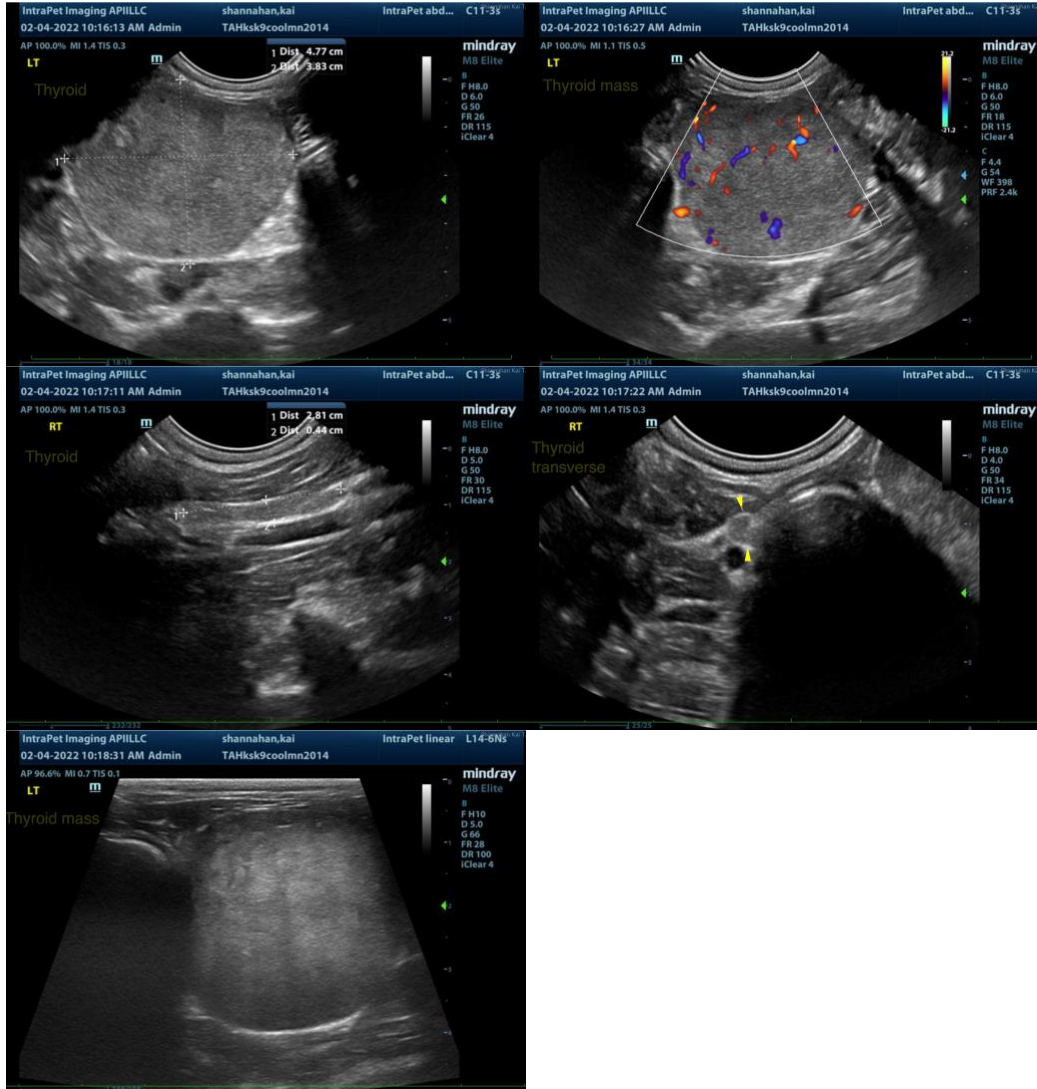
Timonium Animal
Hospital

REFERRING VET

Dr. McMichael

INVOICE

10287



The information and recommendations provided are based on the images presented by the referring veterinarian/sonographer. No evaluation can be communicated regarding pathology that was not visible in the image/video clips provided.

Thank you for this referral. If the clinical or image interpretation does not parallel your findings or if I can be of any further assistance, please contact me.

Andrea Nicastro, DVM, Diplomate DACVIM (Small Animal Internal Medicine)
info@SonoPath.com