**DATE PRESENTING CLINICAL SIGNS**

2/4/2022

History: Presenting Complaint: Pyometra Date: 02-04-2022 Notes: Had mammary cancer removed 2 years ago with RDVM noted it was growing back and planned to try to have removed again. Upon workup, about 3 days ago-- got cysto and noted UTI, started Amoxi. Continued to become lethargic and stopped eating. As per owner, slight increase in renal values. Hx of heat cycle about 3-4 weeks ago, owner noted-- keeps licking. Also, owner mentioned last year when cicadas here -- and pulled up tree had some respiratory issues-- had since resolved. Assessment: Pyometra-- strongly suspect- but is not severely enlarged on my scan. Mammary masses- concern about malignancy, they can spread into abdomen and/or chest. Renal changes-- could be in or go into ARF/ or. Acute on chronic from a pyo or from an anesthetic event. Cardiac murmur-- subclinical cardiac disease. We discussed workup results-- no obvious mets to chest or cardiac disease, mild increase in BUN-- and very suspicious structure in abdomen for pyometra. Offer to do procedure overnight- reviewed risks and concerns. Owner is worried he may put her through something unnecessarily. He wants to do scan to look for any signs mammary cancer has spread and confirm pyometra.

PATIENT

Daisy Blake

SPECIES

Canine

BREED

Beagle

SEX

Female Intact

Current Medications: Buprenex, Ampicillin, Cerenia.

Radiographs: heart may be a little plump, but feel is more confirmation as no change in vessels or edema suspicious fluid filled loop -- can see over bladder on lateral and on VD on right side.

Date of Previous IntraPet Ultrasound: No previous IntraPet scans.

Sedation: Not required to complete full diagnostic ultrasound.

Stat Report: Not requested.

AGE

2-3-2007

Imaging Performed By: Andi Parkinson, RDMS.

WEIGHT

30 Lbs.

Additional History: Hematocrit 27, nonregenerative anemia. Leukocytosis with a neutrophilia, lymphocytosis and monocytosis. BUN 33. ALP 323.

ULTRASONOGRAPHIC EXAMINATION OF THE ABDOMEN**INTERPRETED BY****Urinary System**

The urinary bladder, trigone, and pelvic urethra are normal in thickness and the mucosal surface is smooth. The bladder is moderately distended. A small amount of suspended echogenic debris is observed within the lumen. No masses, inflammatory changes or calculi are observed. Ureteral papillae and visualized portion of the proximal urethra, visible to a depth of 2 cm, are normal.

The left kidney is normal size (4.87 cm in length); with a slightly irregular shape. The cortex is variably thickened and hyperechoic. There is poor corticomedullary distinction. Hyperechoic shadowing and diverticular foci are visualized. Moderate pyelectasia is present (0.51 cm in the transverse plane). There is no evidence of hydroureter.

The right kidney is normal size (6.97 cm in length); with a slightly irregular shape. The cortex is variably thickened and hyperechoic. There is poor corticomedullary distinction. Hyperechoic shadowing and diverticular foci are visualized. Moderate pyelectasia is present (0.59 cm in the longitudinal plane). There is no evidence of hydroureter.

Adrenal Glands

The left adrenal gland is mildly enlarged (0.69 cm at cranial pole) (0.72 cm at caudal pole) (2.37 cm in length); normal shape; homogenous parenchyma. The glandular echogenicity and detail are unremarkable. Capsule, cortex, and medullary definition are normal. The phrenicoabdominal vein and surrounding vasculature are normal.

Andrea Nicastro, DMV,
Diplomate DACVIM
(Small Animal
Internal Medicine)

HOSPITAL NAME

Animal Emergency
Hospital

REFERRING VET

Dr. King

INVOICE

10281

The right adrenal gland is mildly enlarged (0.60 cm at cranial pole) (0.71 cm at caudal pole) (2.15 cm in length); normal shape; homogenous parenchyma. The glandular echogenicity and detail are unremarkable. Capsule, cortex, and medullary definition are normal. The phrenicoabdominal vein and surrounding vasculature are normal.

Spleen

The spleen is normal in size (1.71 cm in width at the level of the hilus) with a normal capsular contour. There is appropriate echogenicity and echotexture. No focal lesions are observed. Splenic vasculature is normal.

Liver

The liver is subjectively prominent in size with swollen curvilinear peripheral contours. The parenchyma is isoechoic relative to the spleen and exhibits mild heterogeneity. No distinct focal lesions are observed. Hepatic vasculature and biliary tracts are of normal volume with no evidence of congestion.

The gall bladder lumen is moderately distended. The wall is thin and smooth. A small to moderate amount of aggregated echogenic debris/sludge is observed within the lumen, some of which is suspended, some of which is adhered to the wall. The cystic and common bile ducts are normal.

Gastrointestinal

The gastric lumen is fluid distended and hypomotile. The gastric wall and pylorus are normal in thickness with a normal layering pattern. The pyloric outflow tract is patent. The small intestinal lumen is not dilated. The small intestinal wall thickness is normal with a normal layering pattern and appropriate mural detail. Discreet masses are not identified. The colonic wall is normal. No obstructive or overt infiltrative disease is noted.

Pancreas

The right limb of the pancreas is visible with normal curvilinear peripheral contours. The parenchyma is largely isoechoic relative to surrounding omental fat and slightly mottled in appearance. The pancreatic duct is visible but not overtly dilated. There is no evidence of peripancreatic inflammation or effusion.

Free Abdomen

The mesentery throughout the abdomen is hyperechoic. Trace free fluid is observed. The abdominal lymph nodes are normal/not visible.

Other

The left uterine horn is severely thickened (up to 2.05 cm in diameter), vascular and irregular with anechoic areas within the tissue. It is difficult to discern the left ovary from the left uterine horn, but it appears irregular. The mesentery surrounding the left uterine horn is hyperechoic. The right ovary is normal in size (1.42 x 1.14 cm) with a normal shape. Two follicles/cysts are observed within the parenchyma, one measuring 0.75 cm, the other measuring 0.40 cm. A 5.63 x 4.29 cm. The right uterine horn is mildly thickened (up to 0.68 cm in diameter). A small amount of fluid is observed within the lumen. The uterine body is mildly to moderately thickened (up to 0.69 cm).

An irregular heterogenous mammary mass with varying-sized fluid pockets is visualized. The mass is walled with variable thickness. The fluid pockets contain echogenic debris.

ULTRASONOGRAPHIC FINDINGS

Primary Findings

- The left uterine horn changes could be consistent with infiltrative neoplasia or a severe inflammatory process. Diffuse peritonitis is present, likely secondary to uterine pathology.

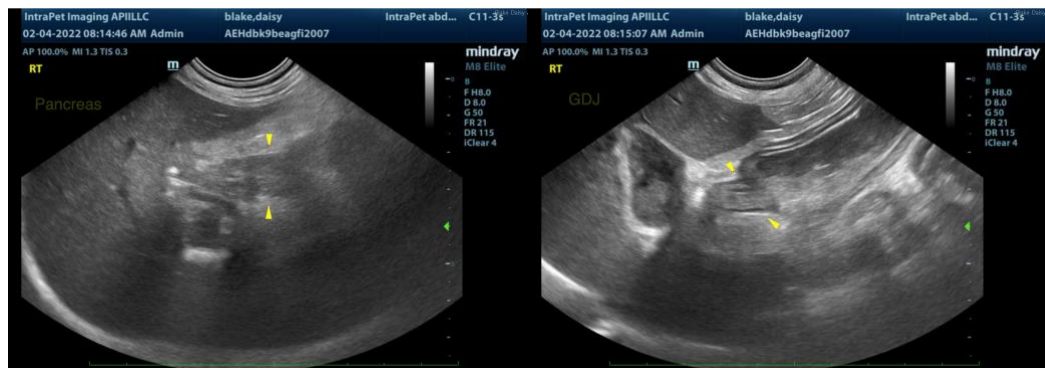
- Large mammary mass. Neoplasia with possible necrotic areas is suspected with a lower possibility of benign pathology
- Bilateral degenerative renal changes with pyelectasia

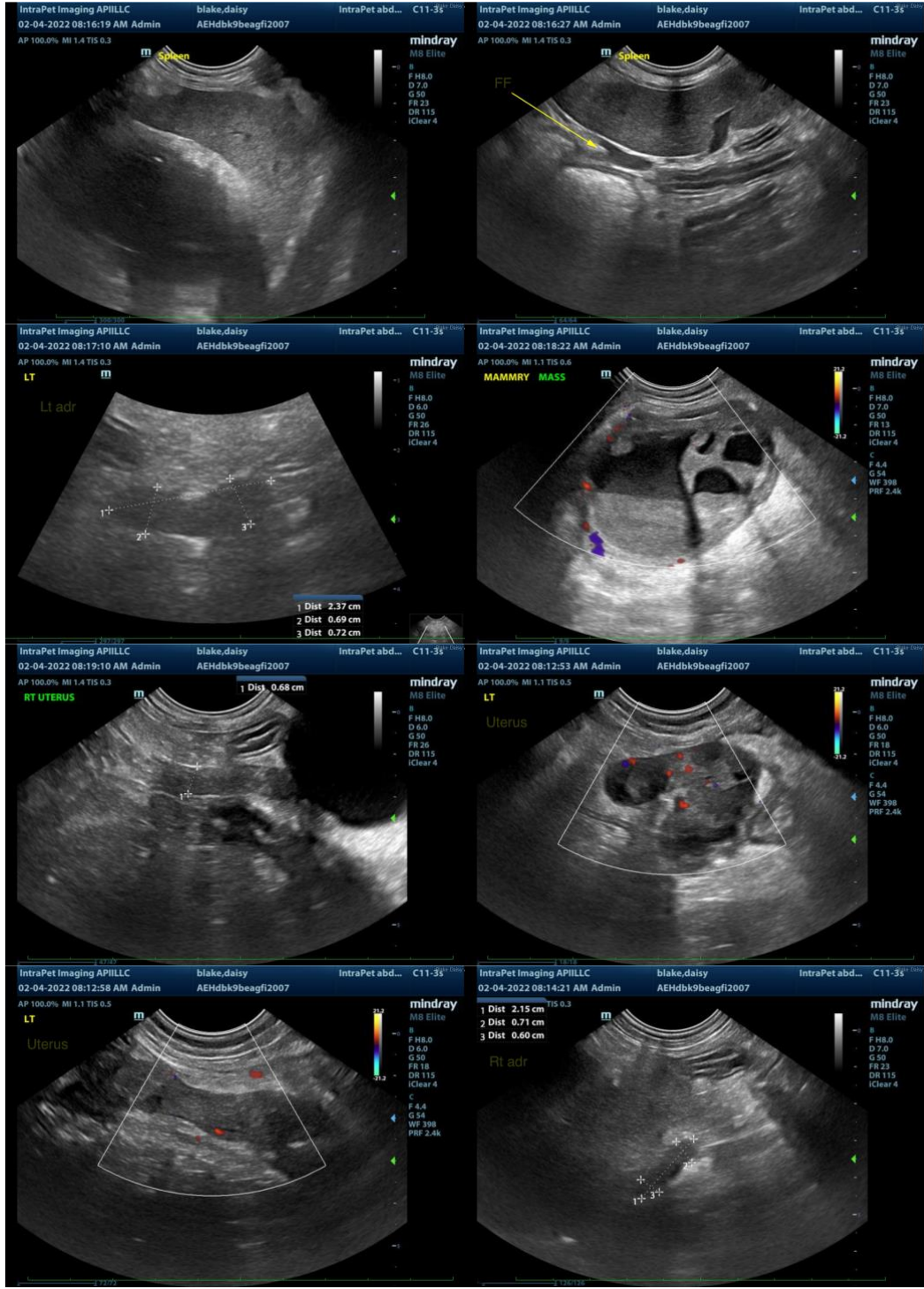
Secondary Findings

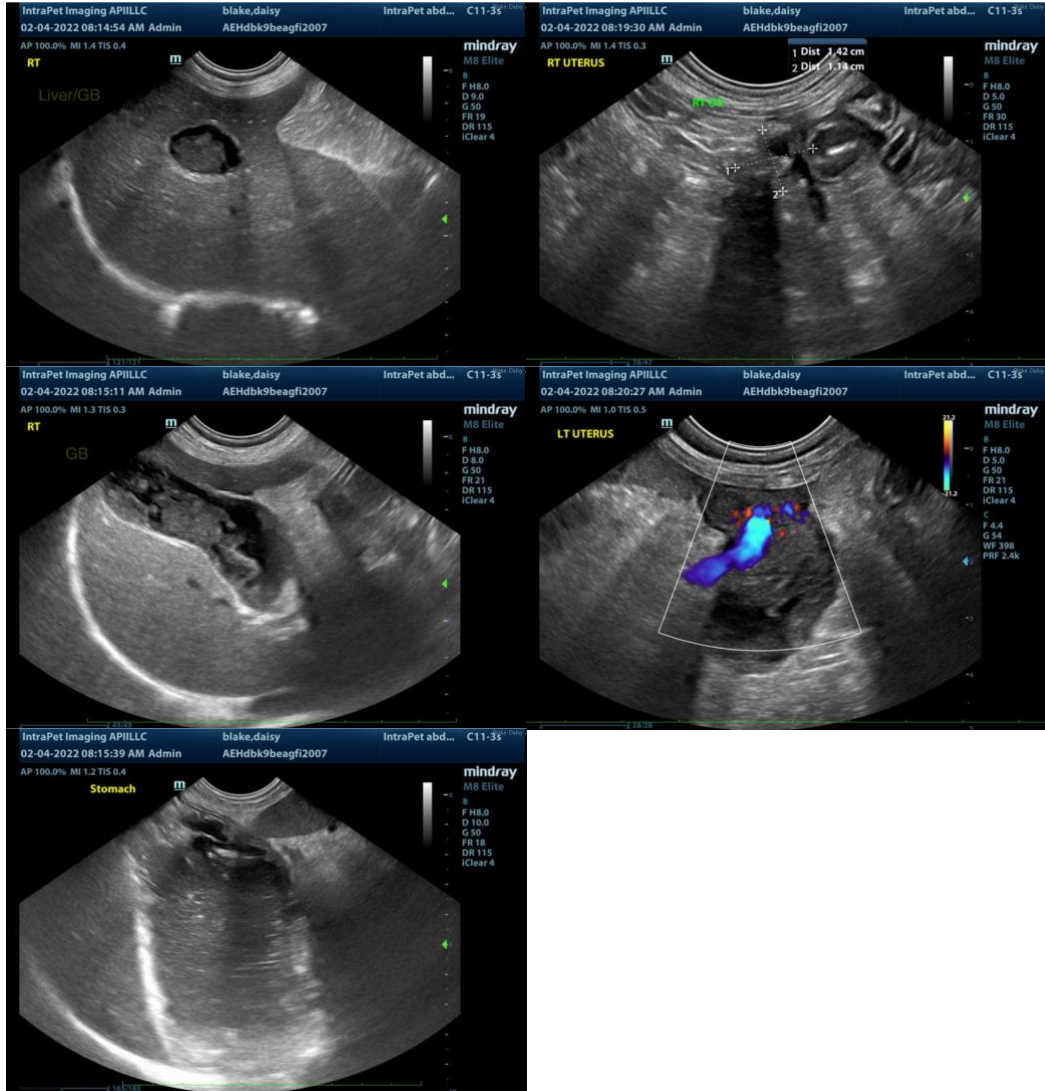
- The diffuse hepatic changes are non-specific and could be consistent with vacuolar hepatopathy, regenerative nodular hyperplasia, and/or age-related remodeling. Inflammatory and infiltrative disease are considered less likely.
- Gall bladder sludge, non-mucocele
- Age-related pancreatic remodeling
- Gastric ileus
- Mild bilateral adrenomegaly

INTERPRETATION OF THE FINDINGS & FURTHER RECOMMENDATIONS

- If an aggressive approach is desired, an ovariectomy with submission of the uterus and ovaries for histopathology is recommended, along with mammary mass removal. Otherwise, palliative care is recommended.
- Given the azotemia and sonographic renal changes, a urine culture and sensitivity, UPC (if proteinuria is present +/- baseline blood pressure measurement should also be considered.







The information and recommendations provided are based on the images presented by the referring veterinarian/sonographer. No evaluation can be communicated regarding pathology that was not visible in the image/video clips provided.

Thank you for this referral. If the clinical or image interpretation does not parallel your findings or if I can be of any further assistance, please contact me.

Andrea Nicastro, DVM, Diplomate DACVIM (Small Animal Internal Medicine)
info@SonoPath.com