



**PATIENT PRESENTING CLINICAL SIGNS**

Cassidy Jeffas History: liver lobectomy about 6 months ago to remove hepatic adenocarcinoma Recheck ultrasound  
Abnormal PE/Chem/CBC/UA Results: PE WNL BW pending prior elevation in liver values

**SPECIES ULTRASONOGRAPHIC EXAMINATION OF THE ABDOMEN**

Canine

**Urinary System**

The urinary bladder is moderately distended with anechoic urine. The apical wall is slightly thickened (0.33 cm). The wall tapers to a normal thickness as it extends towards the urinary bladder neck. The mucosal surface is smooth. No cystic calculi are observed. The region of the trigone and the visible portion of the proximal urethra are normal.

BREED

Mixed

SEX

The left kidney is normal size (6.95 cm in length); normal shape and architecture with smooth peripheral margins. There is a normal 1:3 cortex to medulla ratio with minimal loss of corticomedullary distinction. There is no evidence of pyelectasia, nephroliths, infarcts or hydroureter.

Spayed Female

AGE

The right kidney is normal size (6.19 cm in length); normal shape and architecture with smooth peripheral margins. There is a normal 1:3 cortex to medulla ratio with minimal loss of corticomedullary distinction. There is no evidence of pyelectasia, nephroliths, infarcts or hydroureter.

9 Years

**Adrenal Glands**

The left adrenal gland is normal size (0.72 cm at cranial pole) (0.69 cm at caudal pole) (2.69 cm in length); normal shape; homogenous parenchyma. The glandular echogenicity and detail are unremarkable. Capsule, cortex, and medullary definition are normal. The phrenicoabdominal vein and surrounding vasculature are normal.

WEIGHT

61 Lbs.

The right adrenal gland is normal size (1.10 cm at cranial pole) (0.68 cm at caudal pole) (3.19 cm in length); normal shape; homogenous parenchyma. The glandular echogenicity and detail are unremarkable. Capsule, cortex, and medullary definition are normal. The phrenicoabdominal vein and surrounding vasculature are normal.

**INTERPRETED BY**

Andrea Nicastro, DMV,  
Diplomate DACVIM  
(Small Animal  
Internal Medicine)

**Spleen**

The spleen is normal in size (1.93 cm at the level of the hilus) with a normal capsular contour. There is appropriate echogenicity and echotexture. No focal lesions are observed. Splenic vasculature is normal.

**IMAGING PERFORMED BY**

Dr. Scott

**Liver**

The liver is subjectively prominent in size with slightly swollen peripheral contours. The parenchyma is isoechoic relative to the spleen and diffusely mottled in appearance. No distinct focal lesions are observed. Hepatic vasculature and intrahepatic biliary tracts are of normal volume with no evidence of congestion.

**HOSPITAL NAME**

Ho Ho Kus VH

**REFERRING VET**

Dr. Eisenberg

**Gastrointestinal**

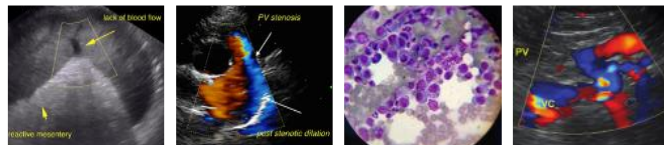
The stomach and intestine are free of stasis and exhibit normal peristaltic activity. The gastric lumen is mildly distended with ingesta. The gastric wall and pylorus are normal in thickness with a normal layering pattern. The small intestinal lumen is segmentally dilated with chyme. The small intestinal wall thickness is normal with a normal layering pattern and appropriate mural detail. Discreet masses are not identified. The colonic wall is normal. No obstructive or overt infiltrative disease is noted.

**INVOICE**

10280

**DATE**

2/4/22



**PATIENT**

**Pancreas**

Cassidy Jeffas

The region of the pancreas is isoechoic relative to surrounding omental fat. No obvious parenchymal abnormalities are observed. There is no evidence of regional inflammation or effusion.

**SPECIES**

**Free Abdomen**

Canine

The peritoneal cavity is normal. There is no evidence of inflammation or effusion. The abdominal lymph nodes are normal/not visible.

**ULTRASONOGRAPHIC FINDINGS**

**BREED**

**Primary Findings**

Mixed

- The diffuse hepatic parenchymal changes could be consistent with an age-related benign process (i.e., regenerative nodular hyperplasia, vacuolar hepatopathy). Alternatively, metastatic disease may be present, although this is considered less likely. Inflammatory disease and other hepatopathies are also possible. Correlation with the patient's bloodwork is recommended.

**SEX**

Spayed Female

**Secondary Findings**

**AGE**

9 Years

- Minor age-related renal changes.
- The mild urinary bladder wall thickening may be a normal variant for this patient or may represent low-grade cystitis. Correlation with clinical findings is recommended.

**WEIGHT**

61 Lbs.

**INTERPRETATION OF THE FINDINGS & FURTHER RECOMMENDATIONS**

**INTERPRETED BY**

- Three-view thoracic radiographs are recommended to assess for pulmonary metastases.
- A repeat abdominal ultrasound is recommended in 4-6 months to assess for recurrence of neoplasia (or sooner, if problems arise).

Andrea Nicastro, DMV,  
Diplomate DACVIM  
(Small Animal  
Internal Medicine)

**IMAGING PERFORMED BY**

Dr. Scott

**HOSPITAL NAME**

Ho Ho Kus VH

**REFERRING VET**

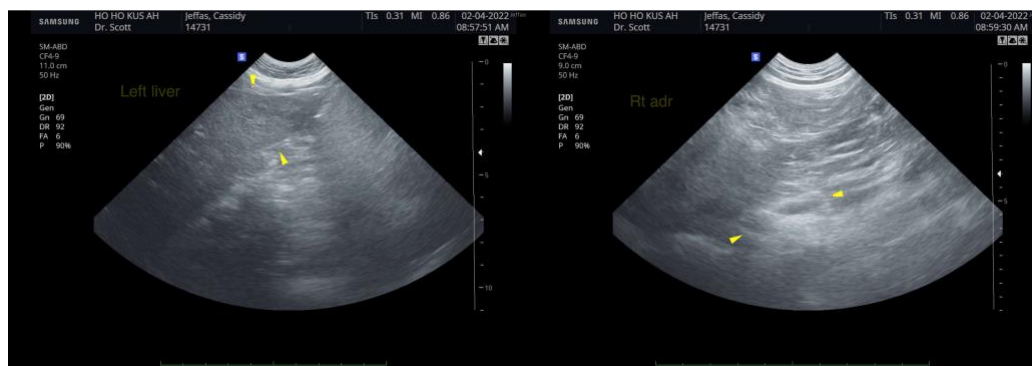
Dr. Eisenberg

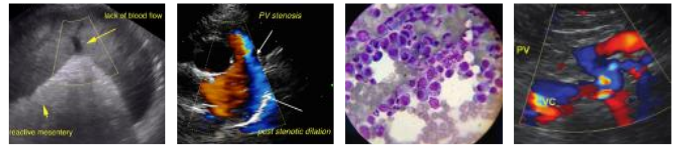
**INVOICE**

10280

**DATE**

2/4/22





**PATIENT**

Cassidy Jeffas

**SPECIES**

Canine

**BREED**

Mixed

**SEX**

Spayed Female

**AGE**

9 Years

**WEIGHT**

61 Lbs.

**INTERPRETED BY**

Andrea Nicastro, DMV,  
Diplomate DACVIM  
(Small Animal  
Internal Medicine)

**IMAGING PERFORMED BY**

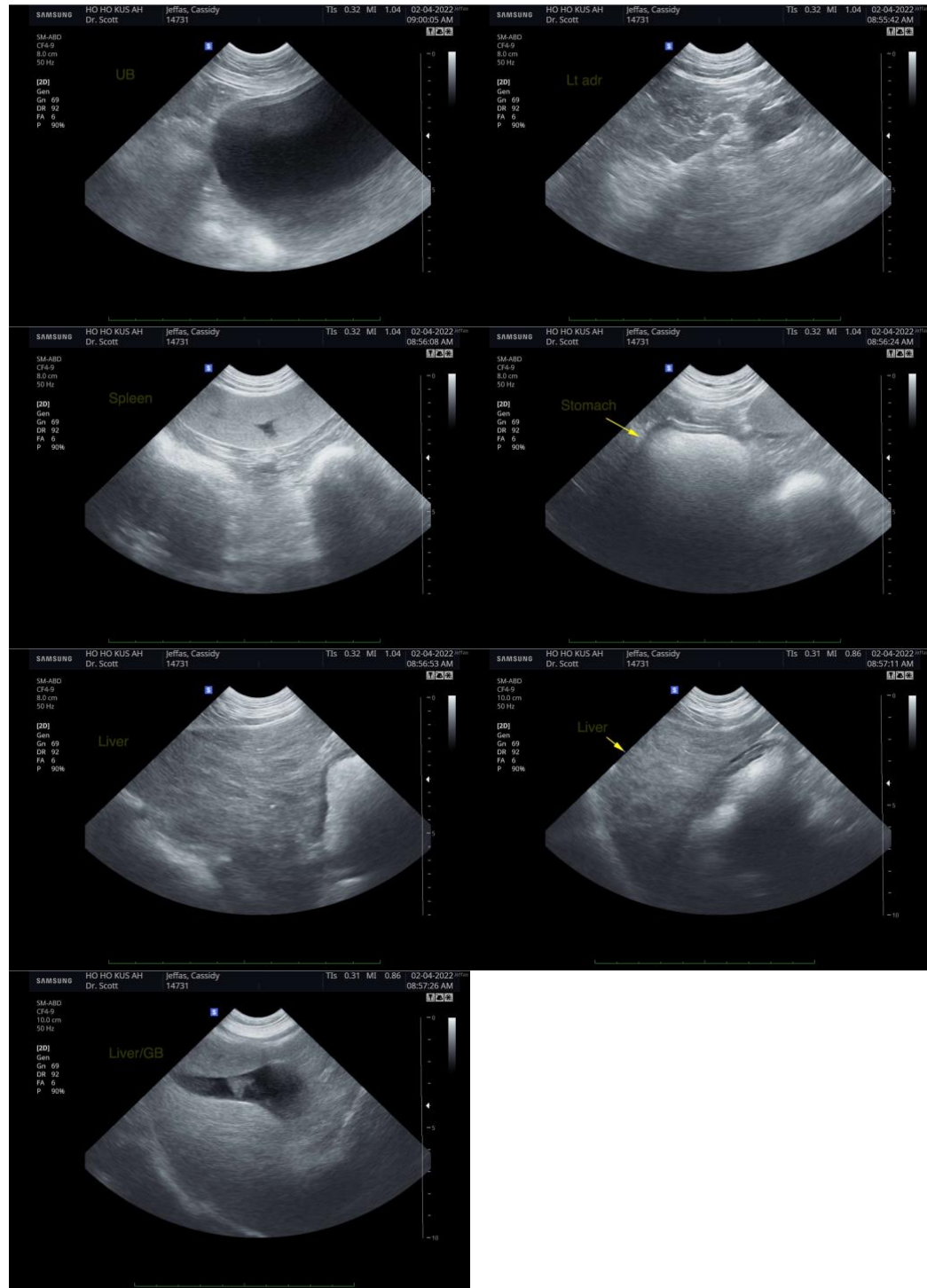
Dr. Scott

**HOSPITAL NAME**

Ho Ho Kus VH

**REFERRING VET**

Dr. Eisenberg



**INVOICE**

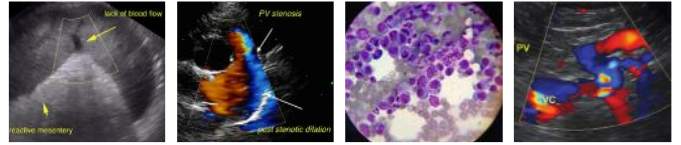
10280

**DATE**

2/4/22

The information and recommendations provided are based on the images presented by the referring veterinarian/sonographer. No evaluation can be communicated regarding pathology that was not visible in the image/video clips provided.

Thank you for this referral. If the clinical or image interpretation does not parallel your findings or if I can be of any further assistance, please contact me.



**PATIENT**

**Andrea Nicastro, DVM, Diplomate DACVIM (Small Animal Internal Medicine)**  
info@SonoPath.com

Cassidy Jeffas

**SPECIES**

Canine

**BREED**

Mixed

**SEX**

Spayed Female

**AGE**

9 Years

**WEIGHT**

61 Lbs.

**INTERPRETED BY**

Andrea Nicastro, DMV,  
Diplomate DACVIM  
(Small Animal  
Internal Medicine)

**IMAGING  
PERFORMED BY**

Dr. Scott

**HOSPITAL NAME**

Ho Ho Kus VH

**REFERRING VET**

Dr. Eisenberg

**INVOICE**

10280

**DATE**

2/4/22