



PATIENT

Cooper Manson

SPECIES

Canine

BREED

Yorkshire Terrier Mix

SEX

Intact Male

AGE

07/1/2022

WEIGHT

6.2 lbs

INTERPRETED BY

Andrea Nicastro, DVM,
Diplomate ACVIM
(Small Animal Internal
Medicine)

**IMAGING
PERFORMED BY**

Andrea Nicastro, DVM,
Diplomate ACVIM
(Small Animal Internal
Medicine)

HOSPITAL NAME

Flowertown AH

REFERRING VET

Dr. McLaughlin

INVOICE

12136

DATE

2.2.22

PRESENTING CLINICAL SIGNS

History: Recent inappetence. ADR.
Abnormal lab-work values: None
Current Medications: Frontline

ULTRASONOGRAPHIC EXAMINATION OF THE ABDOMEN

Urinary System

The urinary bladder wall is normal in thickness and the mucosal surface is smooth. The bladder lumen is moderately distended with anechoic urine. No masses, inflammatory changes or calculi are observed. Ureteral papillae and visualized portion of the proximal urethra, visible to a depth of 2 cm, are normal.

The prostate is normal in size (0.85 cm in width) and shape. Parenchyma is homogenous. The prostatic urethra appears normal without evidence of dilation or obstruction.

The left kidney is normal in size (3.40 cm in length) with a normal shape, architecture and smooth peripheral margins. There is a normal 1:3 cortex to medulla ratio with normal corticomedullary distinction. There is no evidence of pyelectasia, nephroliths, infarcts or hydronephrosis. Renal vasculature is normal.

The right kidney is normal in size (3.24 cm in length) with a normal shape, architecture and smooth peripheral margins. There is a normal 1:3 cortex to medulla ratio with normal corticomedullary distinction. There is no evidence of pyelectasia, nephroliths, infarcts or hydronephrosis. Renal vasculature is normal.

Adrenal Glands

The left adrenal gland is normal in size (0.37 cm at cranial pole) (0.33 cm at caudal pole) with a normal shape and homogenous parenchyma. The glandular echogenicity and detail are unremarkable. Capsule, cortex, and medullary definition are normal. The phrenicoabdominal vein and surrounding vasculature are normal.

The right adrenal gland is in normal size (0.76 cm at cranial pole) (0.37 cm at caudal pole) with a normal shape and homogenous parenchyma. The glandular echogenicity and detail are unremarkable. Capsule, cortex, and medullary definition are normal. The phrenicoabdominal vein and surrounding vasculature are normal.

Spleen

The spleen is normal in size (0.87 cm in width at the level of the hilus) with a normal capsular contour. There is appropriate echogenicity and echotexture. No focal lesions are observed. Splenic vasculature is normal.

Liver

The liver is subjectively normal in size with normal contours and structure. There is appropriate echogenicity and echotexture. No overt structural evidence of inflammatory, infiltrative, or regenerative pathology is evident. Vascular and biliary tracts are of normal volume with no evidence of congestion. No pathological hepatic lymphadenopathy observed. The portal vein to caudal vena cava ratio is approximately 1: 1.

The gall bladder lumen is distended. The wall is thin and smooth. Luminal contents are anechoic. The cystic and common bile ducts are normal/not seen.

Gastrointestinal

The stomach and intestine are free of stasis and exhibit normal peristaltic activity. The gastric lumen is not distended. The gastric wall and pylorus are normal in thickness with a normal layering pattern. The pyloric

outflow tract is patent. The small intestinal lumen is not dilated. The small intestinal wall thickness is normal with a normal layering pattern and appropriate mural detail. Discreet masses are not identified. The colonic wall is normal. There is no evidence of an obstructive pattern.

Pancreas

The pancreas is normal in size with normal peripheral contours. The pancreatic duct is normal. The base and limbs of the pancreas are isoechoic to surrounding omental fat. No focal lesions are observed. There is no evidence of peripancreatic inflammation or effusion.

Free Abdomen

The peritoneal cavity is normal. There is no evidence of inflammation or effusion. One to two prominent mesenteric lymph nodes are visualized (the largest measuring 2.32 cm in length).

Other

A brief echocardiogram reveals no evidence of pericardial effusion or obvious right atrial/auricular mass.

The testicles are subjectively normal in size and symmetrical with homogenous parenchyma. No focal lesions are observed.

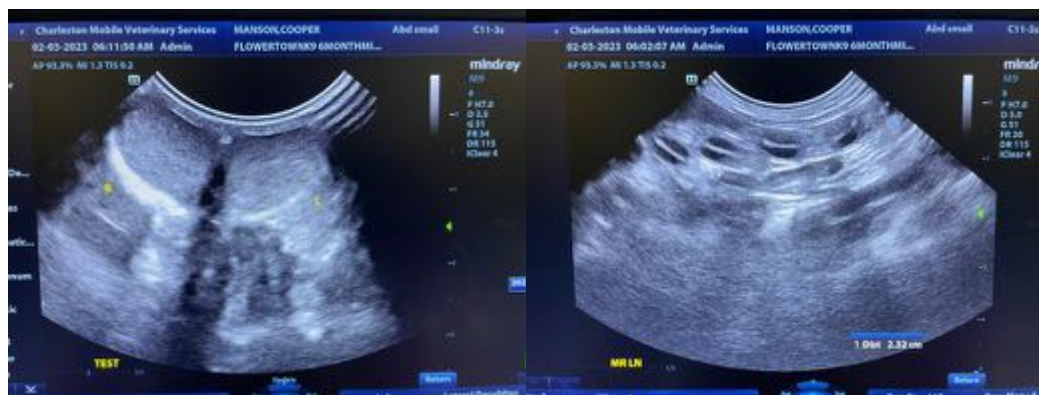ULTRASONOGRAPHIC FINDINGS

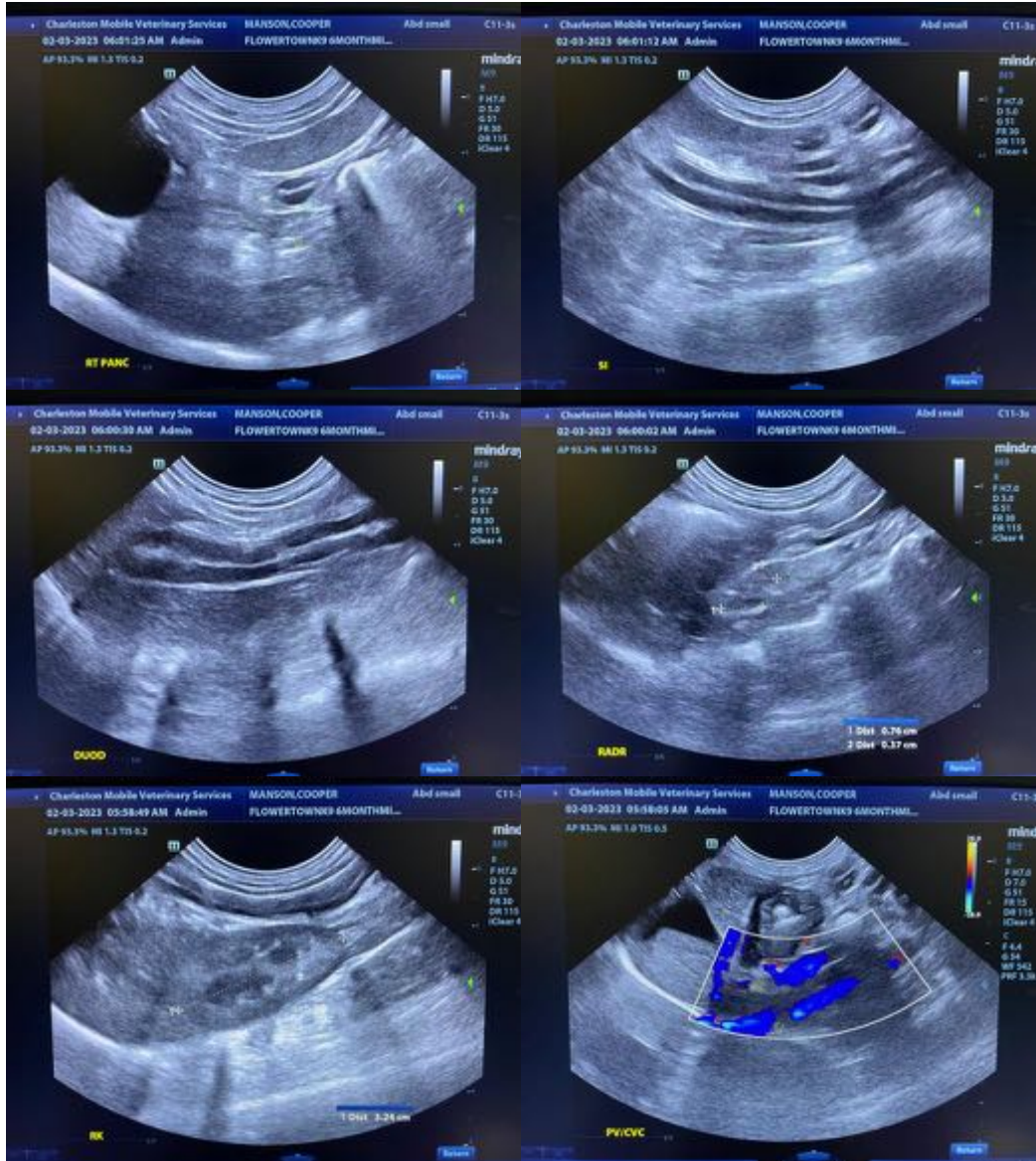
Primary Findings

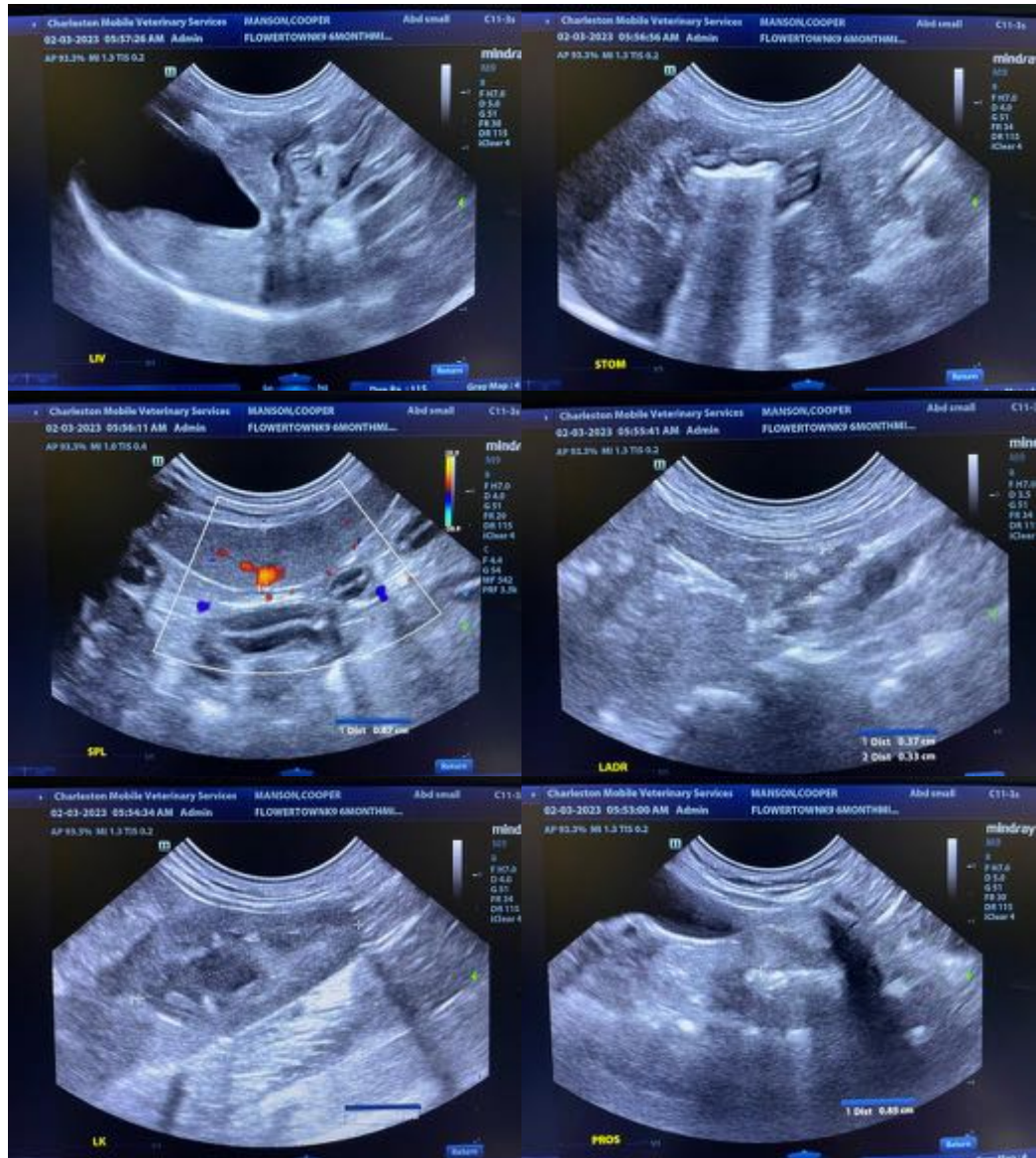
- The abdominal lymphadenopathy could be consistent with immunologic immaturity, reactive lymphadenitis or lymphoid hyperplasia. Infiltrative neoplasia is possible but considered unlikely.
- The abdomen is otherwise unremarkable. An obvious cause for the patient's inappetence is not identified in this study. Considerations include underlying metabolic issue, microscopic gastrointestinal disease, orthopedic/neurologic disease, other.

INTERPRETATION OF THE FINDINGS & FURTHER RECOMMENDATIONS

- Baseline lab work, including a CBC, chemistry panel, urinalysis and T4 is recommended.
- Orthopedic and neurologic examination should also be considered to assess for nonmetabolic causes of inappetence.
- Depending on the results of the above diagnostics, a more comprehensive work-up may be warranted.







The information and recommendations provided are based on the images presented by the referring veterinarian/sonographer. No evaluation can be communicated regarding pathology that was not visible in the image/video clips provided.

Thank you for this referral. If the clinical or image interpretation does not parallel your findings or if I can be of any further assistance, please contact me.

Andrea Nicastro, MPH, DVM, Diplomate DACVIM (Small Animal Internal Medicine)
info@SonoPath.com