



PATIENT

Mater Koroleski

SPECIES

Canine

BREED

Papillon

SEX

Male, neutered

AGE

6 Yrs. 11 months

WEIGHT

6.9 lbs.

INTERPRETED BY

Andrea Nicastro, DVM,
Diplomate ACVIM
(Small Animal Internal
Medicine)

**IMAGING
PERFORMED BY**

Amy Mayhew

HOSPITAL NAME

SVS Imaging Michigan

REFERRING VET

Dr. Craig

INVOICE

14651

DATE

2/28/23

PRESENTING CLINICAL SIGNS

History: Current Medications: Telmisartan 10 mg/mL 0.3 mL po SID. Welactin 1/2 scoop SID. RC renal support + HP. Bravecto. Interceptor Plus. Patient History: Hx of PLE, PLN, hypocalcemia, Ultrasound 2/28/23 for pre-anesthetic evaluation prior to dental surgery. see attached bloodwork performed 1/19/23. UPC elevation. Total protein and albumin slightly decreased from last blood panel. Phosphorus and calcium below reference range.

Abnormal PE/Chem/CBC/UA Results: 1/19/23: 1. BAR 5. Moderate tartar and halitosis- O would like to schedule dental, reviewed increased anesthetic risk with concurrent illness but as long as bloodwork, UA are stable okay to proceed with dental

Labwork from January 2023- albumin 2.1, UPC 5.8

ULTRASONOGRAPHIC EXAMINATION OF THE ABDOMEN

Urinary System

The urinary bladder and visible portion of the pelvic urethra are normal for the degree of luminal distension. The urine is anechoic with no evidence of debris. Cystic calculi and discrete masses are not observed. The region of the trigone and the visible portion of the proximal urethra are normal.

The prostate is normal in size (0.76 cm in width) and shape. Parenchyma is homogenous. The prostatic urethra appears normal without evidence of dilation or obstruction.

The left kidney is normal size (3.72 cm in length); normal shape and architecture with smooth peripheral margins. There is a normal 1:3 cortex to medulla ratio with normal corticomedullary distinction. There is no evidence of pyelectasia, nephroliths, infarcts or hydroureter.

The right kidney is normal size (3.73 cm in length); normal shape and architecture with smooth peripheral margins. There is a normal 1:3 cortex to medulla ratio with normal corticomedullary distinction. There is no evidence of pyelectasia, nephroliths, infarcts or hydroureter.

Adrenal Glands

The left adrenal gland is normal size (0.28 cm at cranial pole) (0.26 cm at caudal pole); normal shape; homogenous parenchyma. The glandular echogenicity and detail are unremarkable. Capsule, cortex, and medullary definition are normal. The phrenicoabdominal vein and surrounding vasculature are normal.

The right adrenal gland is normal size (0.31 cm at cranial pole) (0.29 cm at caudal pole); normal shape; homogenous parenchyma. The glandular echogenicity and detail are unremarkable. Capsule, cortex, and medullary definition are normal. The phrenicoabdominal vein and surrounding vasculature are normal.

Spleen

The spleen is normal in size (0.60 cm in width at the level of the hilus) with a normal capsular contour. There is appropriate echogenicity and echotexture. No focal lesions are observed. Splenic vasculature is normal.

Liver

The liver is subjectively normal in size with normal contours and structure. There is appropriate echogenicity and echotexture. No overt structural evidence of inflammatory, infiltrative or regenerative pathology is evident. Vascular and biliary tracts are of normal volume with no evidence of



PATIENT

Mater Koroleski

congestion. No pathological hepatic lymphadenopathy observed. The gallbladder is of normal contours and contains some dependent echogenic debris. The wall is normal in thickness. No choleliths are observed. The cystic and common bile ducts are normal.

SPECIES

Canine

Gastrointestinal

The stomach and intestine are free of stasis and exhibit normal peristaltic activity. The gastric lumen is not distended. The gastric wall and pylorus are normal in thickness with a normal layering pattern. The pyloric outflow tract is patent. The small intestinal lumen is not dilated. The small intestinal wall thickness is normal with a normal layering pattern and appropriate mural detail. Discreet masses are not identified. The colonic wall is normal. No obstructive disease is noted.

BREED

Papillon

Pancreas

SEX

Male, neutered

The region of the pancreas is isoechoic relative to surrounding omental fat. No obvious parenchymal abnormalities are observed. There is no evidence of regional inflammation or effusion.

AGE

6 Yrs. 11 months

Free Abdomen

The peritoneal cavity is normal. There is no evidence of inflammation or effusion. The abdominal lymph nodes are normal/not visible.

WEIGHT

6.9 lbs.

ULTRASONOGRAPHIC FINDINGS

Unremarkable abdomen.

INTERPRETED BY

Andrea Nicastro, DVM,
Diplomate ACVIM
(Small Animal Internal
Medicine)

INTERPRETATION OF THE FINDINGS & FURTHER RECOMMENDATIONS

- Given the substantially elevated UPC, consider initiation of an ACE inhibitor along with Telmisartan with close monitoring of the patient's renal values and blood pressure.
- If a dental procedure is to be pursued, ensure adequate renal perfusion before, during and after the procedure (i.e., via fluid therapy) with close monitoring of the patient's blood pressure during anesthesia to assess for a hypotensive episode.

IMAGING PERFORMED BY

Amy Mayhew

HOSPITAL NAME

SVS Imaging Michigan

REFERRING VET

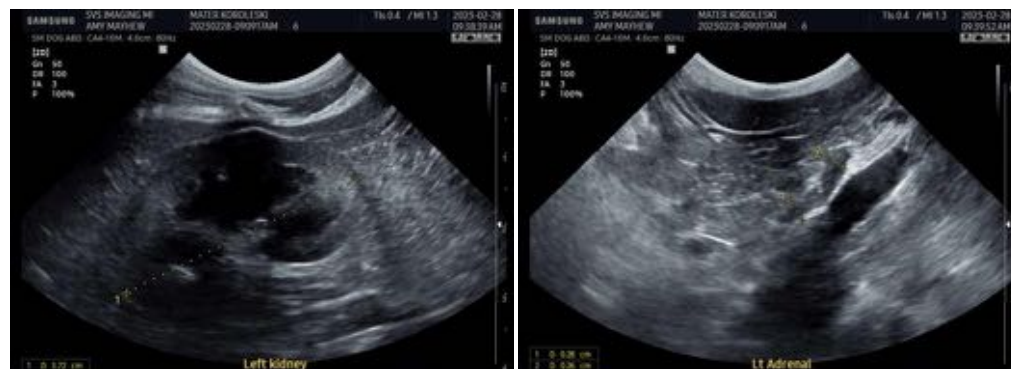Dr. Craig

INVOICE

14651

DATE

2/28/23





PATIENT

Mater Koroleski

SPECIES

Canine

BREED

Papillon

SEX

Male, neutered

AGE

6 Yrs. 11 months

WEIGHT

6.9 lbs.

INTERPRETED BY

Andrea Nicastro, DVM,
Diplomate ACVIM
(Small Animal Internal
Medicine)

**IMAGING
PERFORMED BY**

Amy Mayhew

HOSPITAL NAME

SVS Imaging Michigan

REFERRING VET

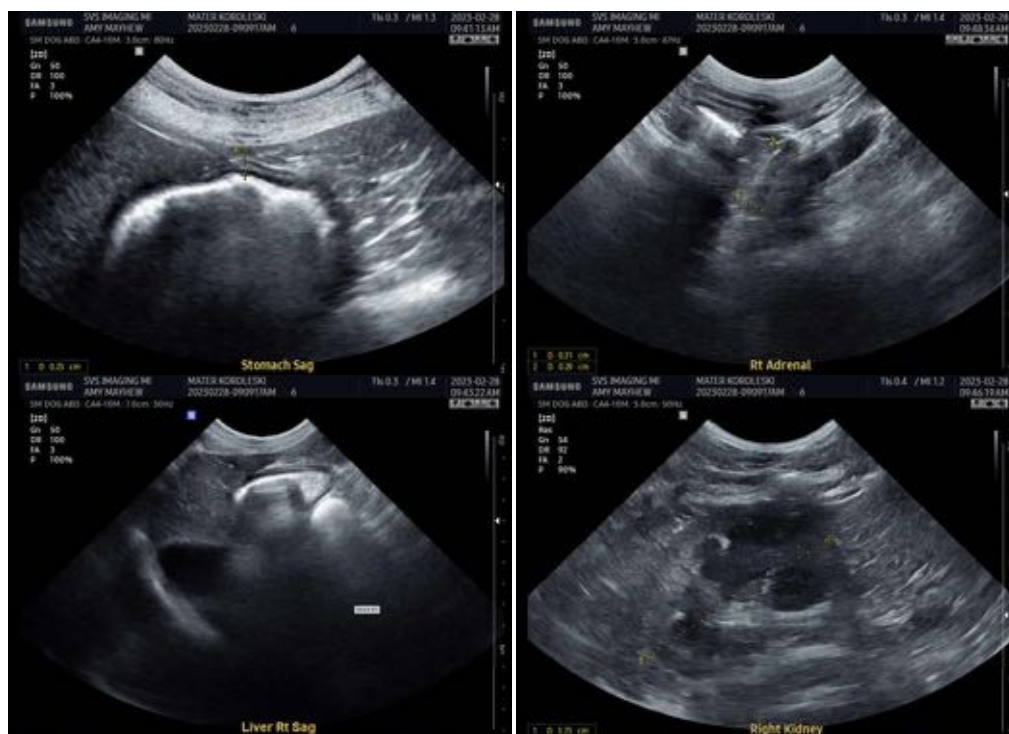
Dr. Craig

INVOICE

14651

DATE

2/28/23



The information and recommendations provided are based on the images presented by the referring veterinarian/sonographer. No evaluation can be communicated regarding pathology that was not visible in the image/video clips provided.

Thank you for this referral. If the clinical or image interpretation does not parallel your findings or if I can be of any further assistance please contact me.

Andrea Nicastro, MPH, DVM, Diplomate DACVIM (Small Animal Internal Medicine)
info@SonoPath.com