



PATIENT PRESENTING CLINICAL SIGNS

Luna Haltner History: lethargic, shaking last night; dribbling urine. On Urasyn, metronidazole, Denamarin , IV fluids
Abnormal PE/Chem/CBC/UA Results: ALT 839

SPECIES ULTRASONOGRAPHIC EXAMINATION OF THE ABDOMEN

Canine **Urinary System**

The urinary bladder wall is normal in thickness and the mucosal surface is smooth. The bladder is moderately distended. A small amount of suspended echogenic debris is observed within the lumen. No masses, inflammatory changes or calculi are observed. The region of the trigone and visible portion of the proximal urethra are normal.

BREED

Fr Bulldog

SEX

Intact Female

The left kidney is normal in size (4.41 cm in length) with a normal shape, architecture and smooth peripheral margins. There is a normal 1:3 cortex to medulla ratio with normal corticomedullary distinction. There is no evidence of pyelectasia, nephroliths, infarcts or hydronephrosis. Renal vasculature is normal.

AGE

6 mos

The right kidney is normal in size (5.23 cm in length) with a normal shape, architecture and smooth peripheral margins. There is a normal 1:3 cortex to medulla ratio with normal corticomedullary distinction. There is no evidence of pyelectasia, nephroliths, infarcts or hydronephrosis. Renal vasculature is normal.

WEIGHT

23.5 lbs

Adrenal Glands

The left adrenal gland is normal in size (0.43 cm at cranial pole) (0.54 cm at caudal pole) with a normal shape and homogenous parenchyma. The glandular echogenicity and detail are unremarkable. Capsule, cortex, and medullary definition are normal. The phrenicoabdominal vein and surrounding vasculature are normal.

The right adrenal gland is in normal size (0.69 cm at cranial pole) (0.42 cm at caudal pole) with a normal shape and homogenous parenchyma. The glandular echogenicity and detail are unremarkable. Capsule, cortex, and medullary definition are normal. The phrenicoabdominal vein and surrounding vasculature are normal.

INTERPRETED BY

Andrea Nicastro, DVM,
Diplomate ACVIM (*Small
Animal Internal Medicine*)

Spleen

The spleen is normal in size (1.41 cm in width at the level of the hilus) with a normal capsular contour. There is appropriate echogenicity and echotexture. No focal lesions are observed. Splenic vasculature is normal.

IMAGING PERFORMED BY

Diane McFadden

Liver

The liver is subjectively normal in size with normal contours and structure. There is appropriate echogenicity and echotexture. No overt structural evidence of inflammatory, infiltrative, or regenerative pathology is evident. Vascular and biliary tracts are of normal volume with no evidence of congestion. No pathological hepatic lymphadenopathy observed. The portal vein to caudal vena cava ratio is approximately 1: 1.

HOSPITAL NAME

Newton VH

REFERRING VET

Dr Kim

The gall bladder lumen is moderately distended. The wall is thin and smooth. Luminal contents are anechoic. The cystic and common bile ducts are normal/not seen.

Gastrointestinal

The stomach and intestine are free of stasis and exhibit normal peristaltic activity. The gastric lumen is not distended. The gastric wall and pylorus are normal in thickness with a normal layering pattern. The pyloric outflow tract is patent. The small intestinal lumen is not dilated. The small intestinal wall thickness is normal with a normal layering pattern and appropriate mural detail. Discreet masses are not identified. The colonic wall is normal. There is no evidence of an obstructive pattern.

INVOICE

12291

DATE

2.27.23

Pancreas

The pancreas is normal in size with normal peripheral contours. The pancreatic duct is normal. The base and limbs of the pancreas are isoechoic to surrounding omental fat. No focal lesions are observed. There is no evidence of peripancreatic inflammation or effusion.

Free Abdomen

The peritoneal cavity is normal. There is no evidence of inflammation or effusion. A few prominent mesenteric lymph nodes are visualized (the largest measuring 1.96 cm in length).

Other

The uterine body is visible and is normal in size (0.45 cm in width). No obvious pathology is observed.

ULTRASONOGRAPHIC FINDINGS

Primary Findings

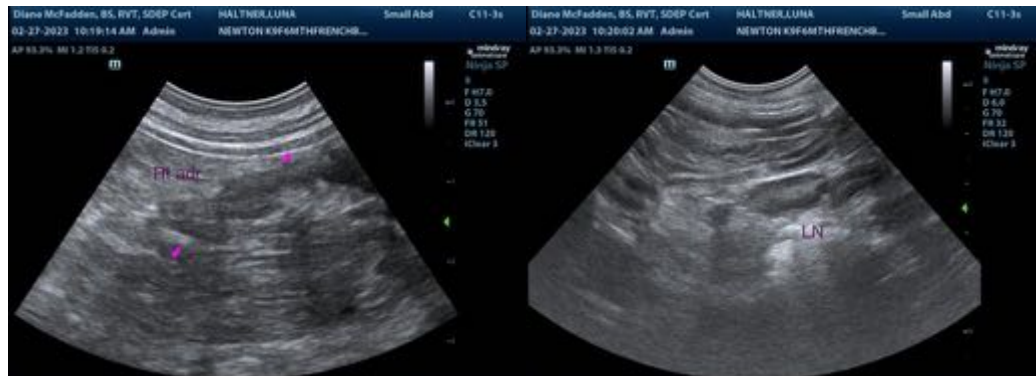- The cause for the patient's clinical signs and the elevated ALT is not identified in this study. Considerations include Leptospirosis, bacterial cholangiohepatitis, hepatotoxicity, congenital disease (less likely), other hepatopathy.

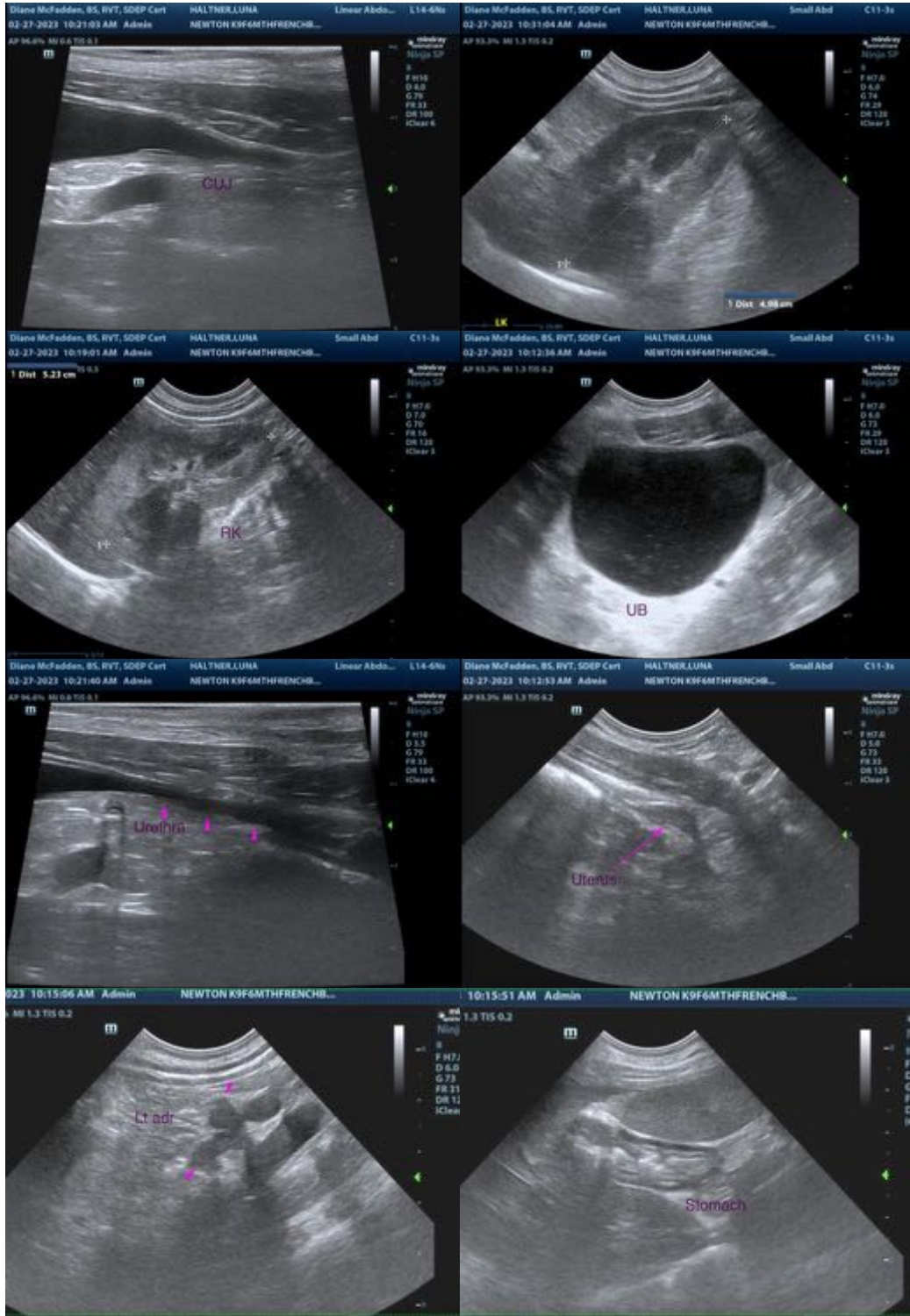
Secondary Findings

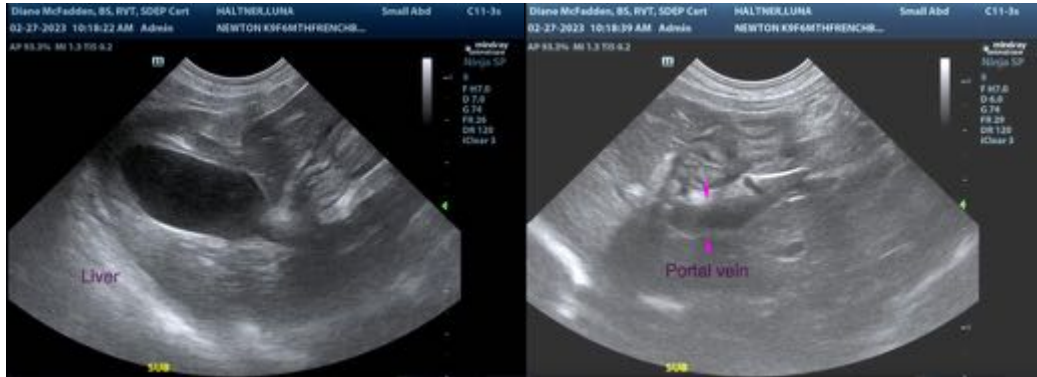
- Urinary bladder debris
- The abdominal lymphadenopathy could be consistent with immunologic immaturity, reactive lymphadenitis or lymphoid hyperplasia. Infiltrative neoplasia is possible but considered unlikely.

INTERPRETATION OF THE FINDINGS & FURTHER RECOMMENDATIONS

- Leptospirosis testing (i.e., blood and urine PCR, serology) is recommended, along with pre-and postprandial serum bile acids, +/- hepatic tissue sampling (i.e., fine-needle aspirate or biopsies). Clotting times should be assessed prior to any hepatic tissue sampling.
- A urine culture and sensitivity is also recommended to assess for occult pyelonephritis.
- While awaiting test results, empirical treatment for bacterial cholangiohepatitis/Leptospirosis/hepatotoxicity is recommended (including broad-spectrum antibiotic, hepatic antioxidants and supportive care).







The information and recommendations provided are based on the images presented by the referring veterinarian/sonographer. No evaluation can be communicated regarding pathology that was not visible in the image/video clips provided.

Thank you for this referral. If the clinical or image interpretation does not parallel your findings or if I can be of any further assistance, please contact me.

Andrea Nicastro, MPH, DVM, Diplomate DACVIM (Small Animal Internal Medicine)
info@SonoPath.com