


PATIENT PRESENTING CLINICAL SIGNS

Kylie Dietz History: pancreatitis, consumes large amt of grass decreased appetite lethargic

SPECIES ULTRASONOGRAPHIC EXAMINATION OF THE ABDOMEN
Canine
Urinary System

The urinary bladder wall is normal in thickness and the mucosal surface is smooth. The bladder lumen is distended with anechoic urine. No masses, inflammatory changes or calculi are observed. Ureteral papillae and visualized portion of the proximal urethra, visible to a depth of 1-2 cm, are normal.

BREED

Boxer The left kidney is normal in size (5.58 cm in length) with a normal shape, architecture and smooth peripheral margins. There is a normal 1:3 cortex to medulla ratio with normal corticomedullary distinction. There is no evidence of pyelectasia, nephroliths, infarcts or hydronephrosis. Renal vasculature is normal.

SEX

Intact Female The right kidney is normal in size (5.25 cm in length) with a normal shape, architecture and smooth peripheral margins. There is a normal 1:3 cortex to medulla ratio with normal corticomedullary distinction. There is no evidence of pyelectasia, nephroliths, infarcts or hydronephrosis. Renal vasculature is normal.

AGE
Adrenal Glands

1 year The left adrenal gland is normal in size (0.49 cm at cranial pole) (0.44 cm at caudal pole) (1.73 cm in length) with a normal shape and homogenous parenchyma. The glandular echogenicity and detail are unremarkable. Capsule, cortex, and medullary definition are normal. The phrenicoabdominal vein and surrounding vasculature are normal.

WEIGHT

64 lbs The right adrenal gland is in normal size (1.90 cm at cranial pole) (0.78 cm at caudal pole) (0.92 cm in length) with a normal shape and homogenous parenchyma. The glandular echogenicity and detail are unremarkable. Capsule, cortex, and medullary definition are normal. The phrenicoabdominal vein and surrounding vasculature are normal.

INTERPRETED BY

Andrea Nicastro, DVM,
 Diplomate ACVIM (*Small
 Animal Internal Medicine*)

Spleen

The spleen is normal in size (2.11 cm in width at the level of the hilus) with a normal capsular contour. There is appropriate echogenicity and echotexture. No focal lesions are observed. Splenic vasculature is normal.

IMAGING PERFORMED BY

Jenn

Liver

The liver is subjectively normal in size with normal contours and structure. There is appropriate echogenicity and echotexture. No overt structural evidence of inflammatory, infiltrative, or regenerative pathology is evident. Vascular and biliary tracts are of normal volume with no evidence of congestion. No pathological hepatic lymphadenopathy observed.

HOSPITAL NAME

Rocakway AH

The gall bladder is of normal contours and contains some dependent echogenic debris. The wall is normal in thickness. No choleliths are observed. The cystic and common bile ducts are normal/not seen.

REFERRING VET

Dr. Maniar

Gastrointestinal

The gastric lumen is mildly distended with soft, shadowing material. The gastric wall is normal in thickness with a normal layering pattern. The small intestinal lumen is not dilated. The small intestinal wall thickness is normal with a normal layering pattern and appropriate mural detail. Discreet masses are not identified. The colonic wall is normal.

INVOICE

12294

Pancreas

The region of the pancreas is isoechoic relative to surrounding omental fat. No obvious parenchymal abnormalities are observed. There is no evidence of regional inflammation or effusion.

DATE

2.27.23

Free Abdomen

The peritoneal cavity is normal. There is no evidence of inflammation or effusion. The abdominal lymph nodes are normal/not visible.

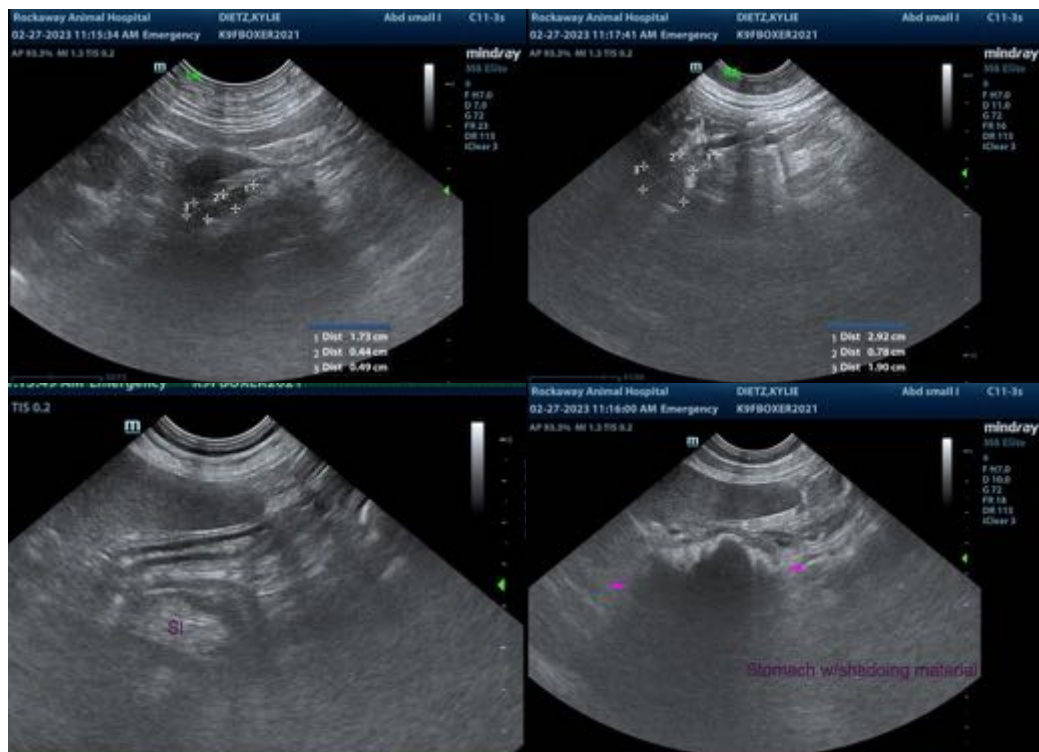
ULTRASONOGRAPHIC FINDINGS

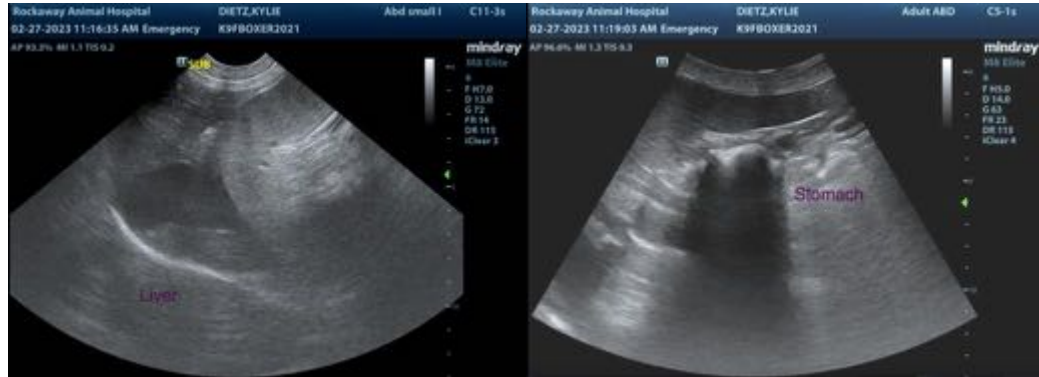Primary Findings

- The shadowing contents within the gastric lumen may represent normal ingesta or foreign material (i.e., grass, other).

INTERPRETATION OF THE FINDINGS & FURTHER RECOMMENDATIONS

- Supportive care for acute gastroenteritis is recommended, along with a fecal evaluation for ova and Giardia and a cPLI to further assess for pancreatitis.
- Also consider a repeat ultrasound in 12-24 hours to assess for movement of the gastric contents into the small intestine.
- Baseline lab work, including a CBC, chemistry panel, urinalysis and T4 is also recommended to evaluate over metabolic function.
- If the patient's clinical signs do not improve with medical management, a more comprehensive GI work-up may be warranted.





The information and recommendations provided are based on the images presented by the referring veterinarian/sonographer. No evaluation can be communicated regarding pathology that was not visible in the image/video clips provided.

Thank you for this referral. If the clinical or image interpretation does not parallel your findings or if I can be of any further assistance, please contact me.

Andrea Nicastro, MPH, DVM, Diplomate DACVIM (Small Animal Internal Medicine)
info@SonoPath.com