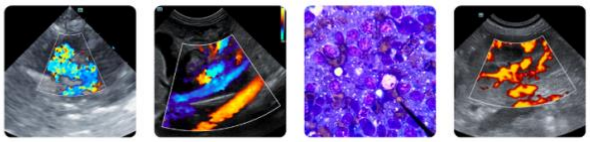

PATIENT
Harley Sullivan

SPECIES
Canine

BREED
Mix

SEX
Female Spayed

AGE
4

WEIGHT
52

INTERPRETED BY
Andrea Nicastro, DVM, Diplomate ACVIM
(Sm Animal Internal Med)

IMAGING PERFORMED BY
Jenn

HOSPITAL NAME
Rockaway AH

REFERRING VET
Dr Maniar

INVOICE
22617

DATE
2-26-26

PRESENTING CLINICAL SIGNS

History: Recheck prev u/s 1/20 Owner reports doing well e/d only vomited bile once Sunday 2/22

ULTRASONOGRAPHIC EXAMINATION OF THE ABDOMEN

Urinary System

The urinary bladder wall is normal in thickness. The mucosal surface is smooth. The bladder is moderately distended. Luminal contents are anechoic. No cystic calculi are observed. The region of the trigone is normal.

The left kidney is normal in size (6.36 cm in length) with a normal shape, architecture and smooth peripheral margins. There is a normal 1:3 cortex to medulla ratio with normal corticomedullary distinction. There is no evidence of pyelectasia, nephroliths, infarcts or hydroureter. Renal vasculature is normal.

The right kidney is normal in size (4.88 cm in length) with a normal shape, architecture and smooth peripheral margins. There is a normal 1:3 cortex to medulla ratio with normal corticomedullary distinction. There is no evidence of pyelectasia, nephroliths, infarcts or hydroureter. Renal vasculature is normal.

Adrenal Glands

The caudal pole left adrenal gland is visualized and is small- to normal-in-size (0.40 cm in width). Glandular echogenicity and detail are normal. Surrounding vasculature appears normal.

The region of the right adrenal gland is evaluated. No obvious pathology is observed in this region.

Spleen

The spleen is normal in size (1.39 cm in width at the level of the hilus) with a normal capsular contour. There is appropriate echogenicity and echotexture. No focal lesions are observed. Splenic vasculature is normal.

Liver

The liver is subjectively normal in size with normal contours and structure. There is appropriate echogenicity and echotexture. No overt structural evidence of inflammatory, infiltrative, or regenerative pathology is evident. Vascular and biliary tracts are of normal volume with no evidence of congestion.

The gallbladder lumen is moderately distended. The wall is thin and smooth. Luminal contents are anechoic. The cystic and common bile ducts are normal/not seen.

Gastrointestinal

The gastric lumen is not distended. The gastric wall is normal in thickness with a normal layering pattern. The small intestinal lumen is not dilated. The small intestinal wall is normal in thickness with a normal layering pattern and appropriate mural detail. Discreet masses are not identified. The colonic wall is normal. There is no evidence of an obstructive pattern.

Pancreas

The region of the pancreas is isoechoic relative to surrounding omental fat. No obvious parenchymal abnormalities are observed. There is no evidence of regional inflammation or effusion.

Lymph Nodes

The abdominal lymph nodes are normal/not visible.

PATIENT

Harley Sullivan

SPECIES

Canine

BREED

Mix

SEX

Female Spayed

AGE

4

WEIGHT

52

INTERPRETED BY

Andrea Nicastro, DVM, Diplomate ACVIM
(Sm Animal Internal Med)

IMAGING PERFORMED BY

Jenn

HOSPITAL NAME

Rockaway AH

REFERRING VET

Dr Maniar

INVOICE

22617

DATE

2-26-26

Free Abdomen

The peritoneal cavity is normal. There is no evidence of inflammation or effusion.

ULTRASONOGRAPHIC FINDINGS

Structurally unremarkable abdomen. An obvious cause for the patient's elevated liver values is not identified in this study. Considerations include hepatic infection (i.e., Leptospirosis, cholangiohepatitis), hepatotoxicosis, a hypotensive event, emerging chronic hepatitis, other.

INTERPRETATION OF THE FINDINGS & FURTHER RECOMMENDATIONS

The patient's liver values should be reevaluated. If values remain persistently elevated, hepatic tissue sampling, along with aerobic and anaerobic bile cultures and hepatic copper quantitation should be performed. Leptospirosis testing (i.e., blood and urine PCR, serology) should also be considered (if not already performed).

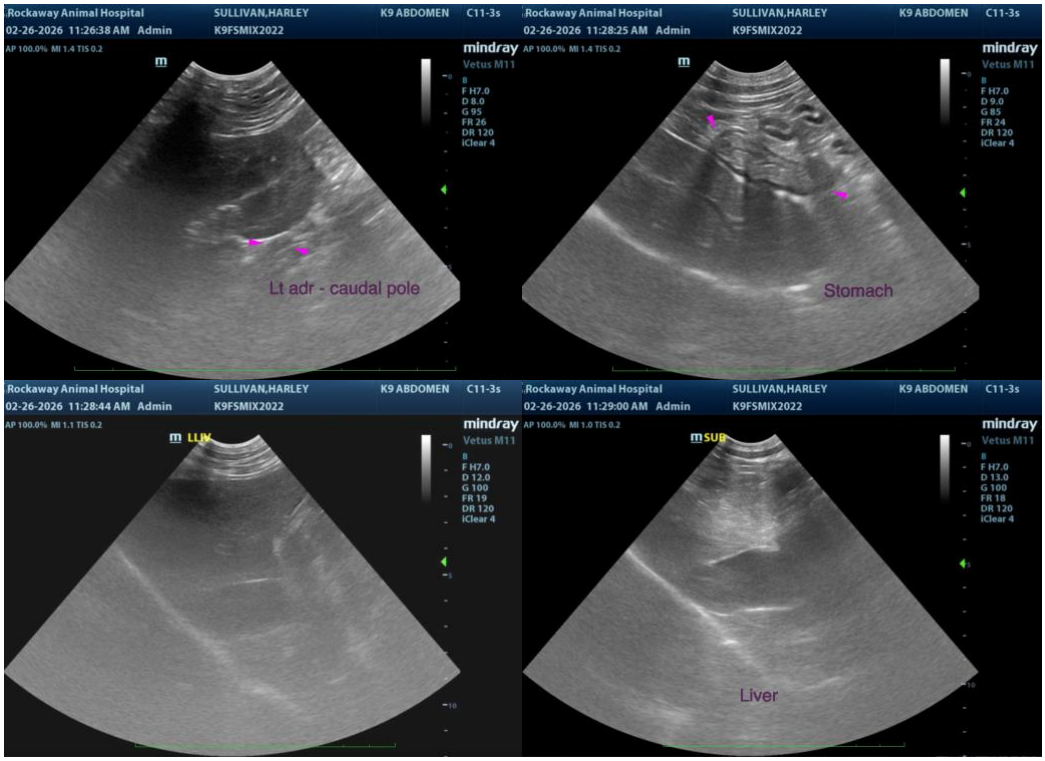

SonoPath
FOSTERING THE ART OF VETERINARY MEDICINE™

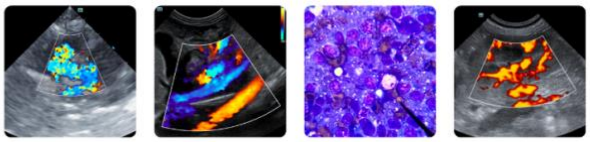

Clinical Sonography & Telecytology
Educational Teleconsultation Services™

SonoPath.com info@sonopath.com 1.800.838.4268

PATIENT

Harley Sullivan

SPECIES

Canine

BREED

Mix

SEX

Female Spayed

AGE

4

WEIGHT

52

INTERPRETED BY

Andrea Nicastro, DVM, Diplomate ACVIM
(Sm Animal Internal Med)

IMAGING PERFORMED BY

Jenn

HOSPITAL NAME

Rockaway AH

REFERRING VET

Dr Maniar

INVOICE

22617

DATE

2-26-26

The information and recommendations provided are based on the images presented by the referring veterinarian/sonographer. No evaluation can be communicated regarding pathology that was not visible in the image/video clips provided.

Thank you for this referral. If the clinical or image interpretation does not parallel your findings or if I can be of any further assistance, please contact me.

Andrea Nicastro, MPH, DVM, Diplomate DACVIM (Small Animal Internal Medicine)
info@SonoPath.com