



**PATIENT**

Champion Potter

**SPECIES**

Canine

**BREED**

Doberman Pinscher

**SEX**

Neutered Male

**AGE**

10

**WEIGHT**

100 lbs

**INTERPRETED BY**

Andrea Nicastrò DVM  
Diplomate ACVIM  
(Sm Animal Internal Med)

**IMAGING  
PERFORMED BY**

Andrea Nicastrò DVM  
Diplomate ACVIM  
(Sm Animal Internal Med)

**HOSPITAL NAME**

Central VH  
Summerville

**REFERRING VET**

Dr Miller

**INVOICE**

22594

**DATE**

2-23-26

**PRESENTING CLINICAL SIGNS**

Patient has a recent history of PU/PD polyphagia. Has gained about 20 lbs in the last few months. USG 1.022 with trace proteinuria and an inactive sediment. ALP 1630. Elevated cholesterol and triglycerides. CBC unremarkable. T4 0.8. Low-dose dexamethasone not consistent with Cushing's disease. Patient also has a history of coughing, and did have a nosebleed, which has since cleared up with antibiotics.

**ULTRASONOGRAPHIC EXAMINATION OF THE ABDOMEN**

**Urinary System**

The urinary bladder is mildly-to-moderately distended with mostly anechoic urine. The wall in the region of the apex is thickened (up to 0.65 cm) with a slightly irregular mucosal surface. The wall tapers to a normal thickness as it extends towards the cystourethral junction. No cystic calculi are observed. The region of the trigone and the proximal urethra, visible to a depth of 5 cm, are normal.

The prostate is normal in size (1.68 cm in width) and shape. Parenchyma is homogenous. The prostatic urethra appears normal without evidence of dilation or obstruction.

The left kidney is normal in size (7.11 cm in length) with a normal shape, architecture and smooth peripheral margins. There is a normal 1:3 cortex to medulla ratio with mild to moderate loss of corticomedullary distinction. There is no evidence of pyelectasia, nephroliths, infarcts or hydronephrosis. Renal vasculature is normal.

The right kidney is normal in size (7.74 cm in length) with a normal shape, architecture and smooth peripheral margins. There is a normal 1:3 cortex to medulla ratio with minimal-to-mild corticomedullary distinction. There is no evidence of pyelectasia, nephroliths, infarcts or hydronephrosis. Renal vasculature is normal.

**Adrenal Glands**

The left adrenal gland is normal in size (0.54 cm at cranial pole) (0.70 cm at caudal pole) with a normal shape and homogenous parenchyma. The glandular echogenicity and detail are unremarkable. Capsule, cortex, and medullary definition are normal. The phrenicoabdominal vein and surrounding vasculature are normal.

The right adrenal gland is normal in size (0.59 cm at cranial pole) (0.56 cm at caudal pole) with a normal shape and homogenous parenchyma. The glandular echogenicity and detail are unremarkable. Capsule, cortex, and medullary definition are normal. The phrenicoabdominal vein and surrounding vasculature are normal.

**Spleen**

The spleen is normal in size (1.63 cm in width at the level of the hilus) with a normal capsular contour. The parenchyma is subtly mottled in appearance. No focal lesions are observed. Splenic vasculature is normal.

**Liver**

The liver is prominent-in-size, with smooth peripheral contours. There is appropriate echogenicity and echotexture. No overt structural evidence of inflammatory, infiltrative, or regenerative pathology is evident. Vascular and biliary tracts are of normal volume with no evidence of congestion.

The gallbladder is of normal contours and contains some dependent echogenic debris. The wall is normal in thickness. No choleliths are observed. The cystic and common bile ducts are normal/not seen.

**Gastrointestinal**

The gastric lumen is mildly to moderately-distended with ingesta, consistent with a post-prandial



**PATIENT**

Champion Potter

**SPECIES**

Canine

**BREED**

Doberman Pinscher

**SEX**

Neutered Male

**AGE**

10

**WEIGHT**

100 lbs

**INTERPRETED BY**

Andrea Nicastrò DVM  
Diplomate ACVIM  
(Sm Animal Internal Med)

**IMAGING  
PERFORMED BY**

Andrea Nicastrò DVM  
Diplomate ACVIM  
(Sm Animal Internal Med)

**HOSPITAL NAME**

Central VH  
Summerville

**REFERRING VET**

Dr Miller

**INVOICE**

22594

**DATE**

2-23-26

presentation. The gastric wall is normal in thickness with a normal layering pattern. The small intestinal lumen is not dilated. The small intestinal wall is normal in thickness with a normal layering pattern and appropriate mural detail. Discreet masses are not identified. The colonic wall is normal. There is no evidence of an obstructive pattern.

**Pancreas**

A portion of the pancreas is obscured by the gastric distention. In the visualized portion, no obvious abnormalities are seen.

**Lymph Nodes**

A 0.99 x 0.52 cm mesenteric lymph node is visualized.

**Free Abdomen**

The peritoneal cavity is normal. There is no evidence of inflammation or effusion.

**ULTRASONOGRAPHIC FINDINGS**

**Primary Findings**

- The diffuse hepatic changes are non-specific and could be consistent with vacuolar hepatopathy, regenerative nodular hyperplasia, and/or age-related remodeling. Inflammatory disease, infiltrative neoplasia and other hepatopathies are considered less likely.
- Gallbladder debris, non-mucocele

**Secondary Findings**

- Bilateral nonspecific age-related renal changes
- The splenic parenchyma changes are most consistent with a benign process such as lymphoid hyperplasia, extramedullary hematopoiesis or splenitis with a lower possibility of infiltrative neoplasia (i.e., lymphoma, mast cell neoplasia).
- The prominent mesenteric lymph node is likely reactive, with a lower possibility of emerging neoplasia.
- The urinary bladder wall changes could be consistent with cystitis or may be artifactual due to lack of full repletion.

\*An obvious cause for the patient's clinical signs is not definitively identified in this study. Considerations include hyperadrenocorticism, diabetic insipidus (i.e., central, nephrogenic), Leptospirosis, psychogenic polydipsia, brain neoplasia, other.

**INTERPRETATION OF THE FINDINGS & FURTHER RECOMMENDATIONS**

- Consider further testing for Cushing's disease (i.e., ACTH stimulation test +/- adrenal panel (University of Tennessee)).
- Also consider Leptospirosis testing (i.e., blood and urine PCR, serology, particularly if clinical suspicion for disease is high).
- If the above diagnostics are inconclusive, consider the following:



**PATIENT**

Champion Potter

1. DDAVP trial
2. Modified water deprivation test

**SPECIES**

Canine

**BREED**

Doberman Pinscher

**SEX**

Neutered Male

**AGE**

10

**WEIGHT**

100 lbs

**INTERPRETED BY**

Andrea Nicastrò DVM  
 Diplomate ACVIM  
 (Sm Animal Internal Med)

**IMAGING PERFORMED BY**

Andrea Nicastrò DVM  
 Diplomate ACVIM  
 (Sm Animal Internal Med)

**HOSPITAL NAME**

Central VH  
 Summerville

**REFERRING VET**

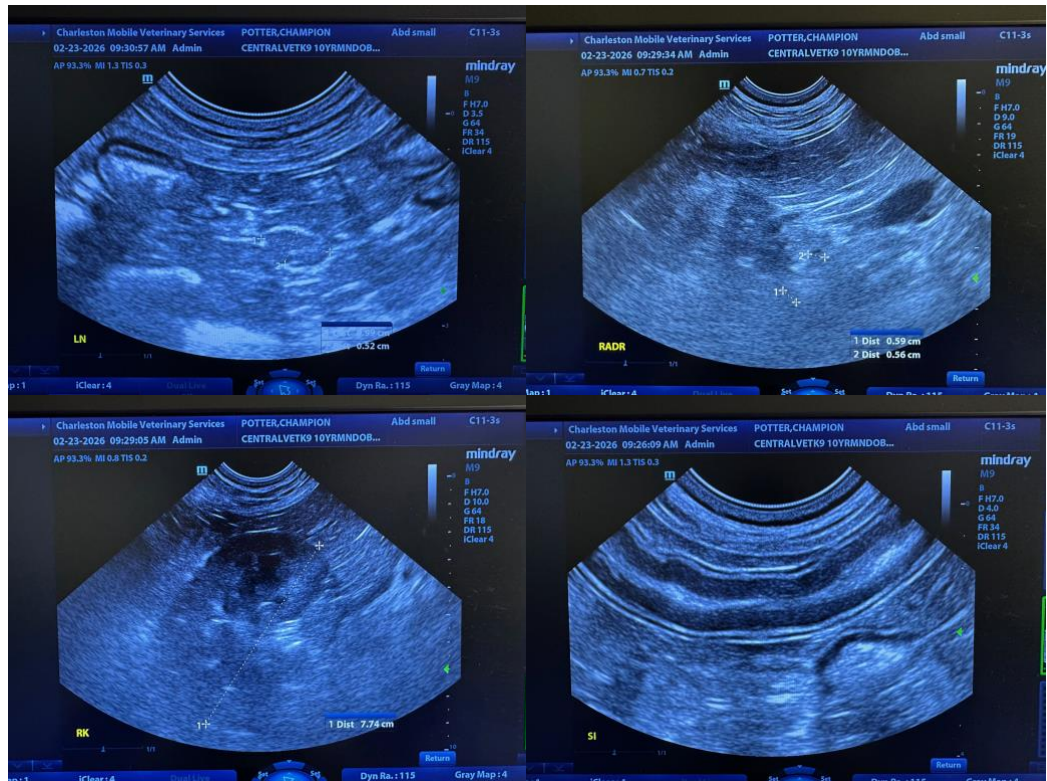
Dr Miller

**INVOICE**

22594

**DATE**

2-23-26





**PATIENT**

Champion Potter

**SPECIES**

Canine

**BREED**

Doberman Pinscher

**SEX**

Neutered Male

**AGE**

10

**WEIGHT**

100 lbs

**INTERPRETED BY**

Andrea Nicastrò DVM  
 Diplomate ACVIM  
 (Sm Animal Internal Med)

**IMAGING PERFORMED BY**

Andrea Nicastrò DVM  
 Diplomate ACVIM  
 (Sm Animal Internal Med)

**HOSPITAL NAME**

Central VH  
 Summerville

**REFERRING VET**

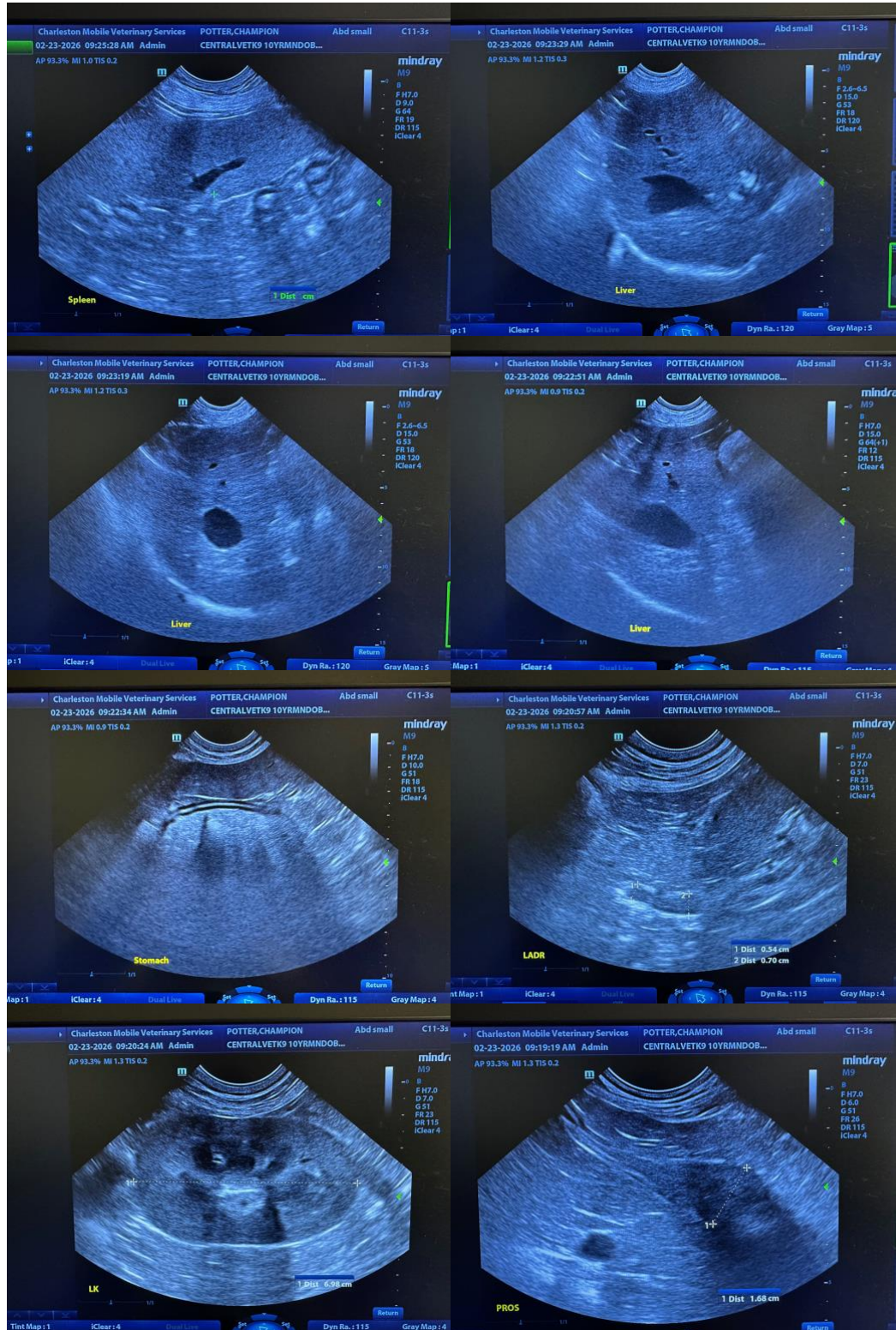
Dr Miller

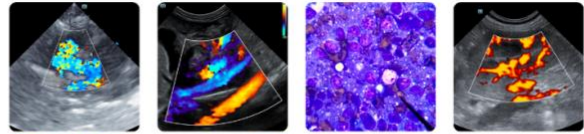
**INVOICE**

22594

**DATE**

2-23-26





**PATIENT**

Champion Potter

**SPECIES**

Canine

**BREED**

Doberman Pinscher

**SEX**

Neutered Male

**AGE**

10

**WEIGHT**

100 lbs

**INTERPRETED BY**

Andrea Nicastro DVM  
Diplomate ACVIM  
(Sm Animal Internal Med)

**IMAGING  
PERFORMED BY**

Andrea Nicastro DVM  
Diplomate ACVIM  
(Sm Animal Internal Med)

**HOSPITAL NAME**

Central VH  
Summerville

**REFERRING VET**

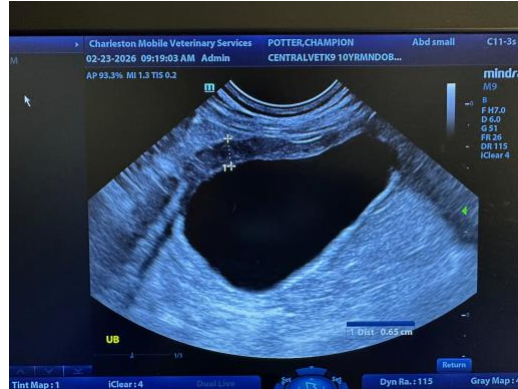
Dr Miller

**INVOICE**

22594

**DATE**

2-23-26



The information and recommendations provided are based on the images presented by the referring veterinarian/sonographer. No evaluation can be communicated regarding pathology that was not visible in the image/video clips provided.

Thank you for this referral. If the clinical or image interpretation does not parallel your findings or if I can be of any further assistance, please contact me.

**Andrea Nicastro, MPH, DVM, Diplomate DACVIM (Small Animal Internal Medicine)**  
[info@SonoPath.com](mailto:info@SonoPath.com)