

**PATIENT PRESENTING CLINICAL SIGNS**

Tucker Brown History: Annual abdominal US due to his age and breed He has known arthritis and multiple masses (suspected mostly to be lipomas). Has a history of cutaneous hemangiosarcoma.

**SPECIES**

Canine

**BREED**

Pitbull Terrier

**SEX**

Neutered Male

**AGE**

14 years, 11 mos

**WEIGHT**

58.8 lbs

**INTERPRETED BY**

Andrea Nicastro, DVM,  
Diplomate ACVIM  
(Small Animal Internal  
Medicine)

**IMAGING PERFORMED BY**

Loetitia Saint-Jacques,  
LVT

**HOSPITAL NAME**

MountainView AH

**REFERRING VET**

Dr Ashlie Brown

**INVOICE**

12283

**DATE**

2.23.23

**ULTRASONOGRAPHIC EXAMINATION OF THE ABDOMEN**

**Urinary System**

The urinary bladder wall is normal in thickness and the mucosal surface is smooth. The bladder lumen is moderately distended with anechoic urine. No masses, inflammatory changes or calculi are observed. Ureteral papillae and visualized portion of the proximal urethra, visible to a depth of 2 cm, are normal.

The prostate is normal in size (1.04 cm in width) and shape. Parenchyma is homogenous. The prostatic urethra appears normal without evidence of dilation or obstruction.

The left kidney is normal in size (5.91 cm in length) with a normal shape, architecture and smooth peripheral margins. There is a normal 1:3 cortex to medulla ratio with mild loss of corticomedullary distinction. There is no evidence of pyelectasia, nephroliths, infarcts or hydroureter.

The right kidney is normal in size (6.66 cm in length) with a normal shape, architecture and smooth peripheral margins. There is a normal 1:3 cortex to medulla ratio with mild loss of corticomedullary distinction. There is no evidence of pyelectasia, nephroliths, infarcts or hydroureter.

**Adrenal Glands**

The left adrenal gland is normal in size (0.58 cm at cranial pole) (0.65 cm at caudal pole) with a normal shape and homogenous parenchyma. The glandular echogenicity and detail are unremarkable. Capsule, cortex, and medullary definition are normal. The phrenicoabdominal vein and surrounding vasculature are normal.

The right adrenal gland is in normal size (0.82 cm at cranial pole) (0.74 cm at caudal pole) with a normal shape and homogenous parenchyma. The glandular echogenicity and detail are unremarkable. Capsule, cortex, and medullary definition are normal. The phrenicoabdominal vein and surrounding vasculature are normal.

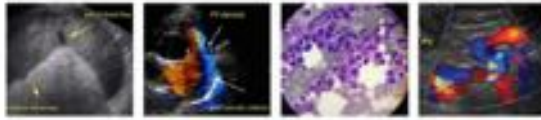
**Spleen**

The spleen is normal in size (1.92 cm in width at the level of the hilus) with a normal capsular contour. There is appropriate echogenicity and echotexture. A 1.70 cm hyperechoic to slightly heterogenous nodule, with suspected small cavitated areas is observed at the craniolateral aspect. In addition, 1.90 cm ill-defined hypoechoic nodule/area is observed at the caudolateral aspect. A few small, ill-defined hyperechoic nodules/areas are also seen.

**Liver**

The liver is subjectively normal in size with normal contours and structure. There is appropriate echogenicity and echotexture. No overt structural evidence of inflammatory, infiltrative, or regenerative pathology is evident. Vascular and biliary tracts are of normal volume with no evidence of congestion. No pathological hepatic lymphadenopathy observed.

The gall bladder lumen is moderately distended. The wall is thin and smooth. A moderate amount of echogenic debris is observed within the lumen (most of which is gravity dependent, some of which is suspended). The cystic and common bile ducts are normal/not seen.



**PATIENT**

Tucker Brown

**SPECIES**

Canine

**BREED**

Pitbull Terrier

**SEX**

Neutered Male

**AGE**

14 years, 11 mos

**WEIGHT**

58.8 lbs

**INTERPRETED BY**

Andrea Nicastro, DVM,  
Diplomate ACVIM  
(Small Animal Internal  
Medicine)

**IMAGING PERFORMED BY**

Loetitia Saint-Jacques,  
LVT

**HOSPITAL NAME**

MountainView AH

**REFERRING VET**

Dr Ashlie Brown

**INVOICE**

12283

**DATE**

2.23.23

**Gastrointestinal**

The stomach and intestine are free of stasis and exhibit normal peristaltic activity. The gastric lumen is not distended. The gastric wall and pylorus are normal in thickness with a normal layering pattern. The pyloric outflow tract is patent. The small intestinal lumen is not dilated. The small intestinal wall thickness is normal with a normal layering pattern and appropriate mural detail. Discreet masses are not identified. The colonic wall is normal. There is no evidence of an obstructive pattern.

**Pancreas**

The region of the pancreas is isoechoic relative to surrounding omental fat. No obvious parenchymal abnormalities are observed. There is no evidence of regional inflammation or effusion.

**Free Abdomen**

The peritoneal cavity is normal. There is no evidence of inflammation or effusion. One to two mesenteric lymph nodes are also visualized (the largest measuring 1.20 cm in length).

**ULTRASONOGRAPHIC FINDINGS**

**Primary Findings**

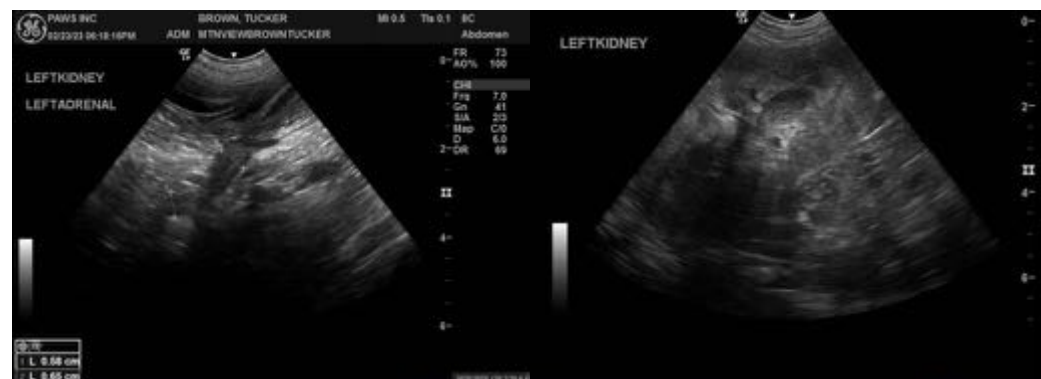- The splenic lesions appear slightly larger compared to the previous sonogram. The lesion at the cranialateral aspect seems to have changed in appearance. The new, smaller hyperechoic lesions trend toward the benign (i.e., myelolipomas) with a lower possibility of more insidious pathology.

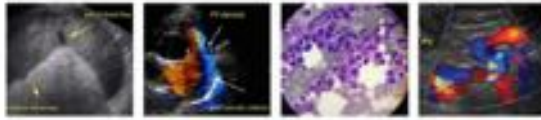
**Secondary Findings**

- Bilateral chronic age-related renal changes. Renal changes are similar to the previous sonogram.

**INTERPRETATION OF THE FINDINGS & FURTHER RECOMMENDATIONS**

- Consider fine-needle aspirates of the splenic lesions (if clotting status is appropriate). Twenty-five gauge-needles should be used. If results are benign or inconclusive, consider repeating an ultrasound in 2-3 months.





**PATIENT**

Tucker Brown

**SPECIES**

Canine

**BREED**

Pitbull Terrier

**SEX**

Neutered Male

**AGE**

14 years, 11 mos

**WEIGHT**

58.8 lbs

**INTERPRETED BY**

Andrea Nicastro, DVM,  
Diplomate ACVIM  
(Small Animal Internal  
Medicine)

**IMAGING  
PERFORMED BY**

Loetitia Saint-Jacques,  
LVT

**HOSPITAL NAME**

MountainView AH

**REFERRING VET**

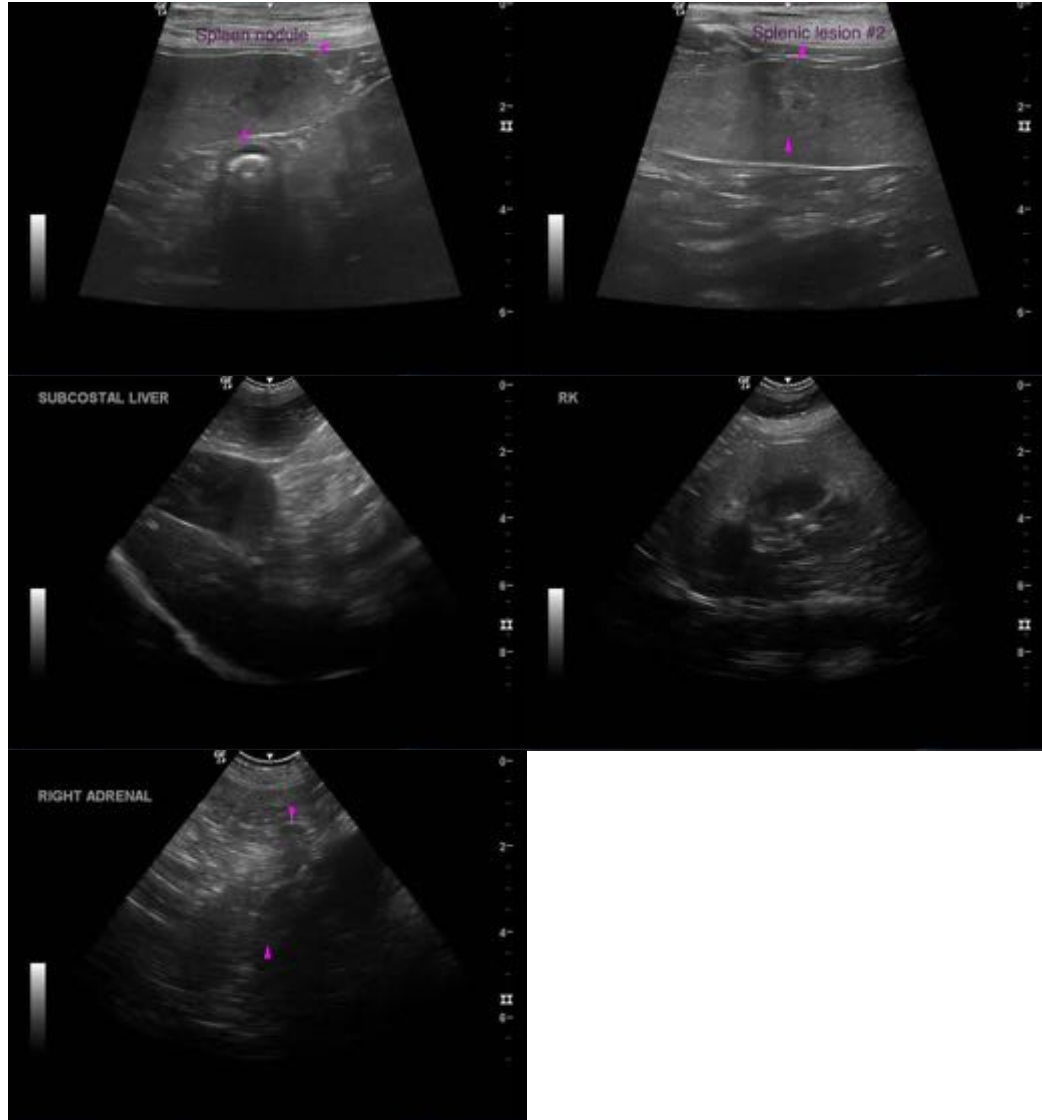
Dr Ashlie Brown

**INVOICE**

12283

**DATE**

2.23.23



The information and recommendations provided are based on the images presented by the referring veterinarian/sonographer. No evaluation can be communicated regarding pathology that was not visible in the image/video clips provided.

Thank you for this referral. If the clinical or image interpretation does not parallel your findings or if I can be of any further assistance, please contact me.

**Andrea Nicastro, MPH, DVM, Diplomate DACVIM (Small Animal Internal Medicine)**  
[info@SonoPath.com](mailto:info@SonoPath.com)