



**PATIENT**

Joey Lachman

**PRESENTING CLINICAL SIGNS**

History: Clinically doing well.

**SPECIES**

Canine

Abnormal PE/Chem/CBC/UA Results: Mass palpated in scrotum for the last few weeks. Cytology consistent with mast cell tumor. BW and three view chest rads are pending.

**BREED**

English Bulldog

**ULTRASONOGRAPHIC EXAMINATION OF THE ABDOMEN**

**Urinary System**

The urinary bladder and visible portion of the pelvic urethra are normal for the degree of luminal distension. The urine is anechoic with no evidence of debris. Cystic calculi and discrete masses are not observed. The region of the trigone and the proximal urethra (visible to a depth of 2 cm) are normal.

**SEX**

Neutered Male

The prostate is normal in size (0.84 cm in width) and shape. Parenchyma is homogenous. The prostatic urethra appears normal without evidence of dilation or obstruction.

**AGE**

9.5 years

The left kidney is normal in size (7.11 cm in length) with a normal shape, architecture and smooth peripheral margins. There is a normal 1:3 cortex to medulla ratio with mild to moderate loss of corticomedullary distinction. There is no evidence of pyelectasia, nephroliths, infarcts or hydroureter.

**WEIGHT**

30.1 kg

The right kidney is normal in size (6.33 cm in length) with a normal shape, architecture and smooth peripheral margins. There is a normal 1:3 cortex to medulla ratio with normal corticomedullary distinction. There is no evidence of pyelectasia, nephroliths, infarcts or hydroureter. Renal vasculature is normal.

**INTERPRETED BY**

Andrea Nicastro, DVM,  
Diplomate ACVIM (Small  
Animal Internal Medicine)

**Adrenal Glands**

The left adrenal gland is normal in size (0.40 cm at cranial pole) (0.48 cm at caudal pole) with a normal shape and homogenous parenchyma. The glandular echogenicity and detail are unremarkable. Capsule, cortex, and medullary definition are normal. The phrenicoabdominal vein and surrounding vasculature are normal.

**IMAGING PERFORMED BY**

Amy Mayhew LVT

The right adrenal gland is in normal size (1.06 cm at cranial pole) (0.57 cm at caudal pole) with a normal shape and homogenous parenchyma. The glandular echogenicity and detail are unremarkable. Capsule, cortex, and medullary definition are normal. The phrenicoabdominal vein and surrounding vasculature are normal.

**HOSPITAL NAME**

SVS Imaging Michigan

**Spleen**

The spleen is normal in size (1.35 cm in width at the level of the hilus) with a normal capsular contour. There is appropriate echogenicity and echotexture. A 1.08 cm hypoechoic nodule is observed near the hilus. Splenic vasculature is normal.

**REFERRING VET**

Dr. Lauren Zeid

**Liver**

The liver is subjectively normal in size with normal curvilinear peripheral contours. The parenchyma is hypoechoic relative to the spleen. There is a questionable 1.40 cm hypoechoic nodule at the caudate lobe. The remaining parenchyma is homogenous. Hepatic vasculature and intrahepatic biliary tracts are of normal volume with no evidence of congestion.

**INVOICE**

12273

The gall bladder lumen is moderately distended. The wall is thin and smooth. Luminal contents are anechoic. The cystic and common bile ducts are normal/not seen.

**DATE**

2.23.23

**Gastrointestinal**

The gastric lumen is moderately distended with ingesta. The gastric wall is normal in thickness with a normal layering pattern. The small intestinal lumen is segmentally dilated with gas and chyme. The small intestinal wall thickness is normal with a normal layering pattern and appropriate mural

**PATIENT**

Joey Lachman

detail. Discreet masses are not identified. The colonic wall is normal. There is no evidence of an obstructive pattern.

**Pancreas**

A portion of the pancreas is obscured by the gastric distention. In the visualized portion no obvious abnormalities are seen.

**SPECIES**

Canine

**Free Abdomen**

The peritoneal cavity is normal. There is no evidence of inflammation or effusion. The abdominal lymph nodes are normal/not visible.

**BREED**

English Bulldog

**ULTRASONOGRAPHIC FINDINGS****Primary Findings**

- The splenic nodule could be consistent with a benign focus of lymphoid hyperplasia, extramedullary hematopoiesis or similar. Alternatively, it may represent a metastatic lesion.

**Secondary Findings**

- Questionable hepatic nodule in the caudate lobe
- Bilateral chronic age-related renal changes
- If the patient was fasted for this study, the presence of ingesta within the gastric lumen could suggest delayed gastric emptying.

**AGE**

9.5 years

**WEIGHT**

30.1 kg

**INTERPRETATION OF THE FINDINGS & FURTHER RECOMMENDATIONS**

- Consider a fine-needle aspirate of the splenic nodule (if clotting status is normal). A 25-gauge needle should be used. Prior to aspiration, the patient should be pre-treated with diphenhydramine to reduce the risk of mast cell degranulation with the procedure.
- Regarding the questionable hepatic nodule, consider a repeat ultrasound in 3-4 weeks to assess for persistence. Alternatively, an abdominal CT scan can be considered.

**INTERPRETED BY**

Andrea Nicastro, DVM,  
Diplomate ACVIM (*Small  
Animal Internal Medicine*)

**IMAGING PERFORMED BY**

Amy Mayhew LVT

**HOSPITAL NAME**

SVS Imaging Michigan

**REFERRING VET**

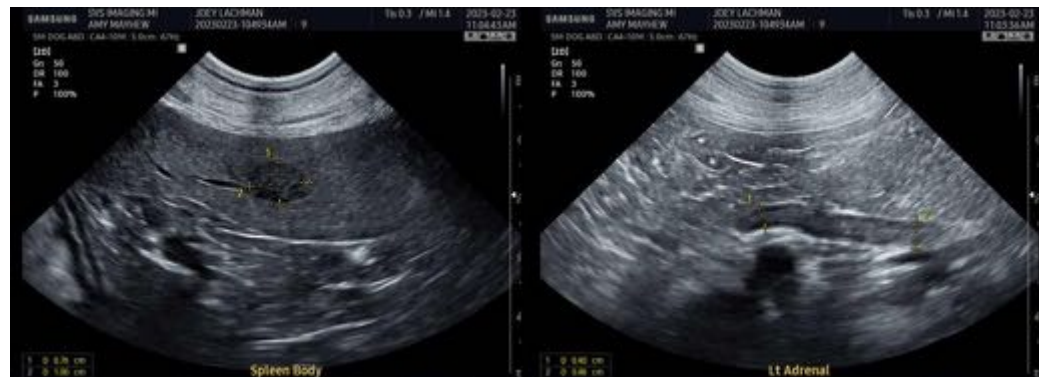Dr. Lauren Zeid

**INVOICE**

12273

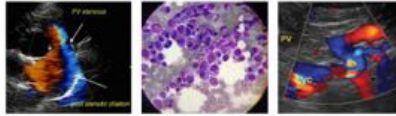
**DATE**

2.23.23



IMAGING PERFORMED BY

svsimagingqc.net 309-737-3070



Clinical Sonography & Telecytology

EDUCATIONAL TELECONSULTATION SERVICES™

1-800-838-4268 info@sonopath.com SonoPath.com

**PATIENT**

Joey Lachman

**SPECIES**

Canine

**BREED**

English Bulldog

**SEX**

Neutered Male

**AGE**

9.5 years

**WEIGHT**

30.1 kg

**INTERPRETED BY**

Andrea Nicastro, DVM,  
Diplomate ACVIM (Small  
Animal Internal Medicine)

**IMAGING PERFORMED BY**

Amy Mayhew LVT

**HOSPITAL NAME**

SVS Imaging Michigan

**REFERRING VET**

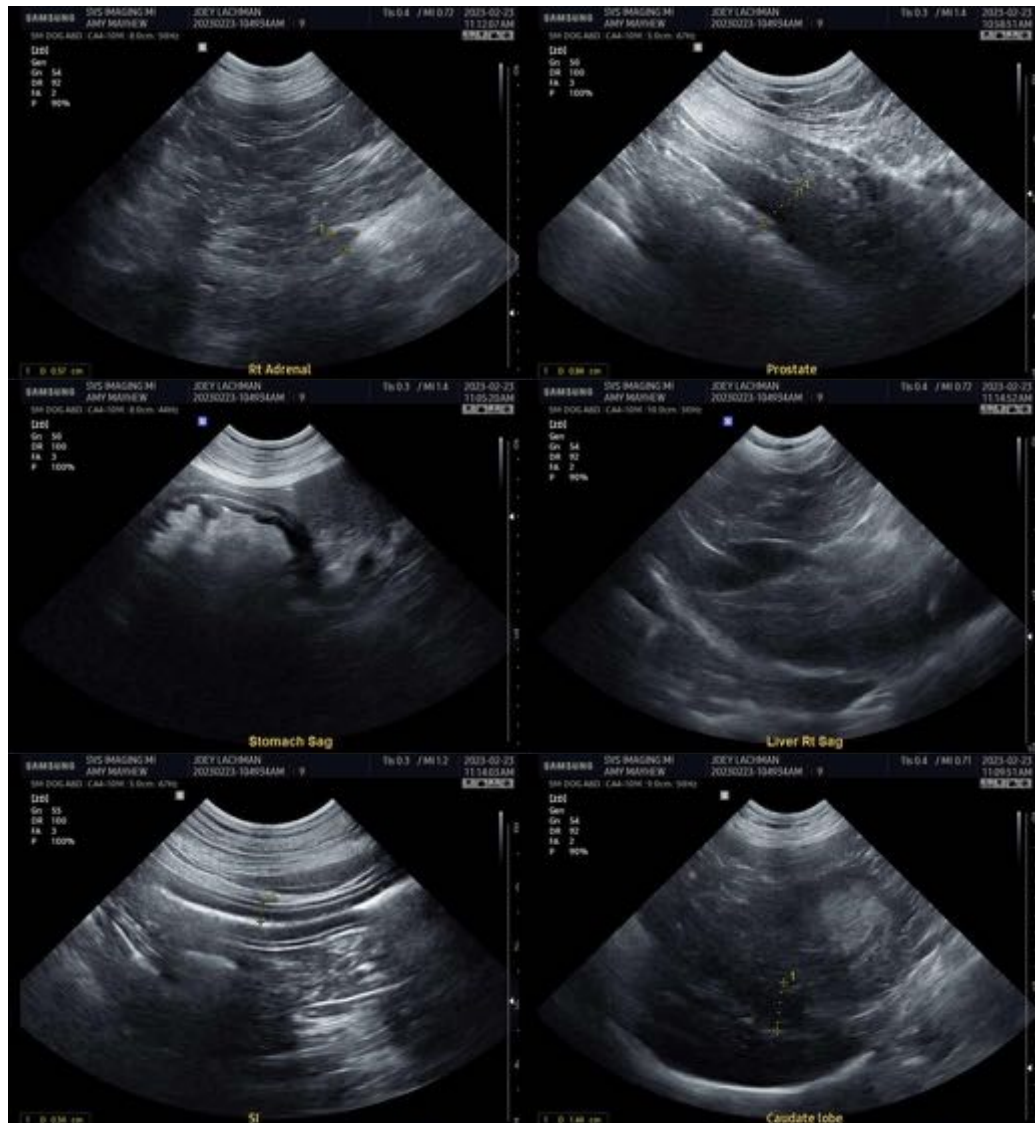
Dr. Lauren Zeid

**INVOICE**

12273

**DATE**

2.23.23



The

information and recommendations provided are based on the images presented by the referring veterinarian/sonographer. No evaluation can be communicated regarding pathology that was not visible in the image/video clips provided.

Thank you for this referral. If the clinical or image interpretation does not parallel your findings or if I can be of any further assistance, please contact me.

Andrea Nicastro, MPH, DVM, Diplomate DACVIM (Small Animal Internal Medicine)  
[info@SonoPath.com](mailto:info@SonoPath.com)