

**DATE PRESENTING CLINICAL SIGNS**

2/23/2022

Pet presented as new pet exam on 2/22. Owners only concern is for resistance to jumping on and off furniture for the past few days. Yelping if touched certain ways. PE: severe dental disease and gingivitis, repeatable pain TL junction and mid lumbar spine. No CP deficits. Heart and lungs auscultate normally. Tense on abdominal palpation.

PATIENT

Madison Grljevic

SPECIES

Canine

BREED

Maltese

SEX

Spayed Female

AGE

2/22/2012

WEIGHT

9.2lbs

Current Medications: Started 2/22- Gabapentin 50mg BID, Methocarbamol 125mg BID, Prednisone 2.5mg BID, Denamarin ¼ SID.

Lab Results: ALT 480, ALKP 576, GGT 23. Reset of chemistry and CBC WNL. 4dx negative.

Date of Previous IntraPet Ultrasound: No previous.

Sedation: Not required to complete full diagnostic ultrasound.

Stat Report: Not requested.

Imaging Performed By: Andi Parkinson, RDMS.

ULTRASONOGRAPHIC EXAMINATION OF THE ABDOMEN**Urinary System**

The urinary bladder, trigone, and pelvic urethra are normal in thickness and the mucosal surface is smooth.

The bladder lumen is moderately distended with mostly anechoic urine. No masses, inflammatory changes or calculi are observed. Ureteral papillae and visualized portion of the proximal urethra, visible to a depth of 2 cm, are normal.

The left kidney is normal size (3.49 cm in length); normal shape and architecture with smooth peripheral margins. There is a normal 1:3 cortex to medulla ratio with minimal to mild loss of corticomedullary distinction. A few nonobstructive nephroliths are visualized. There is no evidence of pyelectasia, infarcts or hydroureter.

INTERPRETED BY

Andrea Nicastro, DMV,
Diplomate DACVIM
(Small Animal
Internal Medicine)

The right kidney is normal size (4.38 cm in length); normal shape and architecture with smooth peripheral margins. There is a normal 1:3 cortex to medulla ratio with minimal to mild loss of corticomedullary distinction. A few nonobstructive nephrolith are visualized. Trace pyelectasia is present. There is no evidence of infarcts or hydroureter.

HOSPITAL NAME

Banfield Towson

Adrenal Glands

The left adrenal gland is normal size (0.51 cm at cranial pole) (0.49 cm at caudal pole) (1.55 cm in length); normal shape; homogenous parenchyma. The glandular echogenicity and detail are unremarkable. Capsule, cortex, and medullary definition are normal. The phrenicoabdominal vein and surrounding vasculature are normal.

REFERRING VET

Dr. Lewis

The right adrenal gland is normal size (0.45 cm at cranial pole) (0.49 cm at caudal pole) (1.56 cm in length); normal shape; homogenous parenchyma. The glandular echogenicity and detail are unremarkable. Capsule, cortex, and medullary definition are normal. The phrenicoabdominal vein and surrounding vasculature are normal.

INVOICE

10444

Spleen

The spleen is normal in size (1.30 cm in width at the level of the hilus) with a normal capsular contour. There is appropriate echogenicity and echotexture. No focal lesions are observed. Splenic

vasculature is normal.

Liver

The liver is subjectively prominent in size with swollen curvilinear peripheral contours. The parenchyma is isoechoic relative to the spleen and exhibits mild heterogeneity. No distinct focal lesions are observed. Hepatic vasculature and biliary tracts are of normal volume with no evidence of congestion.

The gall bladder lumen is moderately distended. The wall is thin and smooth. A moderate amount of aggregated echogenic mostly gravity dependent debris/sludge is observed within the lumen. The cystic and common bile ducts are normal.

Gastrointestinal

The stomach and intestine are free of stasis and exhibit normal peristaltic activity. The gastric lumen is not distended. The gastric wall and pylorus are normal in thickness with a normal layering pattern. The small intestinal lumen is not dilated. The small intestinal wall thickness is normal with a normal layering pattern and appropriate mural detail. Discreet masses are not identified. The colonic wall is normal. No obstructive or overt infiltrative disease is noted.

Pancreas

The region of the pancreas is isoechoic relative to surrounding omental fat. No obvious parenchymal abnormalities are observed. There is no evidence of regional inflammation or effusion.

Free Abdomen

The peritoneal cavity is normal. There is no evidence of inflammation or effusion. The abdominal lymph nodes are normal/not visible.

ULTRASONOGRAPHIC FINDINGS

Primary Findings

- Non-specific diffuse hepatopathy. Differentials include inflammatory disease (i.e., chronic active hepatitis, bacterial cholangiohepatitis, copper hepatotoxicosis, Leptospirosis, infiltrative neoplasia (less likely), +/- concurrent age-related change (i.e., remodeling, regenerative nodular hyperplasia, vacuolar hepatopathy).
- Gall bladder sludge, non-mucocele

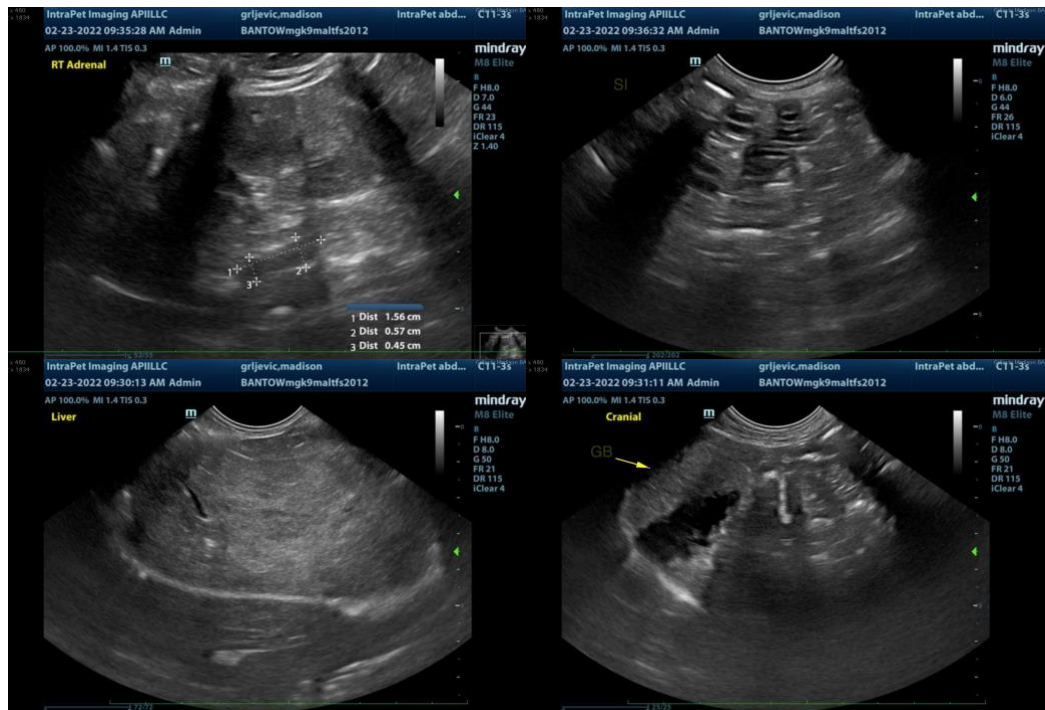
Secondary Findings

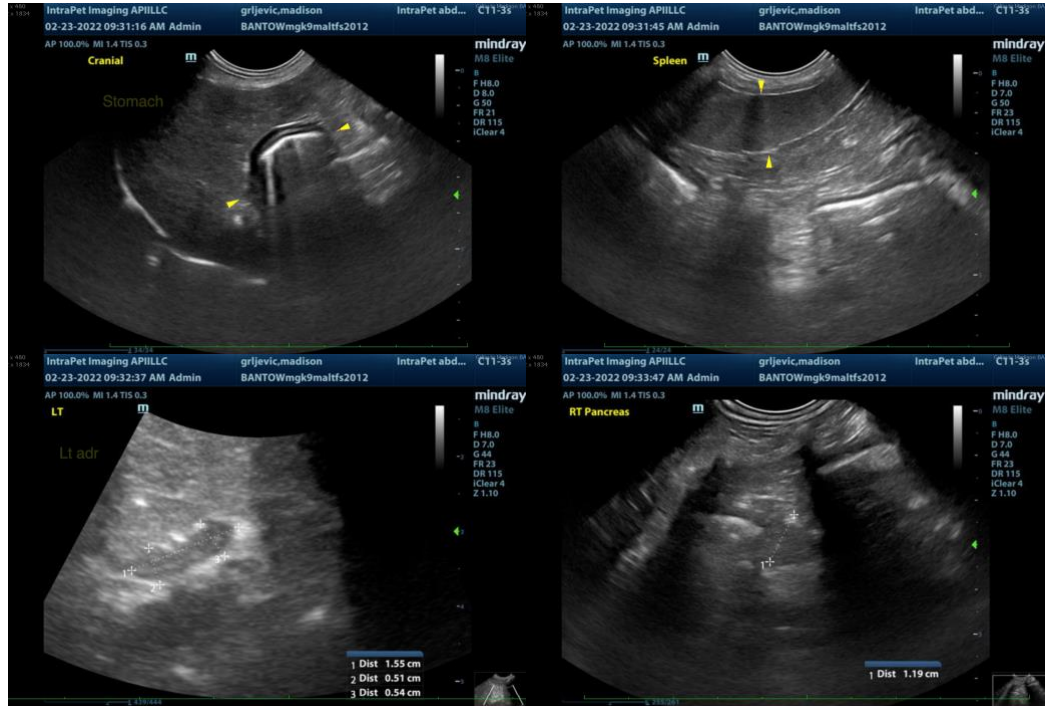
- Bilateral age-related renal changes with nephrocalcinosis

INTERPRETATION OF THE FINDINGS & FURTHER RECOMMENDATIONS

- Pre-and postprandial serum bile acids are recommended to assess hepatic function. Ultimately, hepatic tissue sampling (i.e., fine-needle aspirate or surgical biopsy) may likely be necessary to get a definitive diagnosis. Surgical biopsies would be ideal, as they are more likely to be representative of global organ pathology. If surgery is pursued, aerobic and anaerobic bile cultures and acquisition of additional hepatic tissue samples for potential copper quantitation are recommended.

- If hepatic tissue sampling is not to be pursued at this time, consider empirical treatment for bacterial cholangiohepatitis with broad-spectrum antibiotics (i.e., amoxicillin-clavulanic acid, +/- metronidazole), and hepatic antioxidants. If no improvement in the liver values is seen in 5-7 days of initiating therapy, antibiotics should be discontinued, and further diagnostics pursued.
- Also consider Leptospirosis testing (i.e., blood and urine PCR, serology).





The information and recommendations provided are based on the images presented by the referring veterinarian/sonographer. No evaluation can be communicated regarding pathology that was not visible in the image/video clips provided.

Thank you for this referral. If the clinical or image interpretation does not parallel your findings or if I can be of any further assistance, please contact me.

Andrea Nicastro, DVM, Diplomate DACVIM (Small Animal Internal Medicine)
info@SonoPath.com