



**PATIENT**

Fiona Santana

**SPECIES**

Canine

**BREED**

Miniature Pinscher

**SEX**

Female, spayed

**AGE**

12 Yrs.

**WEIGHT**

13 lbs.

**INTERPRETED BY**

Andrea Nicastro, DVM,  
Diplomate ACVIM  
(Small Animal Internal  
Medicine)

**IMAGING PERFORMED BY**

Dr. Ferrer

**HOSPITAL NAME**

Paseos VC

**REFERRING VET**

Dr. Sierra Archilla

**INVOICE**

13023

**DATE**

2/22/22

**PRESENTING CLINICAL SIGNS**

History: The patient presented as a referral for an abdominal ultrasound to evaluate the urinary tract and bladder. This patient has a history of hematuria and stranguria.

Abnormal PE/Chem/CBC/UA Results: UA: Cystocentesis, Dark yellow, cloudy, pH:6.0, pro:0.3g/L  
Glu: neg, Ket: neg, Bld: 50Ery/uL Bil: neg, Ubg: norm, Leu: 100Leu/uL SG: 1.030 CBC: Lym: 0.61 low  
Eos:0.03 low Chem: Amyl:308 low

**ULTRASONOGRAPHIC EXAMINATION OF THE ABDOMEN**

**Urinary System**

The urinary bladder is mildly to moderately distended. The caudodorsal and caudoventral walls, including the trigone region, are severely thickened (up to 0.86 cm) and irregular with a mass effect. Hyperechoic to mineralized foci are observed within the mass effect. The remaining urinary bladder wall is mildly thickened up to 0.28 cm with a mostly smooth mucosal surface. A scant amount of echogenic debris is observed within the lumen. No cystic calculi are seen.

The left kidney is normal in size (4.25 cm in length) with a normal shape, smooth peripheral margins and normal internal architecture. There is mild loss of corticomedullary distinction. Several hyperechoic shadowing diverticular foci are observed. A few small non-obstructive nephroliths are visualized. There is no evidence of pyelectasia, infarcts or hydroureter.

The right kidney is normal size (4.20 cm in length) with a normal shape, smooth peripheral margins and normal internal architecture. There is mild loss of corticomedullary distinction. Several hyperechoic shadowing diverticular foci are observed. A few small non-obstructive nephroliths are visualized. There is no evidence of pyelectasia, infarcts or hydroureter.

**Adrenal Glands**

The left adrenal gland is normal size (0.41 cm at cranial pole) (0.42 cm at caudal pole) (1.81 cm in length); normal shape; homogenous parenchyma. The glandular echogenicity and detail are unremarkable. Capsule, cortex, and medullary definition are normal. The phrenicoabdominal vein and surrounding vasculature are normal.

The right adrenal gland is normal size (0.66 cm at cranial pole) (0.41 cm at caudal pole) (2.11 cm in length); normal shape; homogenous parenchyma. The glandular echogenicity and detail are unremarkable. Capsule, cortex, and medullary definition are normal. The phrenicoabdominal vein and surrounding vasculature are normal.

**Spleen**

The spleen is normal in size (1.18 cm in width at the level of the hilus) with a normal capsular contour. There is appropriate echogenicity and echotexture. No focal lesions are observed. Splenic vasculature is normal.

**Liver**

The liver is subjectively normal in size with normal contours and structure. There is appropriate echogenicity and echotexture. No overt structural evidence of inflammatory, infiltrative or



**PATIENT**

Fiona Santana

regenerative pathology is evident. Vascular and biliary tracts are of normal volume with no evidence of congestion. No pathological hepatic lymphadenopathy observed. The gall bladder lumen is moderately distended. The wall is thin and smooth. A scant amount of suspended echogenic debris is observed within the lumen. The cystic and common bile ducts are normal/not seen.

**SPECIES**

Canine

**Gastrointestinal**

The stomach and intestine are free of stasis and exhibit normal peristaltic activity. The gastric lumen is not distended. The gastric wall and pylorus are normal in thickness with a normal layering pattern. The pyloric outflow tract is patent. The small intestinal lumen is not dilated. The small intestinal wall thickness is normal with a normal layering pattern and appropriate mural detail. Discreet masses are not identified. The ileocecal colic junction and colonic wall are normal. No obstructive disease is noted.

**BREED**

Miniature Pinscher

**SEX**

Female, spayed

**Pancreas**

The left limb of the pancreas is visible with normal curvilinear peripheral contours. The parenchyma is largely hyperechoic relative to surrounding omental fat and slightly mottled in appearance. The pancreatic duct is visible but not overtly dilated. There is no evidence of peripancreatic inflammation or effusion.

**AGE**

12 Yrs.

**Free Abdomen**

The peritoneal cavity is normal. There is no evidence of inflammation or effusion. The medial iliac lymph nodes are visible, the left measuring 0.75 cm in length and the right measuring 0.85 cm in length. The nodes are normal in shape and echogenicity.

**WEIGHT**

13 lbs.

**INTERPRETED BY**

Andrea Nicaastro, DVM,  
Diplomate ACVIM  
(Small Animal Internal  
Medicine)

**ULTRASONOGRAPHIC FINDINGS**

**Primary Findings:**

- Suspected urinary bladder mass effect in the caudal aspect. Neoplasia (i.e., transitional cell carcinoma) is the top differential. Severe cystitis cannot be completely excluded, but is considered less likely.
- The prominent medial iliac lymph nodes are likely reactive. However, early metastatic disease is possible.

**Secondary Findings:**

- Bilateral degenerative renal changes with dystrophic mineralization and non-obstructive nephrolithiasis.
- Age-related pancreatic remodeling/fibrosis.
- Mild chronic pancreatitis is also possible, particularly if the patient exhibits a positive Murphy's sign.

**IMAGING PERFORMED BY**

Dr. Ferrer

**HOSPITAL NAME**

Paseos VC

**REFERRING VET**

Dr. Sierra Archilla

**INVOICE**

13023

**DATE**

2/22/22



**PATIENT**

Fiona Santana

**SPECIES**

Canine

**BREED**

Miniature Pinscher

**SEX**

Female, spayed

**AGE**

12 Yrs.

**WEIGHT**

13 lbs.

**INTERPRETED BY**

Andrea Nicastro, DVM,  
Diplomate ACVIM  
(Small Animal Internal  
Medicine)

**IMAGING PERFORMED BY**

Dr. Ferrer

**HOSPITAL NAME**

Paseos VC

**REFERRING VET**

Dr. Sierra Archilla

**INVOICE**

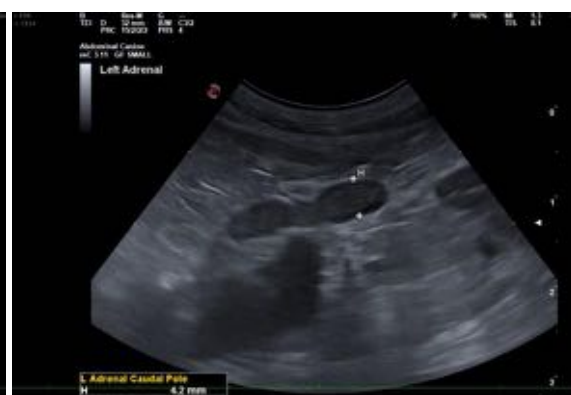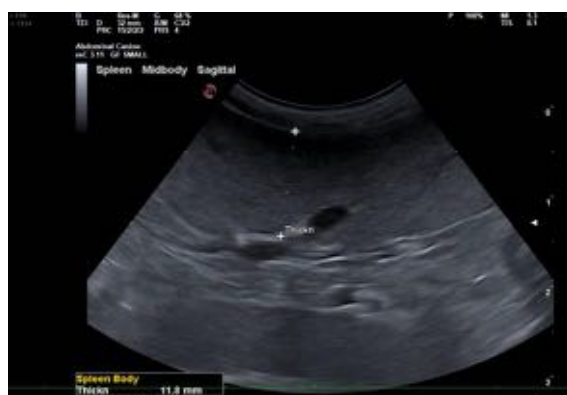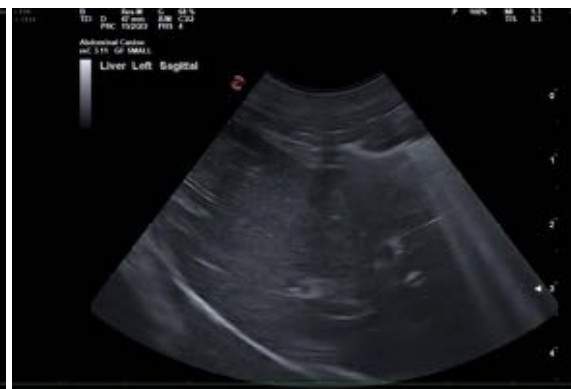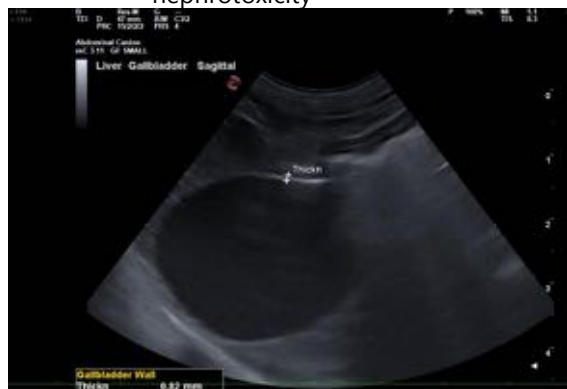13023

**DATE**

2/22/22

**INTERPRETATION OF THE FINDINGS & FURTHER RECOMMENDATIONS**

- Three-view thoracic radiographs should also be considered to assess for pulmonary metastatic disease.
- A urine BRAF test is recommended to further assess for lower urinary tract neoplasia. If bladder neoplasia is confirmed, consultation with a board-certified oncologist can be considered if an aggressive approach is desired. Otherwise, consider the following palliative treatment:
  1. Piroxicam at 0.3 mg/kg PO every 24 hours (may need to be compounded in smaller patients)
  2. Misoprostol (stomach protectant) at 2 mcg/kg PO every 12 hours
  3. Baseline renal values should be performed then repeated every 4 weeks to monitor for nephrotoxicity





**PATIENT**

Fiona Santana

**SPECIES**

Canine

**BREED**

Miniature Pinscher

**SEX**

Female, spayed

**AGE**

12 Yrs.

**WEIGHT**

13 lbs.

**INTERPRETED BY**

Andrea Nicastro, DVM,  
Diplomate ACVIM  
(Small Animal Internal  
Medicine)

**IMAGING PERFORMED BY**

Dr. Ferrer

**HOSPITAL NAME**

Paseos VC

**REFERRING VET**

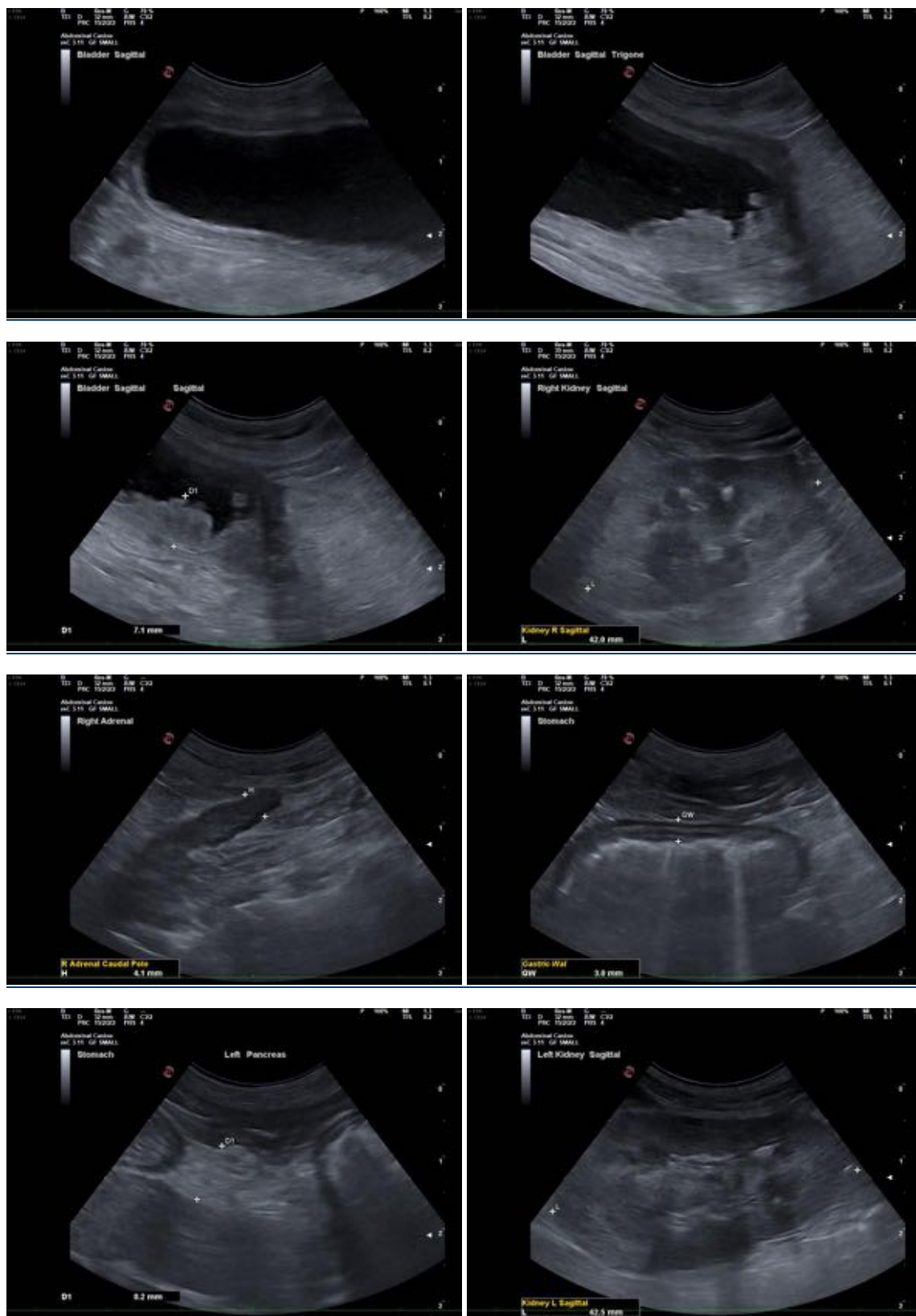
Dr. Sierra Archilla

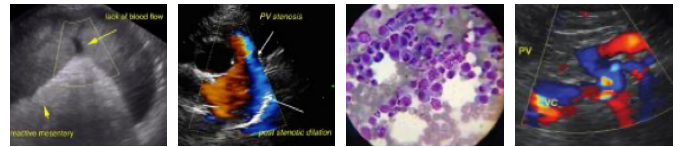
**INVOICE**

13023

**DATE**

2/22/22





**PATIENT**

Fiona Santana

**SPECIES**

Canine

**BREED**

Miniature Pinscher

**SEX**

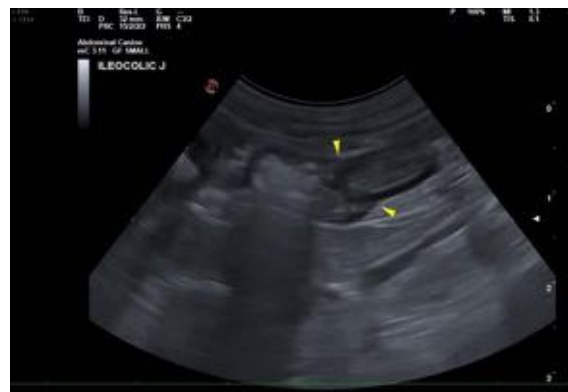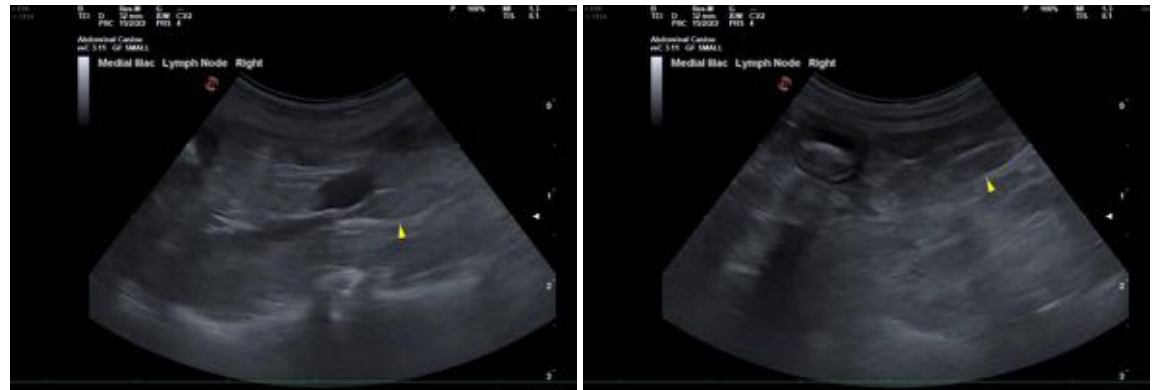
Female, spayed

**AGE**

12 Yrs.

**WEIGHT**

13 lbs.



**INTERPRETED BY**

The information and recommendations provided are based on the images presented by the referring veterinarian/sonographer. No evaluation can be communicated regarding pathology that was not visible in the image/video clips provided.

Andrea Nicastro, DVM,  
Diplomate ACVIM  
(Small Animal Internal  
Medicine)

Thank you for this referral. If the clinical or image interpretation does not parallel your findings or if I can be of any further assistance please contact me.

Andrea Nicastro, DVM, Diplomate ACVIM (Small Animal Internal Medicine)

Andrea.nicastro@sonopath.com

**IMAGING PERFORMED BY**

Dr. Ferrer

**HOSPITAL NAME**

Paseos VC

**REFERRING VET**

Dr. Sierra Archilla

**INVOICE**

13023

**DATE**

2/22/22