**DATE PRESENTING CLINICAL SIGNS**

2/21/23

10d hx of progressive decreased appetite, lethargy, vomiting, decreased interest in food. Painful on abd palpation, mildly febrile (102), dramatic 2 lb weight loss over 10 days, slight delay in skin tenting. No FB noted under tongue, mm pink, moist. marked weight loss, painful abdomen; concern for FB vs FIP vs other i.e. pancreatitis. In-house rads and US showed scant to no effusion, no obvious linear or obstructive pattern. P was imported from Ukraine as 10w kitten.

PATIENT

Hannah Bahr

SPECIES

Feline

BREED

Maine Coon

SEX

Female, spayed

AGE

9/7/2021

WEIGHT

11.7 lbs.

INTERPRETED BY

Andrea Nicastro, DVM,
 Diplomate ACVIM
 (*Small Animal Internal
 Medicine*)

HOSPITAL NAME

Hicory VH

REFERRING VET

Dr. McCourt

INVOICE

14622

Current Medications: Amoxicillin 11mg/kg 2/20 pm, Metronidazole 20mg/kg since 2/20 pm, Cerenia 1mg/kg since 2/20 pm, LRS 8ml/kg/hr since 2/20 pm

Lab Results: FIV/FELV negative 2/20/23. Chem 17 WNL; Amylase low, Ca Low, NA/CL low (mild). CBC- HCT high (61%), Lymphocytes H (16k)

Radiographs: possible thickening of gastric wall, no obvious obstructive pattern

Date of Previous IntraPet Ultrasound: No previous.

Sedation: Not required to complete full diagnostic ultrasound.

Stat Report: Not requested.

Imaging Performed By: Stephanie Warga RDCS, RVT.

ULTRASONOGRAPHIC EXAMINATION OF THE ABDOMEN**Urinary System**

The urinary bladder wall is normal in thickness and the mucosal surface is smooth. The bladder lumen is moderately distended with anechoic urine. No masses, inflammatory changes or calculi are observed. Ureteral papillae and visualized portion of the proximal urethra, visible to a depth of 1-2 cm, are normal.

The left kidney is normal size (3.46 cm in length); normal shape and architecture with smooth peripheral margins. There is a normal 1:3 cortex to medulla ratio with normal corticomedullary distinction. Trace pyelectasia is present (0.13 cm in the transverse plane). There is no evidence of nephroliths, infarcts or hydronephrosis. Renal vasculature is normal.

The right kidney is normal size (3.69 cm in length); normal shape and architecture with smooth peripheral margins. There is a normal 1:3 cortex to medulla ratio with normal corticomedullary distinction. Trace pyelectasia is present (0.13 cm in the transverse plane). There is no evidence of nephroliths, infarcts or hydronephrosis. Renal vasculature is normal.

Adrenal Glands

The left adrenal gland is normal in size (0.29 cm width). Normal shape and glandular echogenicity. The phrenicoabdominal vein and surrounding vasculature are normal.

The right adrenal gland is normal in size (0.33 cm width). Normal shape and glandular echogenicity. The phrenicoabdominal vein and surrounding vasculature are normal.

Spleen

The spleen is normal in size (0.83 cm in width at the level of the hilus) with a normal capsular contour. There is appropriate echogenicity and echotexture. No focal lesions are observed. Splenic vasculature is normal.

Liver

The liver is subjectively normal in size with normal contours and structure. There is appropriate echogenicity and echotexture. No overt structural evidence of inflammatory, infiltrative or regenerative pathology is evident. Vascular and biliary tracts are of normal volume with no evidence of congestion. No pathological hepatic lymphadenopathy observed. The gall bladder lumen is moderately distended. The wall is thin and smooth. A moderate amount of suspended echogenic debris is observed within the lumen. The cystic and common bile ducts are normal.

Gastrointestinal

The gastric lumen is not distended. The gastric wall and pylorus are normal in thickness with a normal layering pattern. The pyloric outflow tract is patent. A few small intestinal segments are fluid distended with a small amount of shadowing material within these segments. There is a 2-3 cm segment of small intestine that is thickened (up to 0.33 cm) with possible loss of the normal layering pattern. In the remaining small intestinal segments, the wall is normal thickness with retention of the normal layering pattern. There is disruption in the normal 1:3 muscularis: mucosal ratio in most segments. The colonic wall is normal.

Pancreas

The pancreas is normal in size with normal peripheral contours. The pancreatic duct is normal. The base and limbs of the pancreas are isoechoic to surrounding omental fat. No focal lesions are observed. There is no evidence of peripancreatic inflammation or effusion.

Free Abdomen

There is no obvious evidence of free fluid. A few prominent mesenteric lymph nodes are visualized, the largest measuring 2.03 cm in length. Surrounding mesentery is hyperechoic.

ULTRASONOGRAPHIC FINDINGS

Primary Findings:

- The focal bowel wall thickening with questionable loss of the normal layering pattern could be consistent with emerging neoplasia or an inflammatory process. The diffuse small intestinal wall changes could be consistent with inflammatory bowel disease or emerging lymphoma. The small amount of shadowing material within the small intestinal lumen may represent foreign material (i.e., hair) or chyme. It does not appear to be overtly obstructive at this time.
- The prominent abdominal lymph nodes are most consistent with reactive lymphadenitis or lymphoid hyperplasia. Neoplastic infiltration is considered less likely.

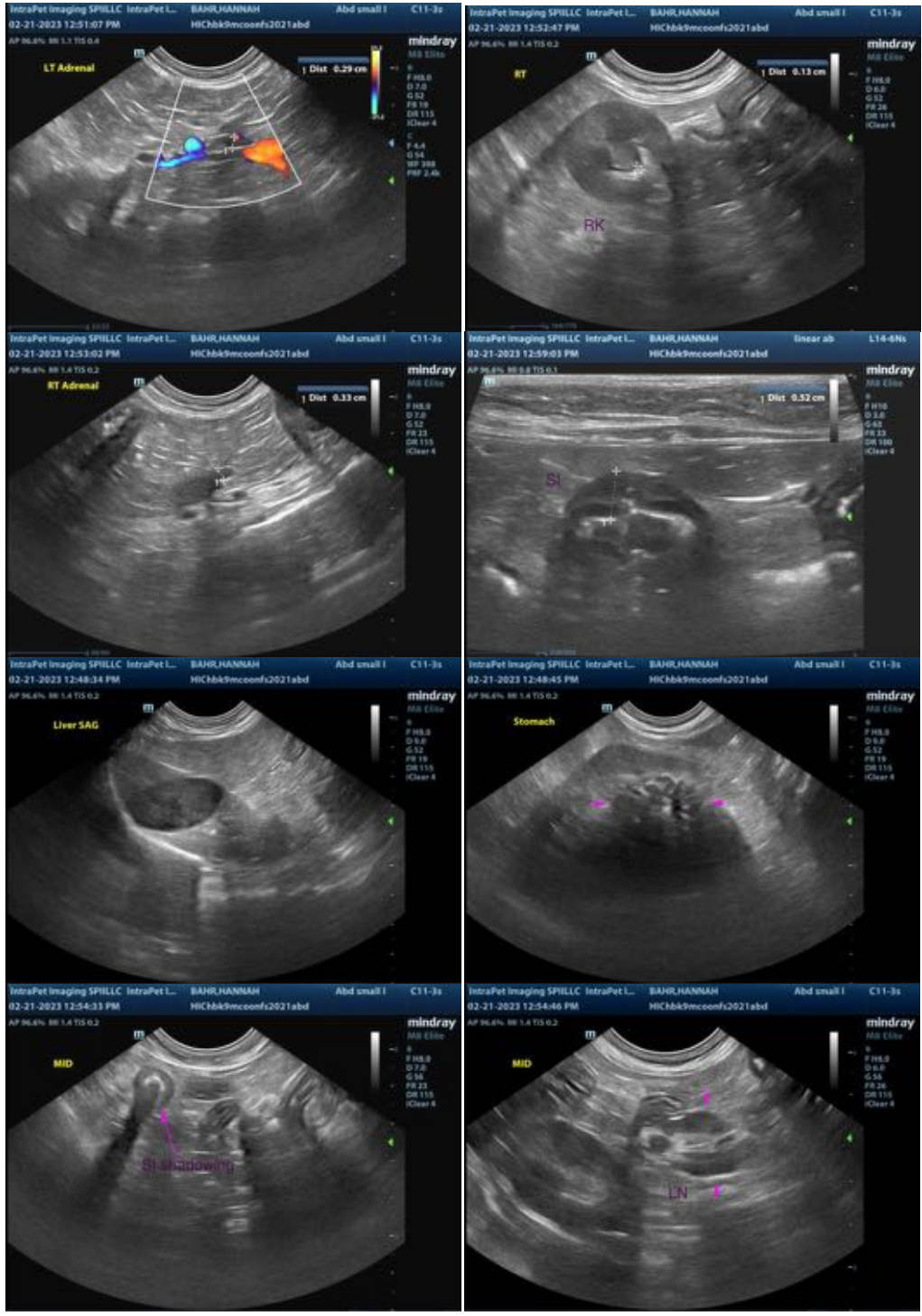
Secondary Findings:

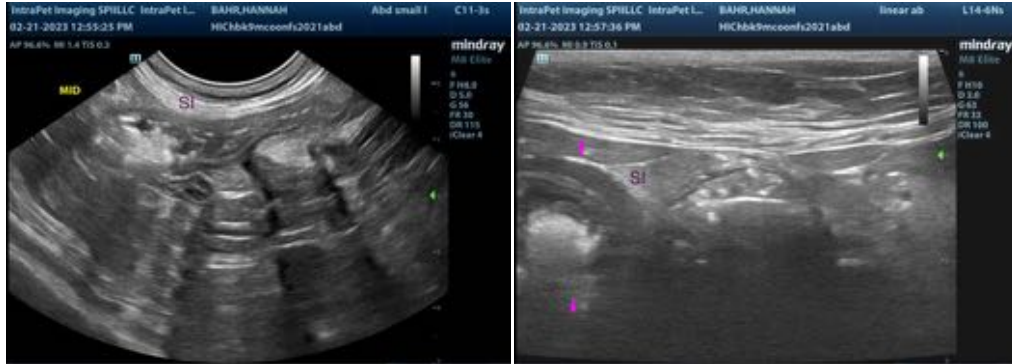
- The trace pyelectasia in both kidneys may be secondary to IV fluid therapy (if applicable), pyelonephritis, PU/PD (if present), other.

INTERPRETATION OF THE FINDINGS & FURTHER RECOMMENDATIONS

Given the patient's clinical history and sonographic changes, consider the following:

1. CBC with clinical pathology review (given the lymphocytosis).
2. Three-view thoracic radiographs to evaluate for occult neoplasia in the chest.
3. GI panel including serum cobalamin folate, TLI and PLI.
4. Surgical GI biopsies may be necessary to get a definitive diagnosis.
5. While awaiting test results, symptomatic care as well as nutritional support is recommended.





The information and recommendations provided are based on the images presented by the referring veterinarian. No evaluation can be communicated regarding pathology that was not visible in the image/video clips provided.

Thank you for this referral. If the clinical or image interpretation does not parallel your findings or if I can be of any further assistance please contact me.

Andrea Nicastro, MPH, DVM, Diplomate DACVIM (Small Animal Internal Medicine)
info@SonoPath.com