**DATE PRESENTING CLINICAL SIGNS**

2/21/23

Vomits regularly after drinking water – no response to tx for gastritis.

PATIENT

Boomer Gamble

Current Medications: Tx for helicobacter/gastritis- Amoxi 1000mg BID x10, Metronidazole 750mg BID x10, Omeprazole 40mgSID, Sucralfate 1gm TID, Cerenia 160mg SID x4d.

Lab Results: NSF.

Radiographs: Unremarkable thorax and abdomen.

Date of Previous IntraPet Ultrasound: No previous.

Sedation: Traz PO and Dexdomitor IV.

SPECIES

Canine

Stat Report: Not requested.

Imaging Performed By: Stephanie Warga RDCS, RVT.

BREEDGerman Shorthair
Pointer**ULTRASONOGRAPHIC EXAMINATION OF THE ABDOMEN****Urinary System**

The urinary bladder wall is normal in thickness and the mucosal surface is smooth. The bladder lumen is moderately distended with anechoic urine. No masses, inflammatory changes or calculi are observed. Ureteral papillae and visualized portion of the proximal urethra, visible to a depth of 1-2 cm, are normal.

SEX

Male, neutered

The prostate is normal in size (1.19 cm in width) and shape. Parenchyma is homogenous. The prostatic urethra appears normal without evidence of dilation or obstruction.

AGE

6/30/2019

The left kidney is normal size (7.08 cm in length); normal shape and architecture with smooth peripheral margins. There is a normal 1:3 cortex to medulla ratio with normal corticomedullary distinction. There is no evidence of pyelectasia, nephroliths, infarcts or hydroureter. Renal vasculature is normal.

**WEIGHT
86.5 lbs.**

The right kidney is normal size (6.25 cm in length); normal shape and architecture with smooth peripheral margins. There is a normal 1:3 cortex to medulla ratio with normal corticomedullary distinction. There is no evidence of pyelectasia, nephroliths, infarcts or hydroureter. Renal vasculature is normal.

INTERPRETED BYAndrea Nicastro, DVM,
Diplomate ACVIM
(Small Animal Internal
Medicine)**Adrenal Glands**

The left adrenal gland is normal size (0.61 cm at cranial pole) (0.70 cm at caudal pole) (3.26 cm in length); normal shape; homogenous parenchyma. The glandular echogenicity and detail are unremarkable. Capsule, cortex, and medullary definition are normal. The phrenicoabdominal vein and surrounding vasculature are normal.

HOSPITAL NAME

Hickory VH

The right adrenal gland is normal size (0.78 cm at cranial pole) (0.77 cm at caudal pole) (2.87 cm in length); normal shape; homogenous parenchyma. The glandular echogenicity and detail are unremarkable. Capsule, cortex, and medullary definition are normal. The phrenicoabdominal vein and surrounding vasculature are normal.

REFERRING VET

Dr. Snyder

Spleen

The spleen is normal in size (2.21 cm in width at the level of the hilus) with a normal capsular contour. The parenchyma is subtly mottled in appearance. No focal lesions are observed. Splenic vasculature is normal.

INVOICE

14621

Liver

The liver is subjectively normal in size with normal contours and structure. There is appropriate echogenicity and echotexture. No overt structural evidence of inflammatory, infiltrative or regenerative pathology is evident. Vascular and biliary tracts are of normal volume with no evidence of congestion. No pathological hepatic lymphadenopathy observed. The gall bladder lumen is moderately distended. The wall is thin and smooth. Luminal contents are anechoic. The cystic and common bile ducts are normal/not seen.

Gastrointestinal

The gastric lumen is mildly gas distended. The gastric wall is normal in thickness with a normal layering pattern. The small intestinal lumen is not dilated. The small intestinal wall thickness is normal with a normal layering pattern and appropriate mural detail. Discreet masses are not identified. The colonic wall is normal. There is no evidence of an obstructive pattern.

Pancreas

The region of the pancreas is isoechoic relative to surrounding omental fat. No obvious parenchymal abnormalities are observed. There is no evidence of regional inflammation or effusion.

Free Abdomen

The peritoneal cavity is normal. There is no evidence of inflammation or effusion. The abdominal lymph nodes are normal/not visible.

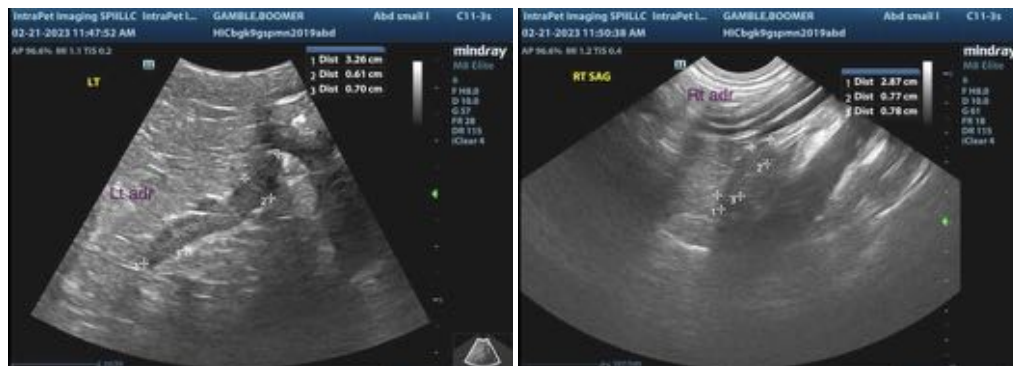ULTRASONOGRAPHIC FINDINGS

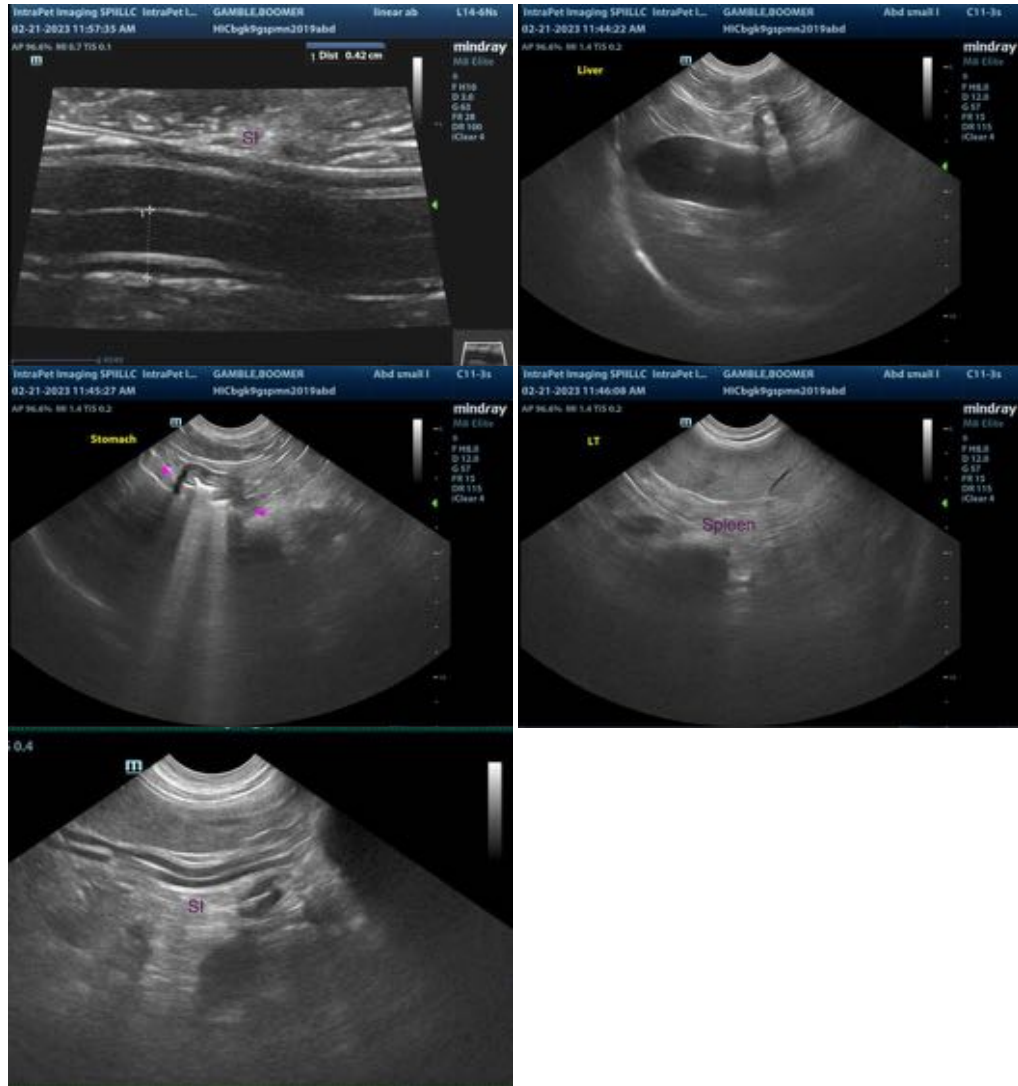
- The splenic parenchymal changes are most consistent with a benign process such as lymphoid hyperplasia, extramedullary hematopoiesis, splenitis or antigenic stimulation with a low possibility of infiltrative neoplasia (i.e., lymphoma, mast cell neoplasia).

*An obvious for the patient's clinical signs is not identified in this study. Considerations include primary gastrointestinal disease (i.e., esophageal dysfunction, esophagitis, gastric reflux, infectious/parasitic disease, food allergy/intolerance, inflammatory bowel disease), underlying metabolic issue, mild pancreatitis, other.

INTERPRETATION OF THE FINDINGS & FURTHER RECOMMENDATIONS

- Three-view thoracic radiographs are recommended to assess for occult esophageal disease. If regurgitation is suspected, consider a barium esophogram, preferably via fluoroscopy.
- A fecal evaluation for ova/Giardia.
- A malabsorption panel including serum cobalamin, folate, TLI, PLI and a resting cortisol level (send to Texas A&M) is recommended.
- Consider a limited antigen or hydrolyzed protein diet trial.
- Depending on the results of the above diagnostics/therapeutics, endoscopic or surgical GI biopsies may be necessary to get a definitive diagnosis. Endoscopic biopsies may be preferable in that the esophageal and gastric mucosa can be directly evaluated.
- In the meantime, symptomatic care should be continued. Initiation of a probiotic may also be beneficial.





The information and recommendations provided are based on the images presented by the referring veterinarian. No evaluation can be communicated regarding pathology that was not visible in the image/video clips provided.

Thank you for this referral. If the clinical or image interpretation does not parallel your findings or if I can be of any further assistance please contact me.

Andrea Nicastro, MPH, DVM, Diplomate DACVIM (Small Animal Internal Medicine)
info@SonoPath.com