

**DATE**

2/21/22

**PRESENTING CLINICAL SIGNS**

Patient presents for evaluation of hematuria.

**PATIENT**

Bella Rivas

Current Medications: None current but Gabapentin and Trazodone for scan.

Lab Results: UTI- treating currently for this, will get sterile sample during AUS. Historical increased ALP, mild, LDDST not supportive for Cushing's per rDVM.

CBC WNL, SDMA 15, ALP 412, USG 1.032, 3+ proteinuria, hematuria, bacteriuria and a normal T4. PT/PTT normal.

**SPECIES**

Canine

Date of Previous IntraPet Ultrasound: No previous.

Sedation: Not required to complete full diagnostic ultrasound.

Stat Report: Not requested.

**BREED**

Mixed breed

Imaging Performed By: Andi Parkinson, RDMS.

**SEX**

Female, spayed

**ULTRASONOGRAPHIC EXAMINATION OF THE ABDOMEN****Urinary System**

The urinary bladder is mildly to moderately distended with anechoic urine. The wall in the region of the apex is thickened (up to 0.61 cm) and irregular. The wall tapers to a normal thickness as it extends toward the urinary bladder neck. No cystic calculi are observed. The region of the trigone and the visible portion of the proximal urethra are normal.

**AGE**

12/6/2007

The left kidney is normal in size (6.66 cm in length) with a normal shape, smooth peripheral margins and normal internal architecture. There is mild loss of corticomedullary distinction. Several hyperechoic shadowing diverticular foci are observed. There is no evidence of pyelectasia, infarcts or hydronephrosis. At least 2 irregular cortical cysts are visualized, the largest measuring 1.87 cm in diameter. The larger cyst causes some distortion of the renal medullary architecture.

**WEIGHT**

52 lbs.

**INTERPRETED BY**

Andrea Nicastro, DVM,  
 Diplomate ACVIM  
 (Small Animal Internal  
 Medicine)

The right kidney is normal in size (6.31 cm in length) with a normal shape, smooth peripheral margins and normal internal architecture. There is mild loss of corticomedullary distinction. Several hyperechoic shadowing diverticular foci are observed. There is no evidence of pyelectasia, infarcts or hydronephrosis. A few small cortical cysts are present.

**HOSPITAL NAME**

Perry Hall AH

**Adrenal Glands**

The left adrenal gland is normal size (0.55 cm at cranial pole) (0.58 cm at caudal pole) (2.68 cm in length); normal shape; homogenous parenchyma. The glandular echogenicity and detail are unremarkable. Capsule, cortex, and medullary definition are normal. The phrenicoabdominal vein and surrounding vasculature are normal.

**REFERRING VET**

Dr. Miller

The right adrenal gland is normal size (0.85 cm at cranial pole) (0.73 cm at caudal pole) (2.96 cm in length); normal shape; homogenous parenchyma. The glandular echogenicity and detail are unremarkable. Capsule, cortex, and medullary definition are normal. The phrenicoabdominal vein and surrounding vasculature are normal.

**INVOICE**

13000

**Spleen**

The spleen is normal in size (1.72 cm in width at the level of the hilus) with a normal capsular contour. There is appropriate echogenicity and echotexture. Several ill-defined hypoechoic nodules are observed, mainly at the cranial aspect. Splenic vasculature is normal.

### ***Liver***

The liver is prominent in size with normal curvilinear peripheral contours. The parenchyma is isoechoic relative to the spleen and exhibits subtle heterogeneity. A 1.41 cm irregular hyperechoic nodule with tiny cystic areas is observed on the left side. Vascular and biliary tracts are of normal volume with no evidence of congestion. The gall bladder lumen is distended. The wall is thin and smooth. A moderate amount of echogenic to mineralized debris is observed within the lumen, some of which is gravity-dependent and some of which is suspended. The cystic and common bile ducts are normal/not seen.

### ***Gastrointestinal***

The stomach and intestine are free of stasis and exhibit normal peristaltic activity. The gastric lumen is mildly distended with ingesta. The gastric wall and pylorus are normal in thickness with a normal layering pattern. The pyloric outflow tract is patent. The small intestinal lumen is not dilated. The small intestinal wall thickness is normal with a normal layering pattern and appropriate mural detail. Discreet masses are not identified. The colonic wall is normal. No obstructive disease is noted.

### ***Pancreas***

The region of the pancreas is isoechoic relative to surrounding omental fat. No obvious parenchymal abnormalities are observed. There is no evidence of regional inflammation or effusion.

### ***Free Abdomen***

The peritoneal cavity is normal. There is no evidence of inflammation or effusion. The abdominal lymph nodes are normal/not visible.

### ***Other***

A brief echocardiogram reveals no evidence of pericardial effusion.

## **ULTRASONOGRAPHIC FINDINGS**

### **Primary Findings:**

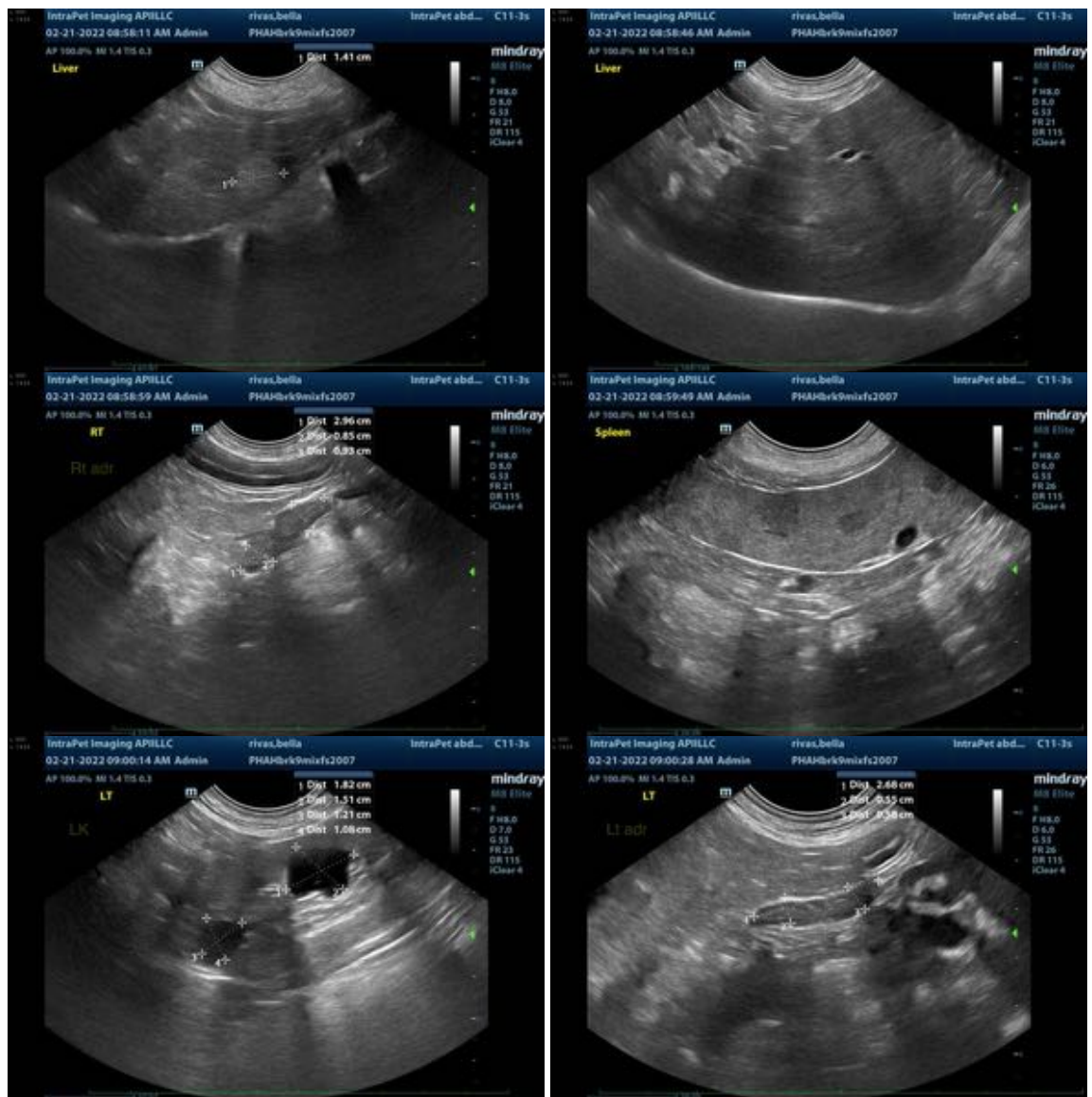- The urinary bladder wall changes are most consistent with cystitis with lower potential for neoplasia.
- The hypoechoic splenic nodules could be consistent with neoplasia (i.e., round cell tumor). Alternatively, a benign process such as lymphoid hyperplasia is also possible.
- The hyperechoic hepatic nodule trends toward the benign (i.e., regenerative nodule) with some potential for emerging neoplasia. The diffuse hepatic parenchymal changes are most consistent with a benign hepatopathy (i.e., regenerative nodular hyperplasia and/or vacuolar hepatopathy).
- Gallbladder debris, non-mucocele.

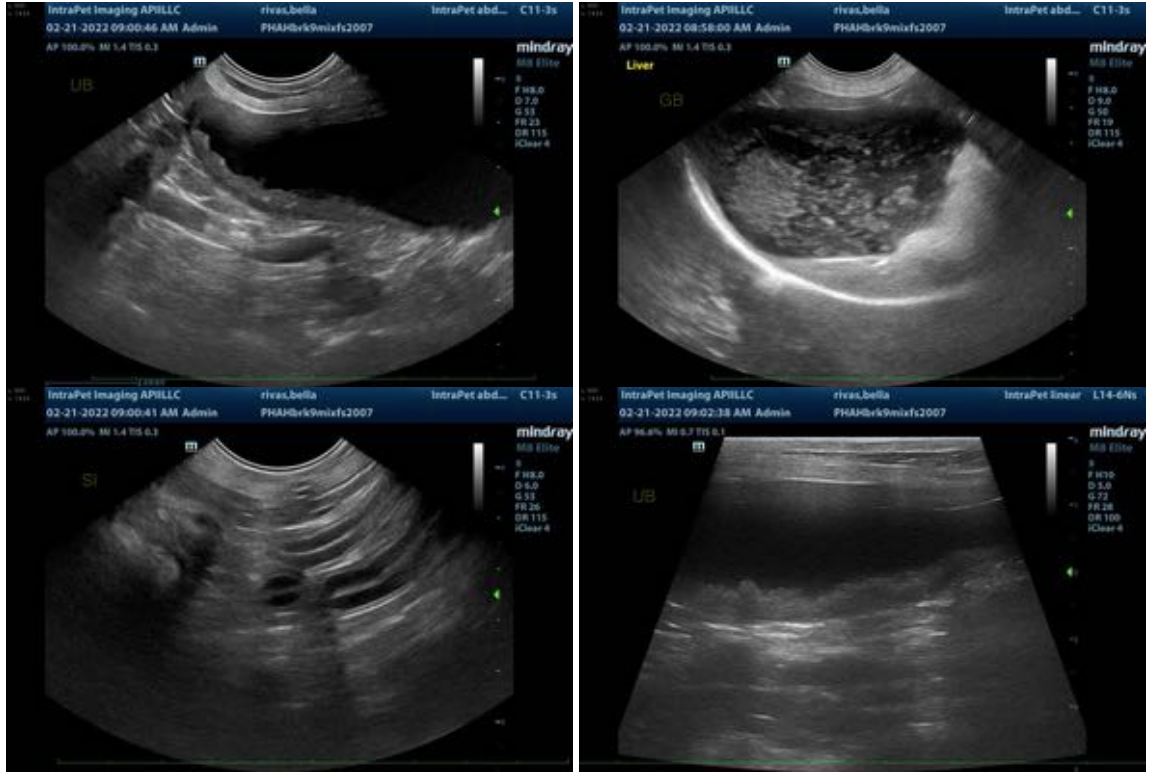
### **Secondary Findings:**

- Bilateral age-related renal changes with dystrophic mineralization and cortical cysts (larger in the left kidney).

## **INTERPRETATION OF THE FINDINGS & FURTHER RECOMMENDATIONS**

- Urine culture and sensitivity.
- Consider a fine needle aspirate of the splenic +/- hepatic nodules. 25-gauge needles should be used.
- Also consider a repeat ultrasound in 4-8 weeks to assess for progression of the nodules and to reevaluate the urinary bladder wall.
- Three-view thoracic radiographs are recommended to assess cardiopulmonary status.





**The information and recommendations provided are based on the images presented by the referring veterinarian. No evaluation can be communicated regarding pathology that was not visible in the image/video clips provided.**

Thank you for this referral. If the clinical or image interpretation does not parallel your findings or if I can be of any further assistance please contact me.

Andrea Nicastro, DVM, Diplomate ACVIM (*Small Animal Internal Medicine*)  
Andrea.nicastro@sonopath.com