**PATIENT**Irah Sokolova  
56529A**SPECIES**

Canine

**BREED**

German Shepherd

**SEX**

Intact Female

**AGE**

6 years 8 mos

**WEIGHT**

31.2 kg

**INTERPRETED BY**Andrea Nicastro, DVM,  
Diplomate ACVIM  
(Small Animal Internal  
Medicine)**IMAGING PERFORMED BY**

Tom McNeill

**HOSPITAL NAME**

SVS Imaging CT

**REFERRING VET**Madison Vet Spec  
Dr. Calhoun**INVOICE**

12253

**DATE**

2.20.23

**PRESENTING CLINICAL SIGNS**

History: Irah presented to the MVS Emergency Service on Feb 19, 2023, at 12pm, for evaluation of dribbling urine. Irah was seen here 10 days ago (2/9) for increased thirst / urination and constipation. We sent her home with Carprofen, Lactulose, Clavamox, and Gabapentin. Irah seemed to improve with the medications. Wednesday night (2/15), Irah began straining to urinate. This continued until Friday, when she was evaluated at her pcDVM. The pcDVM found that her UTI had resolved, but she was still unable to urinate. They restarted Carprofen and sent her home. At that point, Irah completely stopped urinating. This morning Irah began dribbling urine. Over the past two weeks, she has been eating and drinking normally. She has a history of constipation.

Abnormal PE/Chem/CBC/UA Results: Urogenital: FI; hooded vulva with urine-soaked fur of rear end; large urinary bladder, unable to express; patient is straining without production outside Rectal: Under sedation after ucath placement - no palpable stone or mass appreciated Renal panel: WNL UA: Collected from ucath, UA - USG 1.023, 3 RBC/hpf, 1 WBC/hpf, no bacteria, no crystals.

**ULTRASONOGRAPHIC EXAMINATION OF THE ABDOMEN****Urinary System**

The urinary bladder is mildly distended. A Foley catheter is observed within the lumen. The wall is moderately thickened (1.02 cm) and slightly irregular, with a heterogenous appearance. A scant amount of echogenic debris is observed within the lumen. No cystic calculi are observed. The proximal urethra is difficult to evaluate due to the presence of the urinary catheter. However, mild wall thickening is suspected.

The left kidney is normal in size (7.93 cm in length) with a normal shape, architecture and smooth peripheral margins. There is a normal 1:3 cortex to medulla ratio with normal corticomedullary distinction. There is no evidence of pyelectasia, nephroliths, infarcts or hydroureter.

The right kidney is normal in size (7.84 cm in length) with a normal shape, architecture and smooth peripheral margins. There is a normal 1:3 cortex to medulla ratio with normal corticomedullary distinction. There is no evidence of pyelectasia, nephroliths, infarcts or hydroureter. Renal vasculature is normal.

**Adrenal Glands**

The left adrenal gland is normal in size (0.65 cm at cranial pole) (0.83 cm at caudal pole) with a normal shape and homogenous parenchyma. The glandular echogenicity and detail are unremarkable. Capsule, cortex, and medullary definition are normal. The phrenicoabdominal vein and surrounding vasculature are normal.

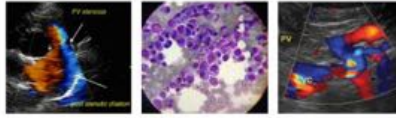
The right adrenal gland is in normal size (0.82 cm at cranial pole) (0.76 cm at caudal pole) with a normal shape and homogenous parenchyma. The glandular echogenicity and detail are unremarkable. Capsule, cortex, and medullary definition are normal. The phrenicoabdominal vein and surrounding vasculature are normal.

**Spleen**

The spleen is normal in size (2.04 cm in width at the level of the hilus) with a normal capsular contour. There is appropriate echogenicity and echotexture. No focal lesions are observed. Splenic vasculature is normal.

**Liver**

The liver is subjectively normal in size with normal contours and structure. There is appropriate echogenicity and echotexture. No overt structural evidence of inflammatory, infiltrative, or regenerative pathology is evident. Vascular and biliary tracts are of normal volume with no evidence of congestion. No pathological hepatic lymphadenopathy observed.

**PATIENT**Irah Sokolova  
56529A

The gall bladder lumen is moderately distended. The wall is thin and smooth. Luminal contents are anechoic. The cystic and common bile ducts are normal/not seen.

**SPECIES**

Canine

**Gastrointestinal**

The stomach and intestine are free of stasis and exhibit normal peristaltic activity. The gastric lumen is not distended. The gastric wall and pylorus are normal in thickness with a normal layering pattern. The pyloric outflow tract is patent. The small intestinal lumen is not dilated. The small intestinal wall thickness is normal with a normal layering pattern and appropriate mural detail. Discreet masses are not identified. The ileocecolic junction and colonic wall are normal. There is no evidence of an obstructive pattern.

**BREED**

German Shepherd

**Pancreas**

The region of the pancreas is isoechoic relative to surrounding omental fat. No obvious parenchymal abnormalities are observed. There is no evidence of regional inflammation or effusion.

**SEX**

Intact Female

**Free Abdomen**

There is no obvious evidence free fluid. The medial iliac lymph nodes are visualized (left: 3.12 x 1.07 cm) (right 3.38 x 1.09 cm). A few prominent mesenteric lymph nodes are also seen (the largest measuring 2.21 cm in length). The nodes are normal in shape and echogenicity.

**AGE**

6 years 8 mos

**Other**

The uterine body is visible and is normal in size (0.75 cm in width). No obvious pathology is observed. The left and right uterine horns are also visible. No obvious abnormalities are seen.

**WEIGHT**

31.2 kg

The ovaries are subjectively normal in size (left: 1.81 x 0.89 cm) (right: 2.77 x 1.99 cm). No obvious pathology is observed.

**ULTRASONOGRAPHIC FINDINGS****INTERPRETED BY**

Andrea Nicastro, DVM,  
Diplomate ACVIM  
(Small Animal Internal  
Medicine)

**Primary Findings**

- The urinary bladder +/- urethral wall thickening could be consistent with cystitis or infiltrative neoplasia (i.e., transitional cell carcinoma). The wall thickening may be somewhat artifactual due to lack of luminal distention.

**IMAGING PERFORMED BY**

Tom McNeill

**Secondary Findings**

- The prominent abdominal lymph nodes are most consistent with reactive lymphadenitis or lymphoid hyperplasia. Neoplastic infiltration is considered less likely.

**HOSPITAL NAME**

SVS Imaging CT

**INTERPRETATION OF THE FINDINGS & FURTHER RECOMMENDATIONS**

- A urine culture and sensitivity is recommended to assess for occult infection. Also consider a urine BRAF test to further evaluate for lower urinary tract neoplasia. It should be noted however, that a negative BRAF test does not completely rule out the possibility of neoplasia. A positive test confirms the diagnosis. Ultimately, an abdominal/pelvic CT scan and or cystoscopy may be necessary to get a definitive diagnosis. If a urethral obstruction is not definitively identified, reflex dyssynergia should be a consideration.

**REFERRING VET**

Madison Vet Spec  
Dr. Calhoun

**INVOICE**

12253

**DATE**

2.20.23



**PATIENT**

Irah Sokolova  
56529A

**SPECIES**

Canine

**BREED**

German Shepherd

**SEX**

Intact Female

**AGE**

6 years 8 mos

**WEIGHT**

31.2 kg

**INTERPRETED BY**

Andrea Nicastro, DVM,  
Diplomate ACVIM  
(Small Animal Internal  
Medicine)

**IMAGING PERFORMED BY**

Tom McNeill

**HOSPITAL NAME**

SVS Imaging CT

**REFERRING VET**

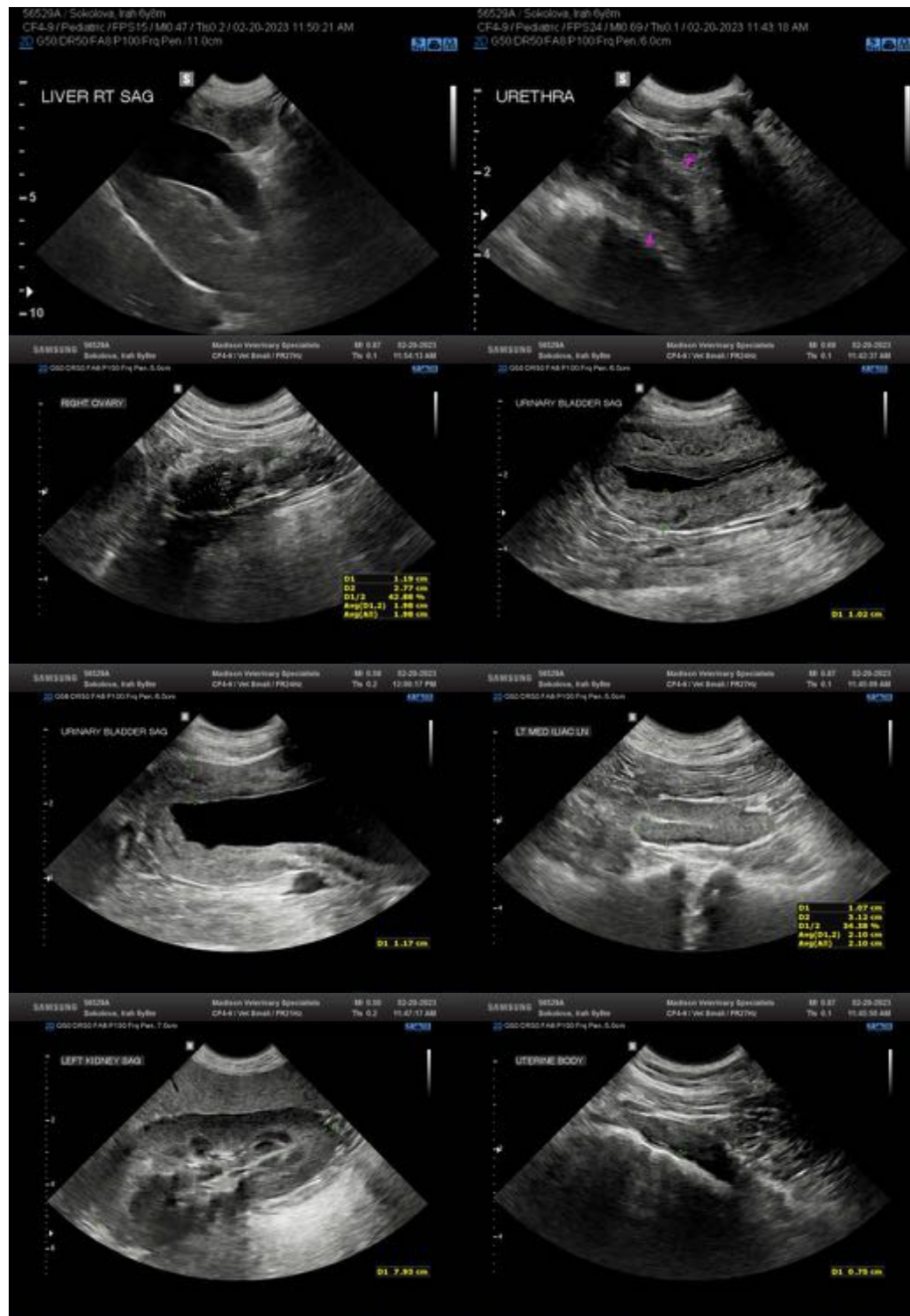
Madison Vet Spec  
Dr. Calhoun

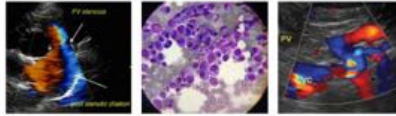
**INVOICE**

12253

**DATE**

2.20.23





**PATIENT**

Irah Sokolova  
56529A

**SPECIES**

Canine

**BREED**

German Shepherd

**SEX**

Intact Female

**AGE**

6 years 8 mos

**WEIGHT**

31.2 kg

**INTERPRETED BY**

Andrea Nicastro, DVM,  
Diplomate ACVIM  
(Small Animal Internal  
Medicine)

**IMAGING PERFORMED BY**

Tom McNeill

**HOSPITAL NAME**

SVS Imaging CT

**REFERRING VET**

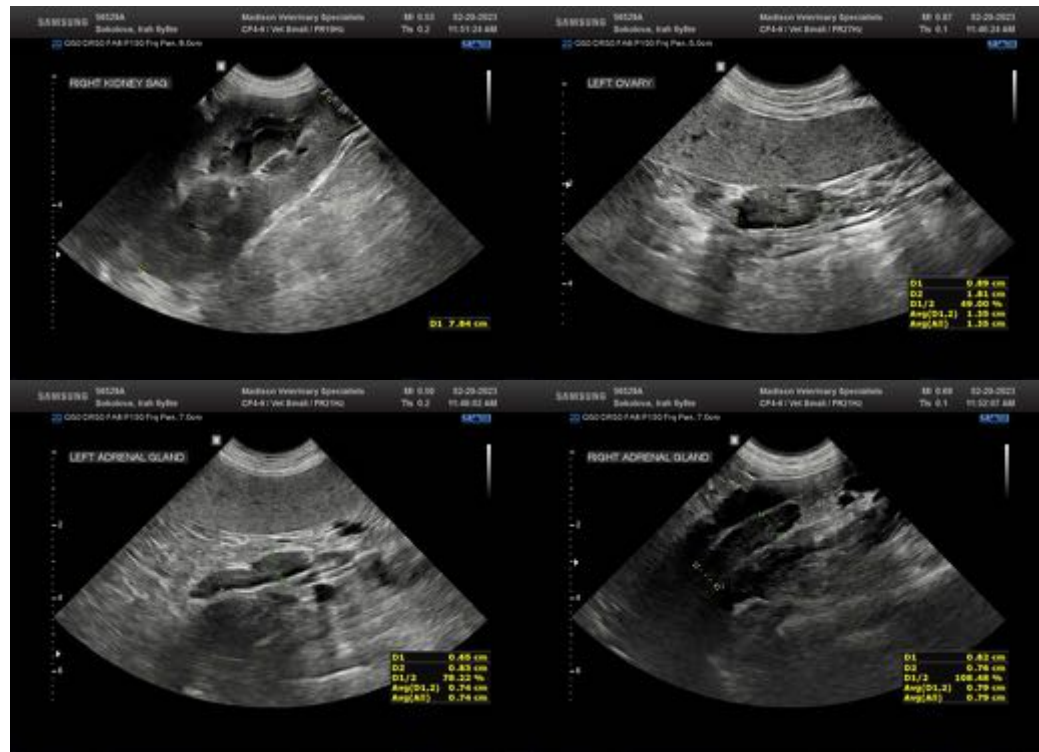
Madison Vet Spec  
Dr. Calhoun

**INVOICE**

12253

**DATE**

2.20.23



The information and recommendations provided are based on the images presented by the referring veterinarian/sonographer. No evaluation can be communicated regarding pathology that was not visible in the image/video clips provided.

Thank you for this referral. If the clinical or image interpretation does not parallel your findings or if I can be of any further assistance, please contact me.

Andrea Nicastro, MPH, DVM, Diplomate DACVIM (Small Animal Internal Medicine)  
[info@SonoPath.com](mailto:info@SonoPath.com)