



PATIENT

Maya Ward

SPECIES

Canine

BREED

Belgian Malinois

SEX

Female Spayed

AGE

7

WEIGHT

90.6 lbs

INTERPRETED BY

Andrea Nicastrò DVM
Diplomate ACVIM
(Sm Animal Internal Med)

**IMAGING
PERFORMED BY**

Andrea Nicastrò DVM
Diplomate ACVIM
(Sm Animal Internal Med)

HOSPITAL NAME

Ashley Pines AH

REFERRING VET

Dr Andrea Winney

INVOICE

22574

DATE

2-19-26

PRESENTING CLINICAL SIGNS

Patient needs a TPLO surgery. Bloodwork showed and ALP in the 1600s. Wanted to evaluate the liver and gallbladder prior to surgery. Also, borderline anemic with a hematocrit of 41%. Sedated with Dexdomitor and butorphanol for this study.

ULTRASONOGRAPHIC EXAMINATION OF THE ABDOMEN

Urinary System

The urinary bladder wall is normal in thickness. The mucosal surface is smooth. The bladder is moderately distended. Luminal contents are anechoic. No cystic calculi are observed. The region of the trigone and the proximal urethra, visible to a depth of 2 cm, are normal.

The left kidney is normal in size (7.74 cm in length) with a normal shape, architecture and smooth peripheral margins. The cortex is isoechoic relative to the spleen. There is a normal 1:3 cortex to medulla ratio with mild loss of corticomedullary distinction. There is no evidence of pyelectasia, nephroliths, infarcts or hydronephrosis. Renal vasculature is normal.

The right kidney is normal in size (7.95 cm in length) with a normal shape, architecture and smooth peripheral margins. The cortex is isoechoic relative to the spleen. There is a normal 1:3 cortex to medulla ratio with minimal-to-mild corticomedullary distinction. There is no evidence of pyelectasia, nephroliths, infarcts or hydronephrosis. Renal vasculature is normal.

Adrenal Glands

The left adrenal gland is normal in size (0.60 cm at cranial pole) (0.50 cm at caudal pole) with a normal shape and homogenous parenchyma. The glandular echogenicity and detail are unremarkable. Capsule, cortex, and medullary definition are normal. The phrenicoabdominal vein and surrounding vasculature are normal.

The right adrenal gland is normal in size (0.97 cm at cranial pole) (0.51 cm at caudal pole) with a normal shape and homogenous parenchyma. The glandular echogenicity and detail are unremarkable. Capsule, cortex, and medullary definition are normal. The phrenicoabdominal vein and surrounding vasculature are normal.

Spleen

The spleen is normal in size (1.89 cm in width at the level of the hilus) with a normal capsular contour. There is appropriate echogenicity and echotexture. No focal lesions are observed. Splenic vasculature is normal.

Liver

The liver is subjectively normal in size with normal curvilinear peripheral contours. The parenchyma is isoechoic-to slightly-hyperechoic relative to the spleen and slightly mottled in appearance. No distinct focal lesions are observed. Hepatic vasculature and intrahepatic biliary tracts are of normal volume with no evidence of congestion. The portal vein to caudal vena cava ratio is approximately 1: 1.

The gallbladder is of normal contours and contains some dependent echogenic debris. The wall is normal in thickness. No choleliths are observed. The cystic and common bile ducts are normal/not seen.

Gastrointestinal

The gastric lumen is mildly distended with ingesta. The gastric wall and pylorus are normal in thickness with a normal layering pattern. The pyloric outflow tract is patent. The small intestinal lumen is segmentally dilated with chyme. The small intestinal wall is normal in thickness with a normal layering pattern and appropriate mural detail. Discreet masses are not identified. The colonic wall is normal. There is no evidence of an obstructive pattern.



PATIENT

Maya Ward

Pancreas

The region of the pancreas is isoechoic relative to surrounding omental fat. No obvious parenchymal abnormalities are observed. There is no evidence of regional inflammation or effusion.

SPECIES

Canine

Lymph Nodes

A 1.93 x 0.71 cm medial iliac lymph node is visualized. In addition, a 1.80 x 0.65 cm mesenteric lymph node is seen.

BREED

Belgian Malinois

Free Abdomen

There is no obvious evidence of free fluid.

SEX

Female Spayed

Other

A brief echocardiogram reveals no evidence of pericardial effusion or obvious right atrial/auricular mass.

ULTRASONOGRAPHIC FINDINGS

AGE

7

Primary Findings

- The diffuse hepatic changes are non-specific and could be consistent with vacuolar hepatopathy, regenerative nodular hyperplasia, and/or age-related remodeling. Inflammatory disease, infiltrative neoplasia and other hepatopathies are considered less likely.
- Gallbladder debris, non-mucocele

WEIGHT

90.6 lbs

Secondary Findings

- Mild bilateral nonspecific age-related renal changes
- The prominent abdominal lymph nodes are most consistent with reactive lymphadenitis or lymphoid hyperplasia. Neoplastic infiltration is considered less likely.

INTERPRETED BY

Andrea Nicastrò DVM
Diplomate ACVIM
(Sm Animal Internal Med)

IMAGING PERFORMED BY

Andrea Nicastrò DVM
Diplomate ACVIM
(Sm Animal Internal Med)

INTERPRETATION OF THE FINDINGS & FURTHER RECOMMENDATIONS

- Serial monitoring (i.e., every 3-4 months) of the patient's liver values is recommended. If liver values continue to increase, a repeat abdominal ultrasound +/- hepatic tissue sampling may be warranted.
- If the patient is to undergo anesthesia, benzodiazepines should be avoided, and opioids used judiciously.

HOSPITAL NAME

Ashley Pines AH

REFERRING VET

Dr Andrea Winney

INVOICE

22574

DATE

2-19-26



PATIENT

Maya Ward

SPECIES

Canine

BREED

Belgian Malinois

SEX

Female Spayed

AGE

7

WEIGHT

90.6 lbs

INTERPRETED BY

Andrea Nicastrò DVM
 Diplomate ACVIM
 (Sm Animal Internal Med)

IMAGING PERFORMED BY

Andrea Nicastrò DVM
 Diplomate ACVIM
 (Sm Animal Internal Med)

HOSPITAL NAME

Ashley Pines AH

REFERRING VET

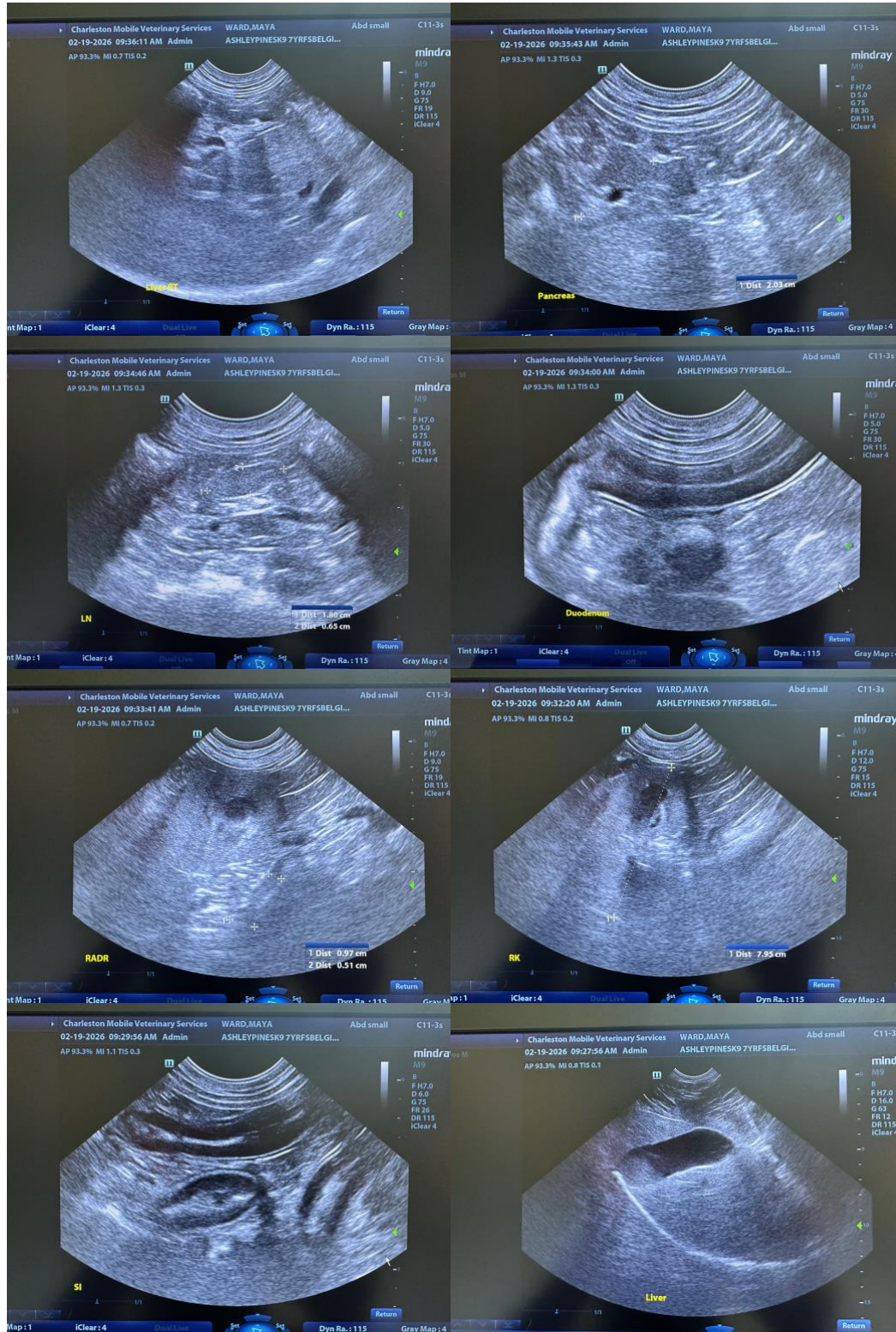
Dr Andrea Winney

INVOICE

22574

DATE

2-19-26





PATIENT

Maya Ward

SPECIES

Canine

BREED

Belgian Malinois

SEX

Female Spayed

AGE

7

WEIGHT

90.6 lbs

INTERPRETED BY

Andrea Nicaastro DVM
 Diplomate ACVIM
 (Sm Animal Internal Med)

IMAGING PERFORMED BY

Andrea Nicaastro DVM
 Diplomate ACVIM
 (Sm Animal Internal Med)

HOSPITAL NAME

Ashley Pines AH

REFERRING VET

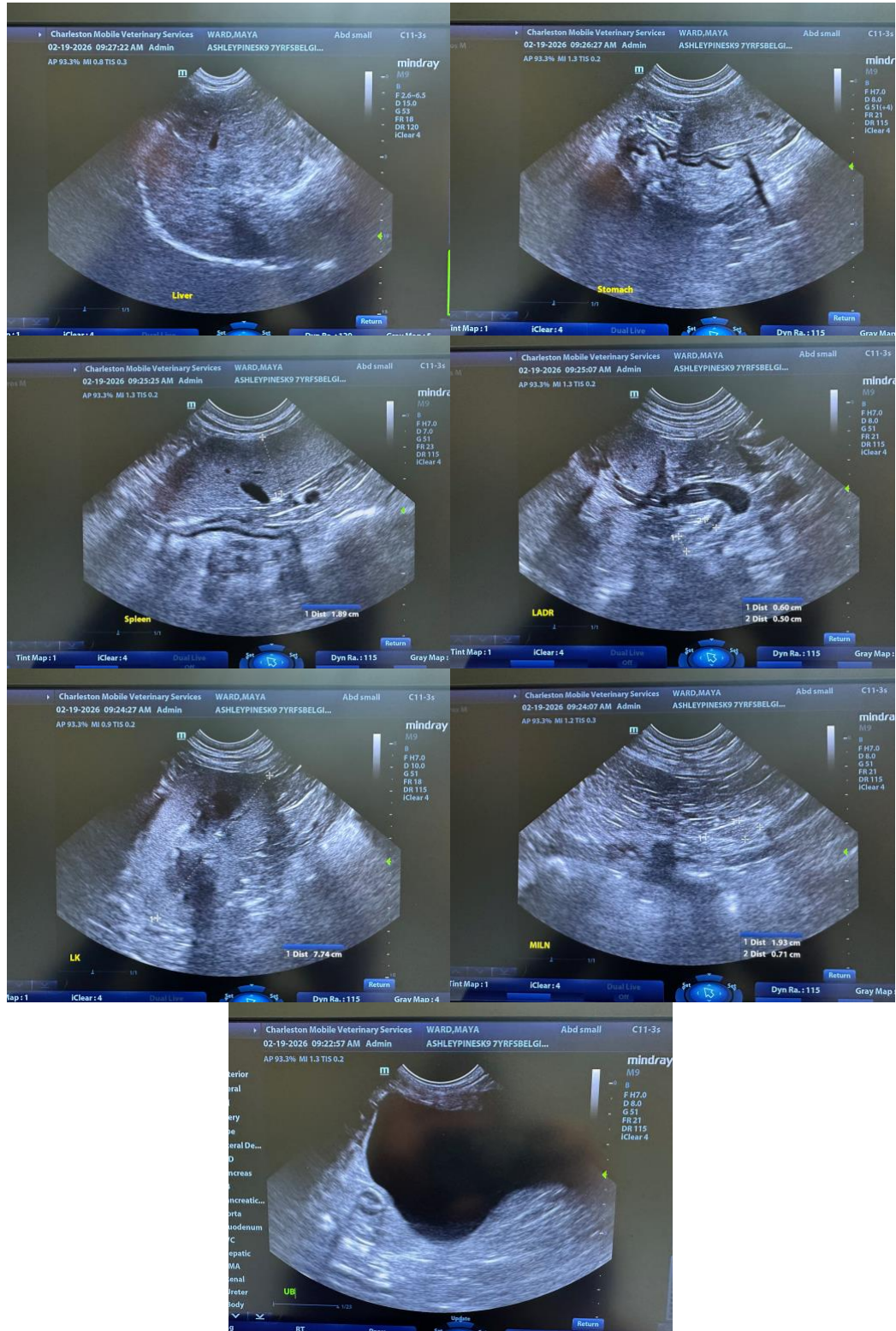
Dr Andrea Winney

INVOICE

22574

DATE

2-19-26





PATIENT

Maya Ward

The information and recommendations provided are based on the images presented by the referring veterinarian/sonographer. No evaluation can be communicated regarding pathology that was not visible in the image/video clips provided.

SPECIES

Canine

Thank you for this referral. If the clinical or image interpretation does not parallel your findings or if I can be of any further assistance, please contact me.

BREED

Belgian Malinois

Andrea Nicastro, MPH, DVM, Diplomate DACVIM (Small Animal Internal Medicine)
info@SonoPath.com

SEX

Female Spayed

AGE

7

WEIGHT

90.6 lbs

INTERPRETED BY

Andrea Nicastro DVM
Diplomate ACVIM
(Sm Animal Internal Med)

**IMAGING
PERFORMED BY**

Andrea Nicastro DVM
Diplomate ACVIM
(Sm Animal Internal Med)

HOSPITAL NAME

Ashley Pines AH

REFERRING VET

Dr Andrea Winney

INVOICE

22574

DATE

2-19-26