



PATIENT PRESENTING CLINICAL SIGNS

Heidi Scavodio
 History: 1-week-history of hyporexia and diarrhea, no vomiting
 History of mild liver enzyme elevations
 Fasted 12 hours for ultrasound

SPECIES

Canine

Abnormal PE/Chem/CBC/UA Results: Mild abdominal pain on examination and cranial organomegaly
 ALT 280 H (125), ALP 1317 H (212), Chol 360 H (320), Amyl 1630 H (1500), Lipa 2324 H (1800), PSL 693 H (200)

BREED

Chihuahua

ULTRASONOGRAPHIC EXAMINATION OF THE ABDOMEN

SEX

Female Spayed

Urinary System

The urinary bladder wall is normal in thickness. The mucosal surface is smooth. The bladder is moderately distended. Luminal contents are anechoic. No cystic calculi are observed. The region of the trigone and visible portion of the proximal urethra are normal.

AGE

13

The left kidney is normal in size (4.20 cm in length) with a normal shape. The cortex is isoechoic-to-hyperechoic relative to the spleen and mildly heterogenous in appearance, with numerous, varying-sized cortical cysts. There is poor corticomedullary distinction. Trace pyelectasia is present. Hyperechoic shadowing diverticular foci are visualized. There is no evidence of hydroureter. Renal vasculature is normal.

WEIGHT

7.4 kg

The right kidney is normal in size (5.07 cm in length) with a normal shape. The cortex is isoechoic-to-hyperechoic relative to the spleen and mildly heterogenous in appearance, with numerous, varying-sized cortical cysts. There is poor corticomedullary distinction. Trace pyelectasia is present (0.18 cm in the longitudinal plane). Hyperechoic shadowing diverticular foci are visualized. There is no evidence of hydroureter. Renal vasculature is normal.

INTERPRETED BY

Andrea Nicastro, DVM,
 Diplomate ACVIM
 (Small Animal Internal
 Medicine)

IMAGING PERFORMED BY

Camille Petrizzo

Adrenal Glands

The left adrenal gland is normal in size (0.49 cm at cranial pole) (0.43 cm at caudal pole) with a normal shape and homogenous parenchyma. The glandular echogenicity and detail are unremarkable. Capsule, cortex, and medullary definition are normal. The phrenicoabdominal vein and surrounding vasculature are normal.

The region of the right adrenal gland is evaluated. No obvious pathology is observed in this region.

Spleen

The spleen is normal in size (1.16 cm in width at the level of the hilus) with a normal capsular contour. The parenchyma is mottled, bordering on a "moth-eaten" appearance. No focal lesions are observed. Splenic vasculature is normal.

HOSPITAL NAME

Greater Staten Island
 Vet Svc

Liver

REFERRING VET

Mihira Konda

The liver is subjectively enlarged, with swollen peripheral contours. The parenchyma is isoechoic relative to the spleen and heterogenous, bordering on a nodular appearance. Ill-defined hypo- and hyperechoic nodules are seen. In addition, a 1.5 cm hyperechoic-to-heterogenous nodule is observed mid- to right-liver. Hepatic vasculature and intrahepatic biliary tracts are of normal volume with no evidence of congestion.

INVOICE

22579

DATE

2-19-26

The gallbladder lumen is moderately distended. The wall is normal in thickness. A moderate amount of aggregated, echogenic-to-mineralized, partially dependent debris/sludge is observed within the lumen, along with some adhered echogenic debris. The cystic and common bile ducts are normal. The duodenal papilla is normal-in-size (0.31 cm in width).



PATIENT *Gastrointestinal*

Heidi Scavodio

SPECIES

Canine

BREED

Chihuahua

SEX

Female Spayed

AGE

13

WEIGHT

7.4 kg

INTERPRETED BY

Andrea Nicastro, DVM,
Diplomate ACVIM
(Small Animal Internal
Medicine)

**IMAGING
PERFORMED BY**

Camille Petrizzo

HOSPITAL NAME

Greater Staten Island
Vet Svc

REFERRING VET

Mihira Konda

INVOICE

22579

DATE

2-19-26

The gastric lumen is mildly fluid-distended. The gastric wall and pylorus are normal in thickness with a normal layering pattern. The pyloric outflow tract is patent. The small intestinal lumen is not dilated. The small intestinal wall is normal in thickness with a normal layering pattern and appropriate mural detail. Discreet masses are not identified. The colonic wall is normal. There is no evidence of an obstructive pattern.

Pancreas

The left limb of the pancreas is visible with normal curvilinear peripheral contours. The parenchyma is largely isoechoic relative to surrounding omental fat and slightly mottled in appearance. The pancreatic duct is visible but not overtly dilated. There is no evidence of peripancreatic inflammation or effusion.

Lymph Nodes

The abdominal lymph nodes are normal/not visible.

Free Abdomen

There is no obvious evidence of free fluid.

ULTRASONOGRAPHIC FINDINGS

Primary Findings

- The hepatic changes are nonspecific and could be secondary to inflammatory disease (i.e., cholangiohepatitis, chronic hepatitis), Leptospirosis, hepatotoxicosis, infiltrative neoplasia (i.e., lymphoma), vacuolar hepatopathy, regenerative nodular hyperplasia, other hepatopathy, or some combination thereof. The hyperechoic-to-heterogenous nodule seen mid-liver could be consistent with a regenerative nodule, myelolipoma, inflammatory focus, emerging tumor, other.
- The gallbladder changes are suggestive of a developing mucocele.
- The splenic parenchymal changes could be consistent with emerging neoplasia (i.e., round cell tumor), lymphoid hyperplasia, extramedullary hematopoiesis, splenitis, antigenic stimulation, other).

Secondary Findings

- Bilateral nonspecific age-related renal changes with cortical cysts and pyelectasia. The pyelectasia may be secondary to parenchymal remodeling, pyelonephritis, PU/PD (if applicable), or some combination thereof.
- The pancreatic changes are most consistent with age-related parenchymal remodeling, potentially secondary to a prior inflammatory episode, early fibrosis or chronic pancreatitis.

INTERPRETATION OF THE FINDINGS & FURTHER RECOMMENDATIONS

- Consider fine-needle aspiration of the liver and spleen (assuming normal clotting status). Twenty-five gauge-needles should be used. If the cytology results are inconclusive, laparoscopic or surgical liver biopsies with aerobic and anaerobic bile cultures and hepatic copper quantitation may be necessary to get a definitive diagnosis. Other considerations include the following:
 1. Three-view thoracic radiographs to assess cardiopulmonary status
 2. Fecal evaluation for ova and Giardia
 3. GI panel including serum cobalamin and folate, TLI, PLI and resting cortisol level



PATIENT

Heidi Scavodio

SPECIES

Canine

BREED

Chihuahua

SEX

Female Spayed

AGE

13

WEIGHT

7.4 kg

INTERPRETED BY

Andrea Nicastro, DVM,
Diplomate ACVIM
(Small Animal Internal
Medicine)

IMAGING PERFORMED BY

Camille Petrizzo

HOSPITAL NAME

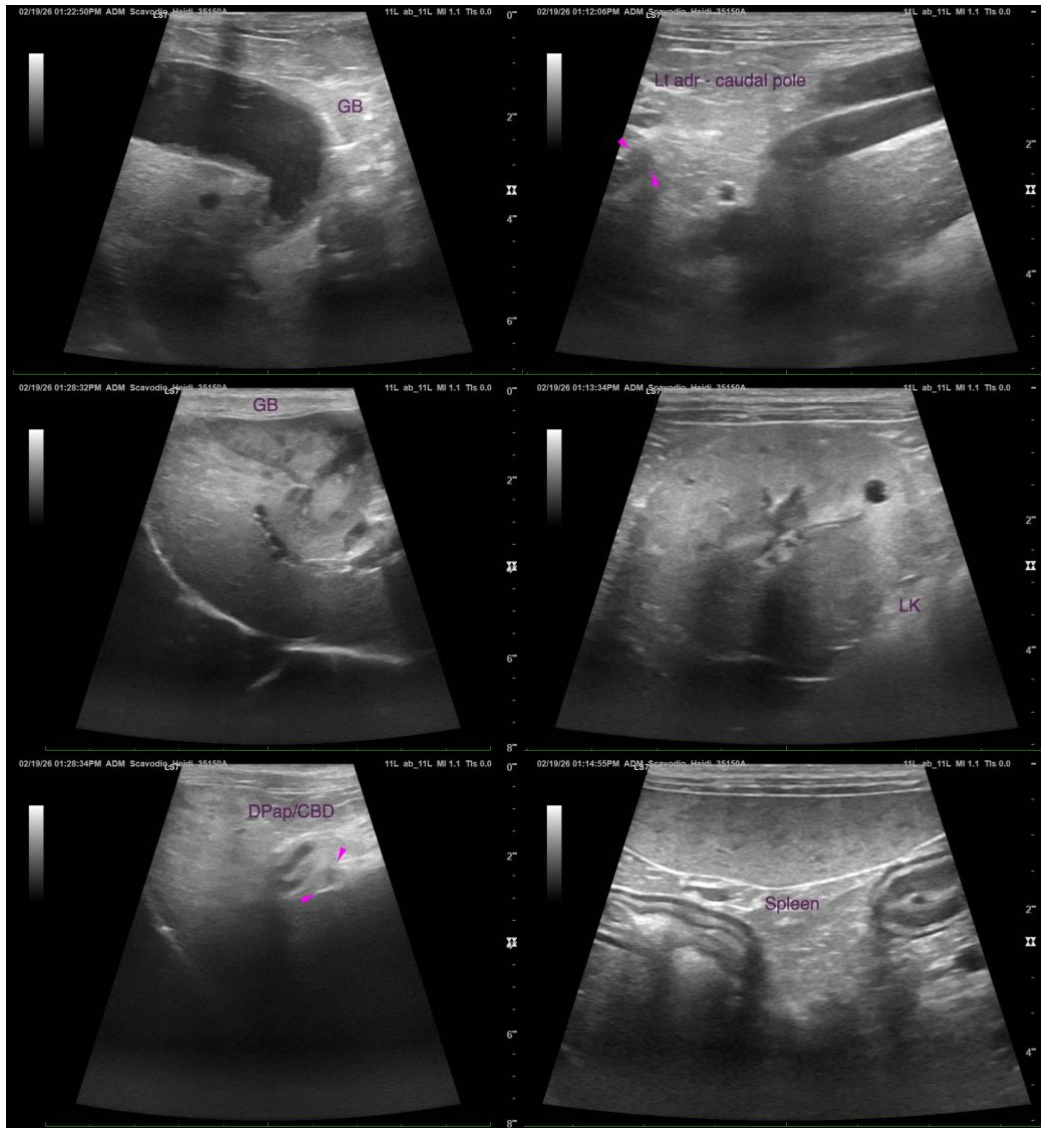
Greater Staten Island
Vet Svc

REFERRING VET

Mihira Konda

4. +/- endoscopic or surgical GI biopsies

- Given the gall bladder changes, Ursodeoxycholic acid (Ursodiol) is recommended. Serial sonographic monitoring (e.g., every 4-6 weeks) of the gall bladder is recommended to assess for progression to a fully formed mucocele. If progression occurs, a cholecystectomy may be warranted.



INVOICE

22579

DATE

2-19-26



PATIENT

Heidi Scavodio

SPECIES

Canine

BREED

Chihuahua

SEX

Female Spayed

AGE

13

WEIGHT

7.4 kg

INTERPRETED BY

Andrea Nicastro, DVM,
Diplomate ACVIM
(Small Animal Internal
Medicine)

IMAGING PERFORMED BY

Camille Petrizzo

HOSPITAL NAME

Greater Staten Island
Vet Svc

REFERRING VET

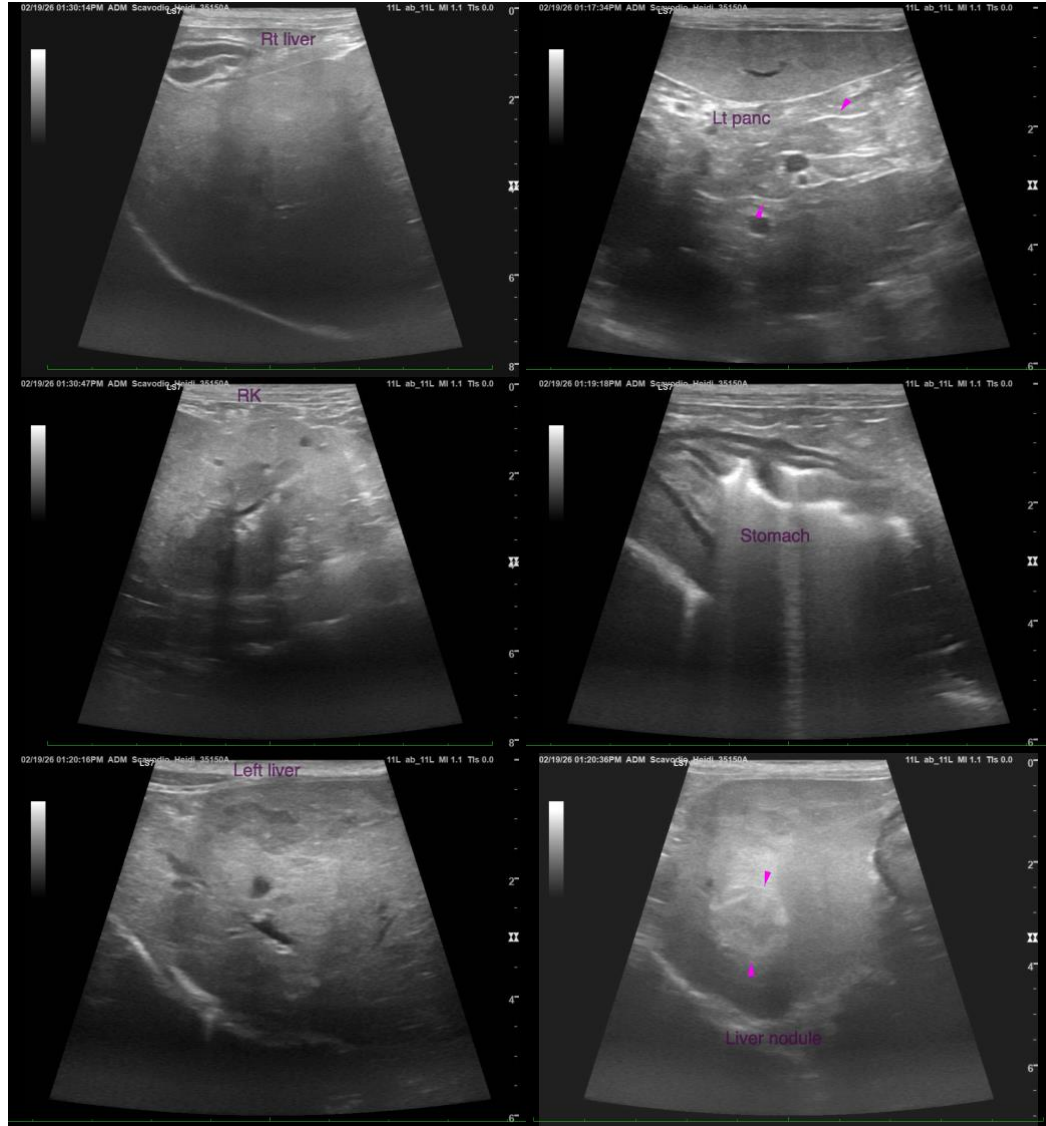
Mihira Konda

INVOICE

22579

DATE

2-19-26



The information and recommendations provided are based on the images presented by the referring veterinarian/sonographer. No evaluation can be communicated regarding pathology that was not visible in the image/video clips provided.

Thank you for this referral. If the clinical or image interpretation does not parallel your findings or if I can be of any further assistance, please contact me.

Andrea Nicastro, MPH, DVM, Diplomate DACVIM (Small Animal Internal Medicine)
info@SonoPath.com