



**PATIENT**

Biscuit Mangum

**SPECIES**

Canine

**BREED**

CKCS

**SEX**

Female Spayed

**AGE**

02/13/2024

**WEIGHT**

8.8 Kgs

**INTERPRETED BY**

Andrea Nicastrò DVM  
Diplomate ACVIM  
(Sm Animal Internal Med)

**IMAGING  
PERFORMED BY**

Andrea Nicastrò DVM  
Diplomate ACVIM  
(Sm Animal Internal Med)

**HOSPITAL NAME**

PawMED Vet  
Urgent Care

**REFERRING VET**

Dr. William Marscher

**INVOICE**

22581

**DATE**

2-19-26

**PRESENTING CLINICAL SIGNS**

Clinical Exam Findings: Developed large bowel diarrhea acutely on February 13<sup>th</sup>. Since then, has had persistent diarrhea which may be mixed small and large bowel, and also has started having episodes of vomiting. Has been on psyllium and Provable, but clinical signs are persistent. Bloodwork reveals hypokalemia. Resting cortisol is normal. Fecal PCR is negative.

**ULTRASONOGRAPHIC EXAMINATION OF THE ABDOMEN**

**Urinary System**

The urinary bladder wall is normal in thickness. The mucosal surface is smooth. The bladder is moderately distended. Luminal contents are anechoic. No cystic calculi are observed. The region of the trigone and the proximal urethra, visible to a depth of 2 cm, are normal.

The left kidney is normal in size (4.29 cm in length) with a normal shape, architecture and smooth peripheral margins. There is a normal 1:3 cortex to medulla ratio with normal corticomedullary distinction. There is no evidence of pyelectasia, nephroliths, infarcts or hydronephrosis. Renal vasculature is normal.

The right kidney is normal in size (4.06 cm in length) with a normal shape, architecture and smooth peripheral margins. There is a normal 1:3 cortex to medulla ratio with normal corticomedullary distinction. There is no evidence of pyelectasia, nephroliths, infarcts or hydronephrosis. Renal vasculature is normal.

**Adrenal Glands**

The left adrenal gland is normal in size (0.43 cm at cranial pole) (0.50 cm at caudal pole) with a normal shape and homogenous parenchyma. The glandular echogenicity and detail are unremarkable. Capsule, cortex, and medullary definition are normal. The phrenicoabdominal vein and surrounding vasculature are normal.

The right adrenal gland is normal in size (0.59 cm at cranial pole) (0.42 cm at caudal pole) with a normal shape and homogenous parenchyma. The glandular echogenicity and detail are unremarkable. Capsule, cortex, and medullary definition are normal. The phrenicoabdominal vein and surrounding vasculature are normal.

**Spleen**

The spleen is normal in size (1.00 cm in width at the level of the hilus) with a normal capsular contour. There is appropriate echogenicity and echotexture. No focal lesions are observed. Splenic vasculature is normal.

**Liver**

The liver is subjectively normal in size with normal contours and structure. There is appropriate echogenicity and echotexture. No overt structural evidence of inflammatory, infiltrative, or regenerative pathology is evident. Vascular and biliary tracts are of normal volume with no evidence of congestion. The portal vein to caudal vena cava ratio is approximately 1: 1.

The gallbladder lumen is moderately distended. The wall is thin and smooth. Luminal contents are anechoic. The cystic and common bile ducts are normal/not seen.

**Gastrointestinal**

The gastric lumen is not distended. The gastric wall and pylorus are normal in thickness with a normal layering pattern. The pyloric outflow tract is patent. The small intestinal lumen is not dilated. The small intestinal wall is normal in thickness with a normal layering pattern and appropriate mural detail. Discreet masses are not identified. The ileoceocolic junction and colonic wall are normal. There is no evidence of an obstructive pattern.



**PATIENT**

Biscuit Mangum

**Pancreas**

The region of the pancreas is isoechoic relative to surrounding omental fat. No obvious parenchymal abnormalities are observed. There is no evidence of regional inflammation or effusion.

**SPECIES**

Canine

**Lymph Nodes**

A few prominent mesenteric lymph nodes are visualized (one measuring 2.44 x 0.41 cm).

**BREED**

**Free Abdomen**

There is no obvious evidence of free fluid.

**CKCS**

**ULTRASONOGRAPHIC FINDINGS**

**SEX**

Female Spayed

The prominent abdominal lymph nodes are most consistent with reactive lymphadenitis or lymphoid hyperplasia. Neoplastic infiltration is considered less likely.

**AGE**

02/13/2024

\*An obvious cause for the patient's clinical signs is not definitively identified in this study. Considerations include a microscopic enteropathy (i.e., food allergy/intolerance, inflammatory bowel disease, infectious/parasitic disease), underlying metabolic issue, other.

**WEIGHT**

8.8 Kgs

**INTERPRETATION OF THE FINDINGS & FURTHER RECOMMENDATIONS**

- Despite the negative fecal examination consider prophylactic deworming with fenbendazole.
- A GI panel including serum cobalamin and folate, TLI and PLI is recommended.
- Also consider a 3-4-week limited antigen or hydrolyzed protein diet trial to assess for food allergies.
- Depending on the results of the above diagnostics/therapeutics, endoscopic or surgical GI biopsies may be warranted.

**INTERPRETED BY**

Andrea Nicastrò DVM  
Diplomate ACVIM  
(Sm Animal Internal Med)

**IMAGING PERFORMED BY**

Andrea Nicastrò DVM  
Diplomate ACVIM  
(Sm Animal Internal Med)

**HOSPITAL NAME**

PawMED Vet  
Urgent Care

**REFERRING VET**

Dr. William Marscher

**INVOICE**

22581

**DATE**

2-19-26



**PATIENT**

Biscuit Mangum

**SPECIES**

Canine

**BREED**

CKCS

**SEX**

Female Spayed

**AGE**

02/13/2024

**WEIGHT**

8.8 Kgs

**INTERPRETED BY**

Andrea Nicastrò DVM  
 Diplomate ACVIM  
 (Sm Animal Internal Med)

**IMAGING PERFORMED BY**

Andrea Nicastrò DVM  
 Diplomate ACVIM  
 (Sm Animal Internal Med)

**HOSPITAL NAME**

PawMED Vet  
 Urgent Care

**REFERRING VET**

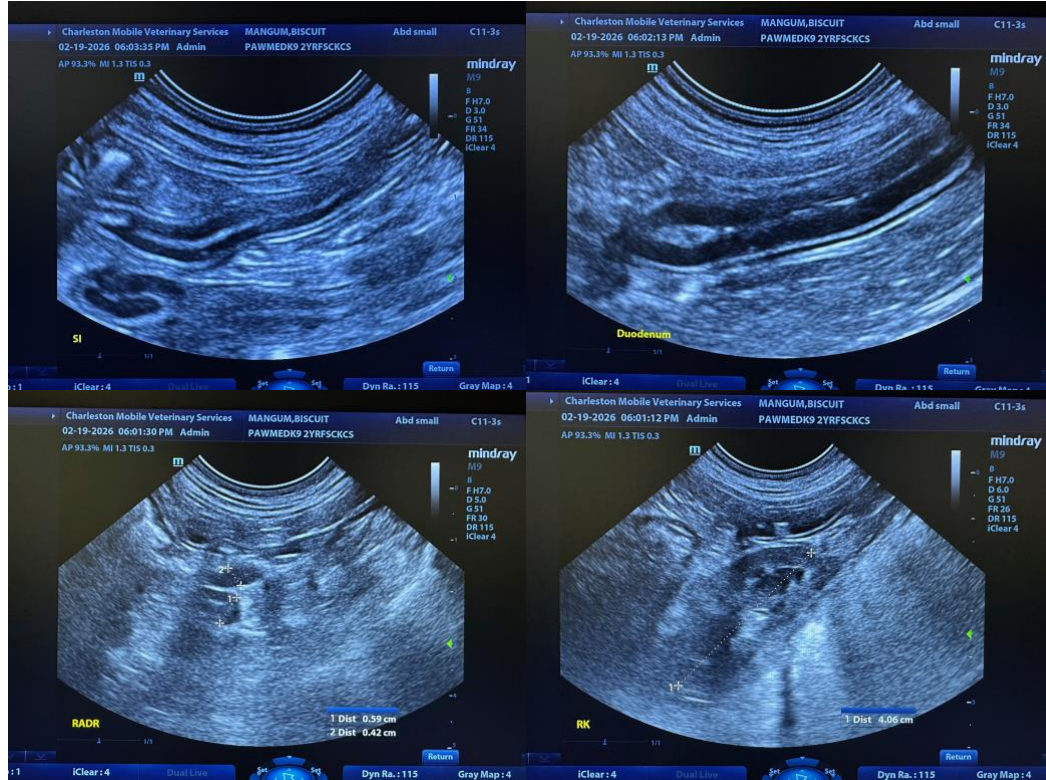
Dr. William Marscher

**INVOICE**

22581

**DATE**

2-19-26





**PATIENT**

Biscuit Mangum

**SPECIES**

Canine

**BREED**

CKCS

**SEX**

Female Spayed

**AGE**

02/13/2024

**WEIGHT**

8.8 Kgs

**INTERPRETED BY**

Andrea Nicastrò DVM  
 Diplomate ACVIM  
 (Sm Animal Internal Med)

**IMAGING PERFORMED BY**

Andrea Nicastrò DVM  
 Diplomate ACVIM  
 (Sm Animal Internal Med)

**HOSPITAL NAME**

PawMED Vet  
 Urgent Care

**REFERRING VET**

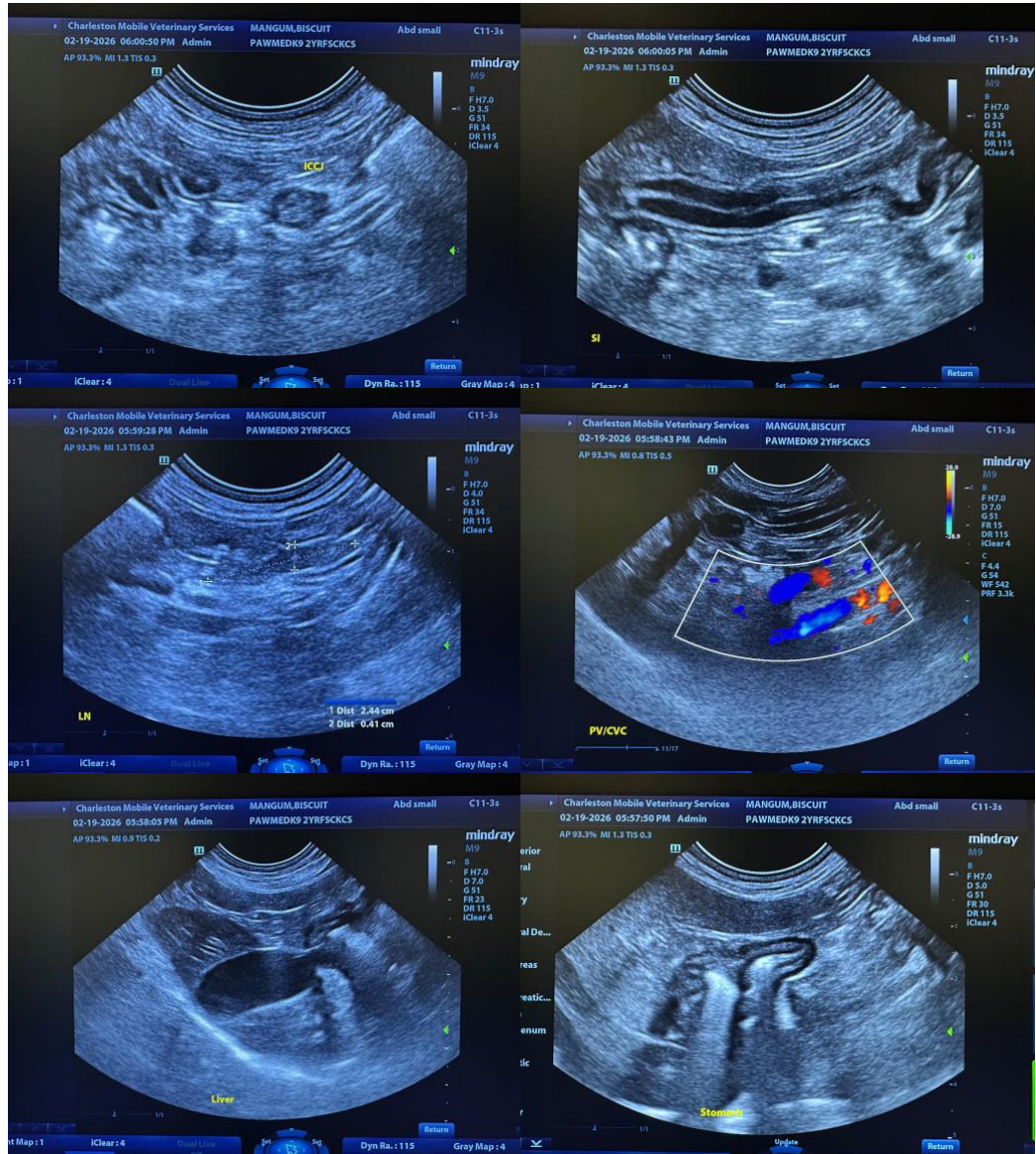
Dr. William Marscher

**INVOICE**

22581

**DATE**

2-19-26





**PATIENT**

Biscuit Mangum

**SPECIES**

Canine

**BREED**

CKCS

**SEX**

Female Spayed

**AGE**

02/13/2024

**WEIGHT**

8.8 Kgs

**INTERPRETED BY**

Andrea Nicastrò DVM  
Diplomate ACVIM  
(Sm Animal Internal Med)

**IMAGING PERFORMED BY**

Andrea Nicastrò DVM  
Diplomate ACVIM  
(Sm Animal Internal Med)

**HOSPITAL NAME**

PawMED Vet  
Urgent Care

**REFERRING VET**

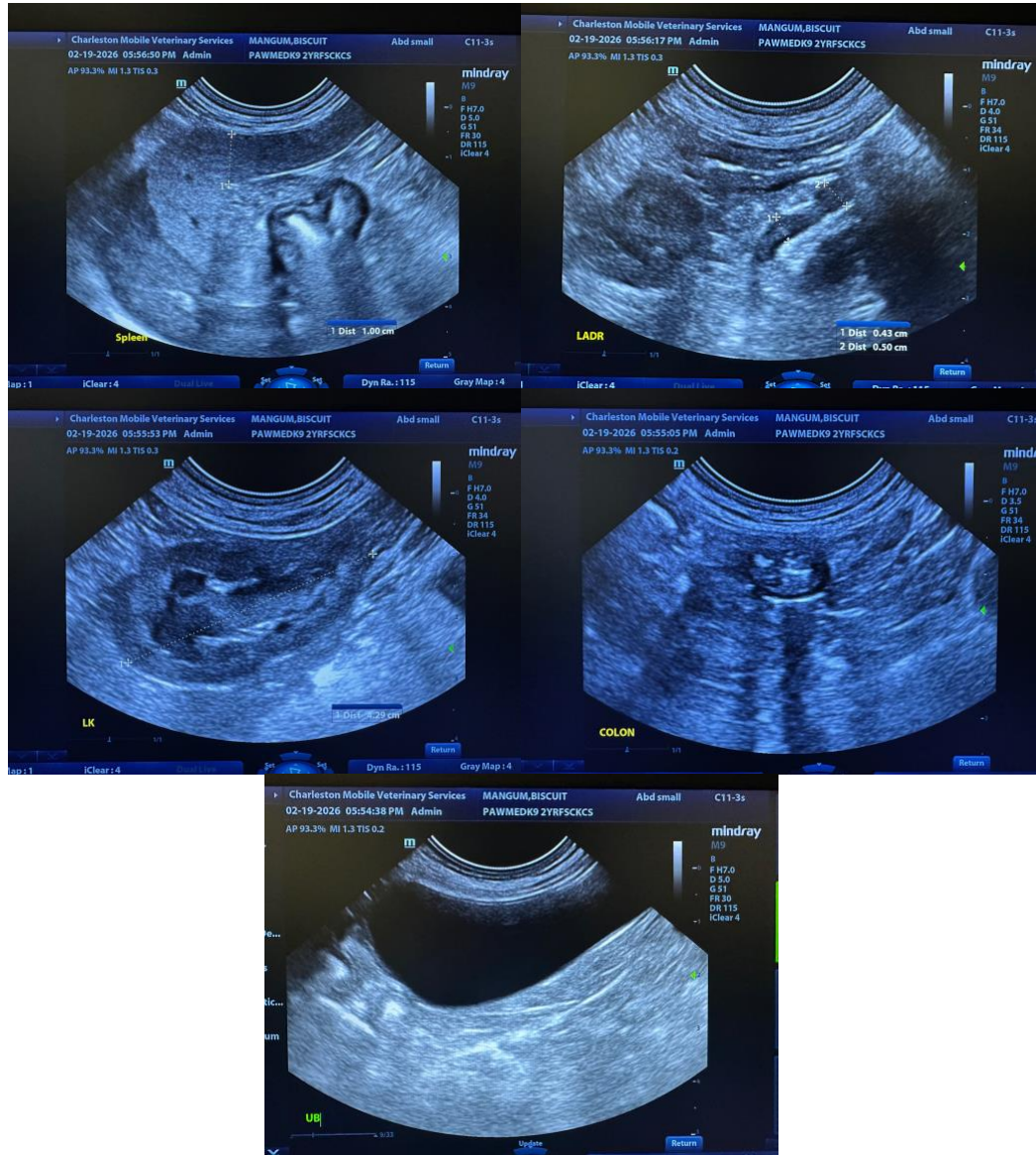
Dr. William Marscher

**INVOICE**

22581

**DATE**

2-19-26



The information and recommendations provided are based on the images presented by the referring veterinarian/sonographer. No evaluation can be communicated regarding pathology that was not visible in the image/video clips provided.

Thank you for this referral. If the clinical or image interpretation does not parallel your findings or if I can be of any further assistance, please contact me.

**Andrea Nicastrò, MPH, DVM, Diplomate DACVIM (Small Animal Internal Medicine)**  
[info@SonoPath.com](mailto:info@SonoPath.com)