

PATIENT

Djali Smith

SPECIES

Canine

BREED

GRT

SEX

Neutered Male

AGE

2019

WEIGHT

80 lbs

INTERPRETED BY

Andrea Nicastro,
 DVM, Diplomate
 ACVIM (Small Animal
 Internal Medicine)

IMAGING PERFORMED BY

RJ

HOSPITAL NAME

Alburtis AH

REFERRING VET

Dr. Smith

INVOICE

10414

DATE

2/17/22

PRESENTING CLINICAL SIGNS

History:

2/15/22 Emergency Clinic for a suspected cerebrovascular midbrain infarct. Pt had an MRI of the brain. CBC Chemistry Panel unremarkable. Spec CPL normal. T4 normal. 4dx negative. Infectious disease panel PCR negative

PRESENTING CLINICAL SIGNS

ULTRASONOGRAPHIC EXAMINATION OF THE ABDOMEN

Urinary System

The urinary bladder, trigone, and pelvic urethra are normal in thickness and the mucosal surface is smooth. The bladder lumen is moderately distended with anechoic urine. No masses, inflammatory changes or calculi are observed. Ureteral papillae and visualized portion of the proximal urethra, visible to a depth of 2 cm, are normal.

The prostate is not definitively visualized due to its pelvic location.

The left kidney presented normal size (7.46 cm in length); normal shape and architecture with smooth peripheral margins. There is a normal 1:3 cortex to medulla ratio with normal corticomedullary distinction. There is no evidence of pyelectasia, nephroliths, infarcts or hydroureter

The right kidney presented normal size (7.62 cm in length); normal shape and architecture with smooth peripheral margins. There is a normal 1:3 cortex to medulla ratio with normal corticomedullary distinction. There is no evidence of pyelectasia, nephroliths, infarcts or hydroureter.

Adrenal Glands

The left adrenal gland is normal size (0.71 cm at cranial pole) (0.70 cm at caudal pole) (2.62 cm in length); normal shape; homogenous parenchyma. The glandular echogenicity and detail are unremarkable. Capsule, cortex, and medullary definition are normal. The phrenicoabdominal vein and surrounding vasculature are normal.

The right adrenal gland is normal size (0.75 cm at cranial pole) (0.51 cm at caudal pole) (2.87 cm in length); normal shape; homogenous parenchyma. The glandular echogenicity and detail are unremarkable. Capsule, cortex, and medullary definition are normal. The phrenicoabdominal vein and surrounding vasculature are normal.

Spleen

The spleen is normal in size (1.59 cm in width at the level of the hilus) with a normal capsular contour. There is appropriate echogenicity and echotexture. No focal lesions are observed. Splenic vasculature is normal.

Liver

The liver is subjectively normal in size with normal contours and structure. There is appropriate echogenicity and echotexture. No overt structural evidence of inflammatory, infiltrative or



PATIENT

Djali Smith

regenerative pathology is evident. Vascular and biliary tracts are of normal volume with no evidence of congestion. No pathological hepatic lymphadenopathy observed.

SPECIES

Canine

The gall bladder lumen is moderately distended. The wall is thin and smooth. Luminal contents are anechoic. The cystic and common bile ducts are normal.

Gastrointestinal

BREED

GRT

The gastric lumen is moderately distended with ingesta. The gastric wall is normal in thickness with a normal layering pattern. The small intestinal lumen is segmentally dilated with gas and chyme. The small intestinal wall thickness is normal with a normal layering pattern and appropriate mural detail. Discreet masses are not identified. The colonic wall is normal. No obstructive or overt infiltrative disease is noted.

SEX

Neutered Male

Pancreas

The region of the pancreas is isoechoic relative to surrounding omental fat. No obvious parenchymal abnormalities are observed. There is no evidence of regional inflammation or effusion.

AGE

2019

Free Abdomen

The peritoneal cavity is normal. There is no evidence of inflammation or effusion. The abdominal lymph nodes are normal/not visible.

WEIGHT

80 lbs

ULTRASONOGRAPHIC FINDINGS

Primary Findings

- Unremarkable abdomen. An obvious cause for the patient's cerebrovascular brain infarct is not identified in this study.

INTERPRETED BY

Andrea Nicastro,
DVM, Diplomate
ACVIM (Small Animal
Internal Medicine)

INTERPRETATION OF THE FINDINGS & FURTHER RECOMMENDATIONS

- Consider a UPC (if proteinuria is present), as proteinuria can sometimes be associated with a hypercoagulable state.
- Also consider a baseline blood pressure measurement, if not already performed, as systemic hypertension can also result in an increased risk of cerebrovascular accidents.

IMAGING PERFORMED BY

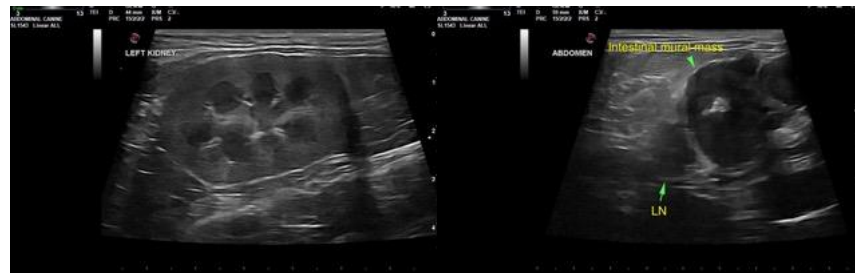RJ

HOSPITAL NAME

Alburtis AH

REFERRING VET

Dr. Smith



INVOICE

10414

DATE

2/17/22



PATIENT

Djali Smith

SPECIES

Canine

BREED

GRT

SEX

Neutered Male

AGE

2019

WEIGHT

80 lbs

INTERPRETED BY

Andrea Nicastro,
DVM, Diplomate
ACVIM (Small Animal
Internal Medicine)

**IMAGING
PERFORMED BY**

RJ

HOSPITAL NAME

Alburtis AH

REFERRING VET

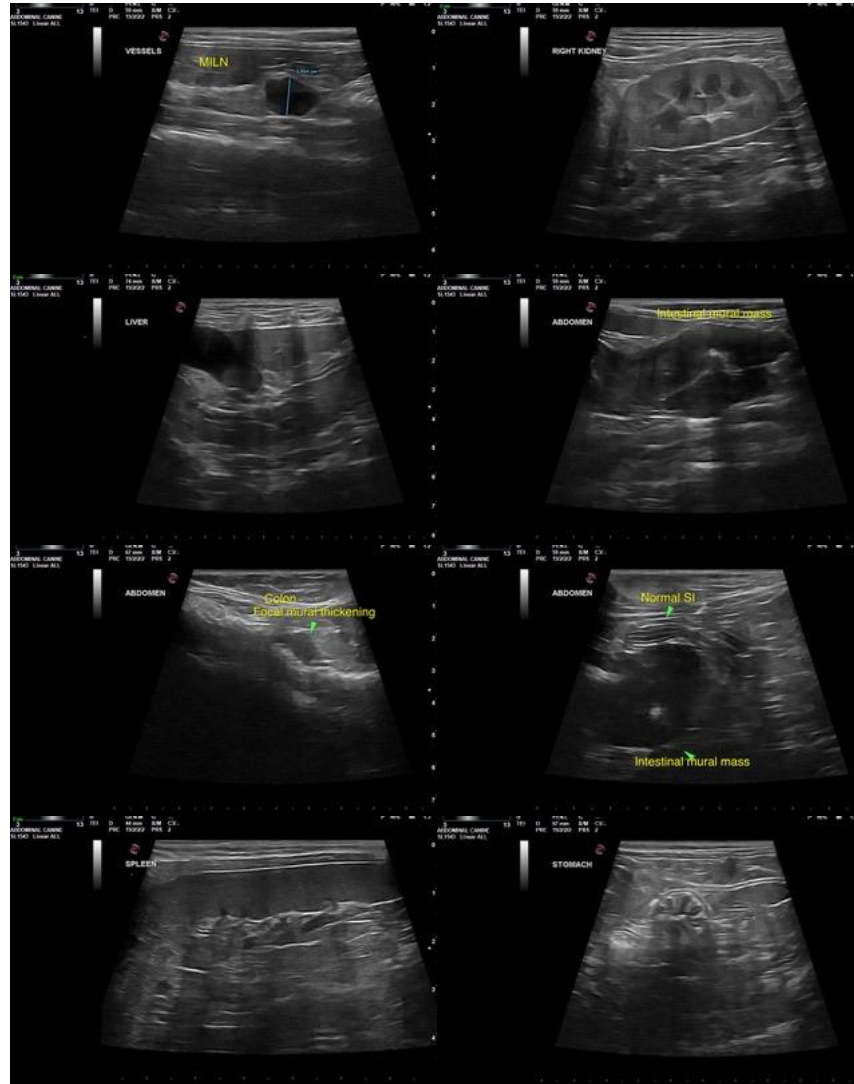
Dr. Smith

INVOICE

10414

DATE

2/17/22



The information and recommendations provided are based on the images presented by the referring veterinarian/sonographer. No evaluation can be communicated regarding pathology that was not visible in the image/video clips provided.

Thank you for this referral. If the clinical or image interpretation does not parallel your findings or if I can be of any further assistance, please contact me.

Andrea Nicastro, DVM, Diplomate DACVIM (Small Animal Internal Medicine)
info@SonoPath.com