



**PATIENT**

**PRESENTING CLINICAL SIGNS**

Byron Burns

**SPECIES**

Canine

**BREED**

Dachshund

**SEX**

Neutered Male

**AGE**

13 years

**WEIGHT**

8.62 kg

History: p presented as transfer from primary veterinarian for ultrasound. p originally presented for not eating well and acting "off". rDVM states blood clotted every time pulled, but that they think there is a cranial abdominal mass on radiographs. Bloodwork done here shows mildly increased ALP, COAG WNL, all other values WNL. Slightly low platelet count at 110,000. ALT 207 ALK foss 900. Chest and abdominal rads unremarkable.

**ULTRASONOGRAPHIC EXAMINATION OF THE ABDOMEN**

**Urinary System**

The urinary bladder, trigone, and pelvic urethra are normal in thickness and the mucosal surface is smooth. The bladder lumen is moderately distended with anechoic urine. No masses, inflammatory changes or calculi are observed. Ureteral papillae and visualized portion of the proximal urethra, visible to a depth of 2 cm, are normal.

The left kidney presented normal size (6.55 cm in length); normal shape and architecture with smooth peripheral margins. There is a normal 1:3 cortex to medulla ratio with normal corticomedullary distinction. There is no evidence of pyelectasia, nephroliths, infarcts or hydronephrosis. Renal vasculature is normal.

The right kidney presented normal size (6.41 cm in length); normal shape and architecture with smooth peripheral margins. There is a normal 1:3 cortex to medulla ratio with normal corticomedullary distinction. There is no evidence of pyelectasia, nephroliths, infarcts or hydronephrosis. Renal vasculature is normal.

**INTERPRETED BY**

**Adrenal Glands**

The left adrenal gland is normal size (0.58 cm at cranial pole) (0.58 cm at caudal pole) (2.80 cm in length); normal shape; homogenous parenchyma. The glandular echogenicity and detail are unremarkable. Capsule, cortex, and medullary definition are normal. The phrenicoabdominal vein and surrounding vasculature are normal.

The right adrenal gland is normal size (1.24 cm at cranial pole) (0.44 cm at caudal pole) (2.22 cm in length); normal shape; homogenous parenchyma. The glandular echogenicity and detail are unremarkable. Capsule, cortex, and medullary definition are normal. The phrenicoabdominal vein and surrounding vasculature are normal.

**Spleen**

The spleen is subjectively normal in size (1.83 cm in width at the level of the hilus) with slightly undulating peripheral contours. The parenchyma is subtly mottled in appearance. No focal lesions are observed. Splenic vasculature is normal.

**Liver**

The liver is enlarged with irregular peripheral contours. The parenchyma is hypoechoic relative to the spleen and diffusely nodular in appearance. A >6 cm mass effect is observed on the right side. In addition, a 1.9 cm nodule/mass is observed in the left lateral lobe. Small cavitated areas are also seen throughout the organ. Hepatic vasculature and intrahepatic biliary tracts are of normal volume with no evidence of congestion.

Andrea Nicastro,  
DVM, Diplomate  
ACVIM (Small Animal  
Internal Medicine)

**IMAGING PERFORMED BY**

Dr. Schwanebeck

**HOSPITAL NAME**

AE Hospital of  
Volusia

**REFERRING VET**

Dr. Kelly  
Schwanebeck, DVM

**INVOICE**

10398

**DATE**

2/17/22

The gall bladder is moderately distended. The wall is mildly thickened (up to 0.41 cm), with a double-walled effect. Luminal contents are mostly anechoic. The cystic and common bile ducts are



**PATIENT** normal/not seen.

Byron Burns

**SPECIES**

Canine

**BREED**

Dachshund

**SEX**

Neutered Male

**AGE**

13 years

**WEIGHT**

8.62 kg

**INTERPRETED BY**

Andrea Nicastro,  
DVM, Diplomate  
ACVIM (Small Animal  
Internal Medicine)

**IMAGING PERFORMED BY**

Dr. Schwanebeck

**HOSPITAL NAME**

AE Hospital of  
Volusia

**REFERRING VET**

Dr. Kelly  
Schwanebeck, DVM

**INVOICE**

10398

**DATE**

2/17/22

**Gastrointestinal**

The stomach and intestine are free of stasis and exhibit normal peristaltic activity. The gastric lumen is not distended. The gastric wall and pylorus are normal in thickness with a normal layering pattern. The small intestinal lumen is not dilated. The small intestinal wall thickness is normal with a normal layering pattern and appropriate mural detail. Discreet masses are not identified. The colonic wall is normal. No obstructive or overt infiltrative disease is noted.

**Pancreas**

The pancreas is somewhat obscured by the hepatic pathology. However, in the visualized portions, no obvious abnormalities are seen.

**Free Abdomen**

The mesentery in the cranial and caudal abdomen is hyperechoic. Trace free fluid is observed. The abdominal lymph nodes are normal/not visible.

**ULTRASONOGRAPHIC FINDINGS**

**Primary Findings**

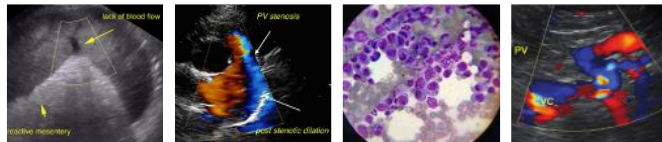
- The hepatic changes are most consistent with infiltrative neoplasia (i.e., round cell tumor, carcinoma, sarcoma) with a lower possibility of a diffuse inflammatory process. Peritonitis is present, likely secondary to hepatic pathology.
- The gall bladder changes could be consistent with cholecystitis, low oncotic pressure (if applicable), other.

**Secondary Findings**

- The splenic parenchymal changes trend toward the benign (i.e., lymphoid hyperplasia or extramedullary hematopoiesis) with a lower possibility of infiltrative neoplasia.

**INTERPRETATION OF THE FINDINGS & FURTHER RECOMMENDATIONS**

- Three-view thoracic radiographs are recommended to assess for pulmonary metastases.
- A fine-needle aspirate of the liver can be considered if clotting status is appropriate. If cytology results are inconclusive, a surgical biopsy may be necessary to get a definitive diagnosis. Due to the diffuse hepatic pathology, the prognosis for this patient is considered guarded.



**PATIENT**

Byron Burns

**SPECIES**

Canine

**BREED**

Dachshund

**SEX**

Neutered Male

**AGE**

13 years

**WEIGHT**

8.62 kg

**INTERPRETED BY**

Andrea Nicastro,  
DVM, Diplomate  
ACVIM (Small Animal  
Internal Medicine)

**IMAGING PERFORMED BY**

Dr. Schwanebeck

**HOSPITAL NAME**

AE Hospital of  
Volusia

**REFERRING VET**

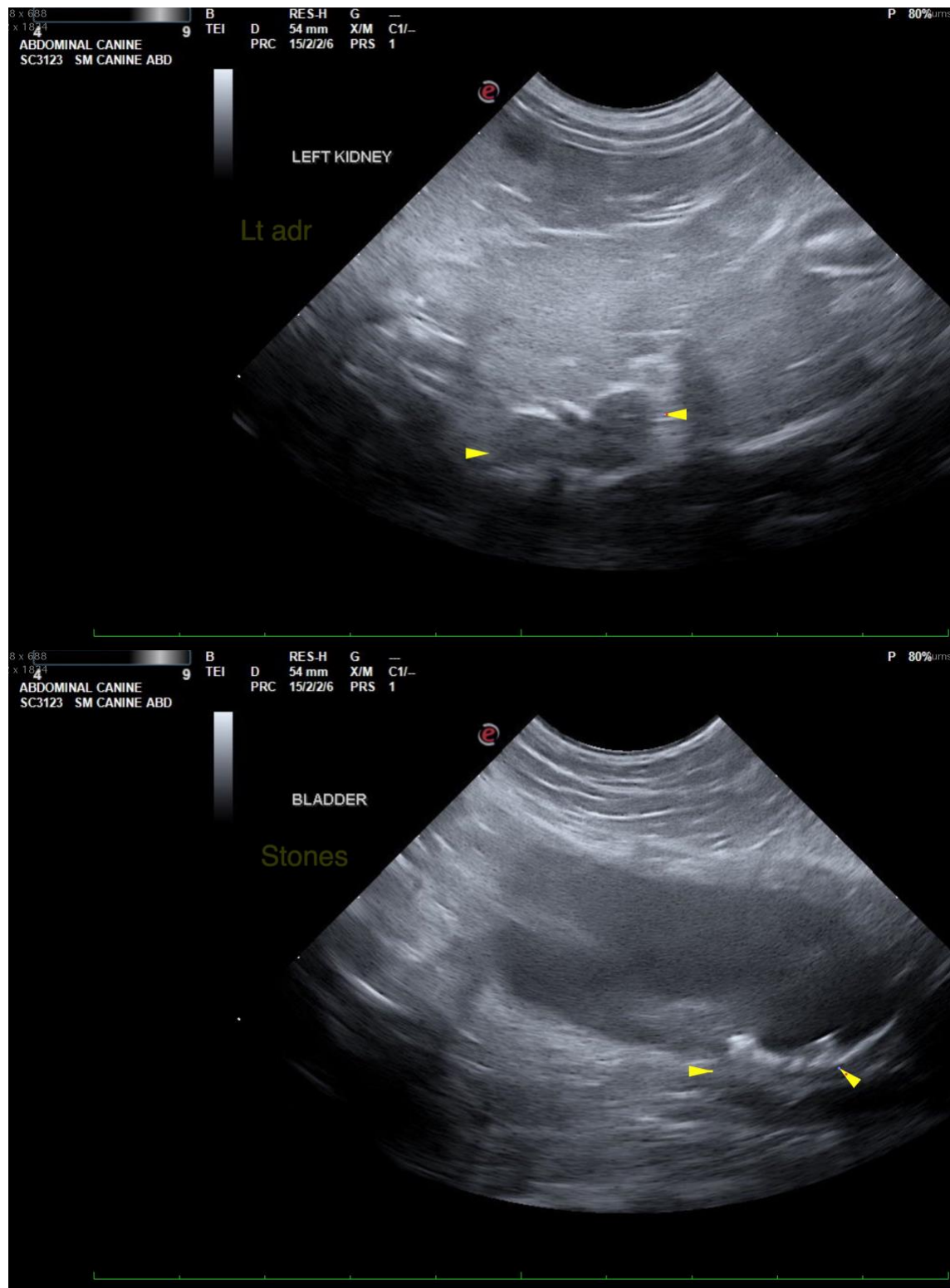
Dr. Kelly  
Schwanebeck, DVM

**INVOICE**

10398

**DATE**

2/17/22





**PATIENT**

Byron Burns

**SPECIES**

Canine

**BREED**

Dachshund

**SEX**

Neutered Male

**AGE**

13 years

**WEIGHT**

8.62 kg

**INTERPRETED BY**

Andrea Nicaastro,  
DVM, Diplomate  
ACVIM (Small Animal  
Internal Medicine)

**IMAGING PERFORMED BY**

Dr. Schwanebeck

**HOSPITAL NAME**

AE Hospital of  
Volusia

**REFERRING VET**

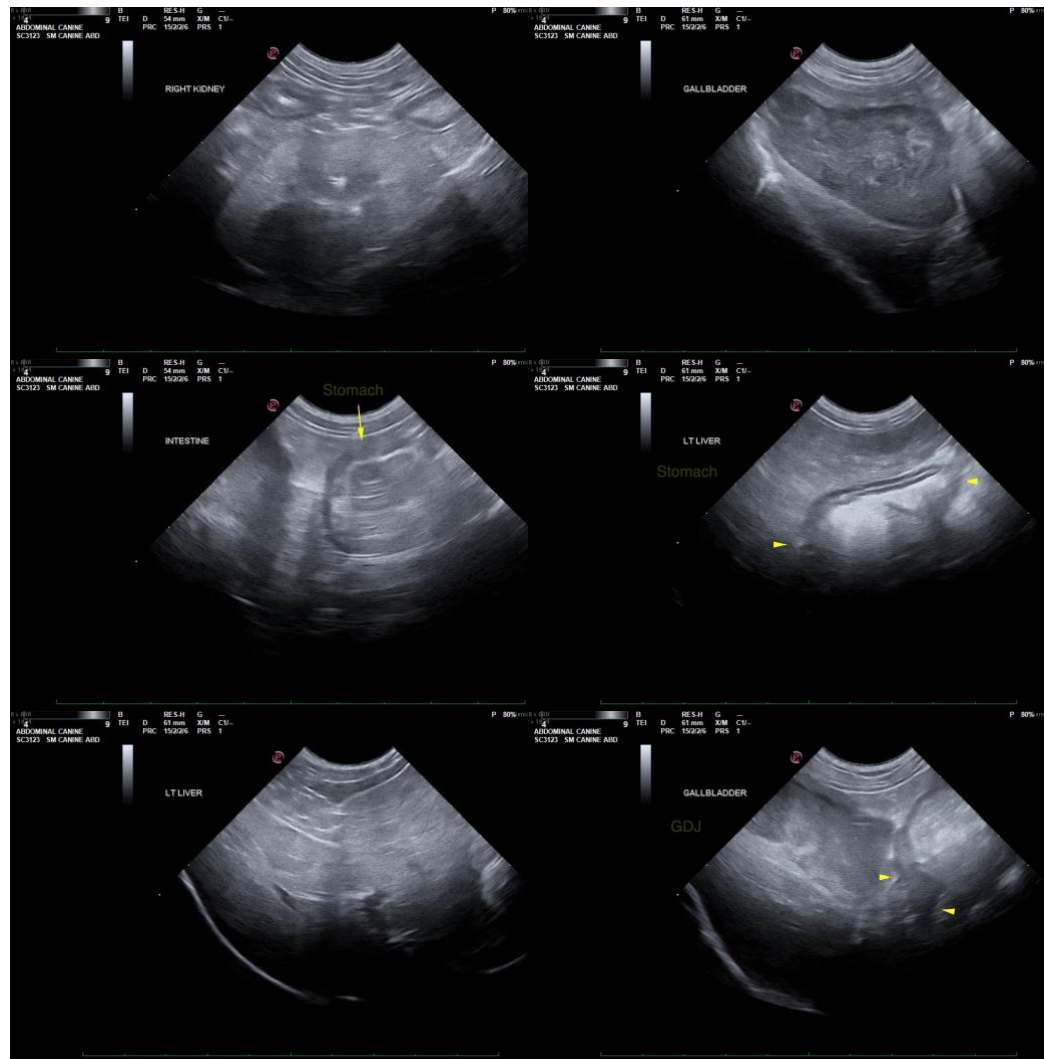
Dr. Kelly  
Schwanebeck, DVM

**INVOICE**

10398

**DATE**

2/17/22





**PATIENT**

Byron Burns

**SPECIES**

Canine

**BREED**

Dachshund

**SEX**

Neutered Male

**AGE**

13 years

**WEIGHT**

8.62 kg

**INTERPRETED BY**

Andrea Nicastro,  
DVM, Diplomate  
ACVIM (Small Animal  
Internal Medicine)

**IMAGING  
PERFORMED BY**

Dr. Schwanebeck

**HOSPITAL NAME**

AE Hospital of  
Volusia

**REFERRING VET**

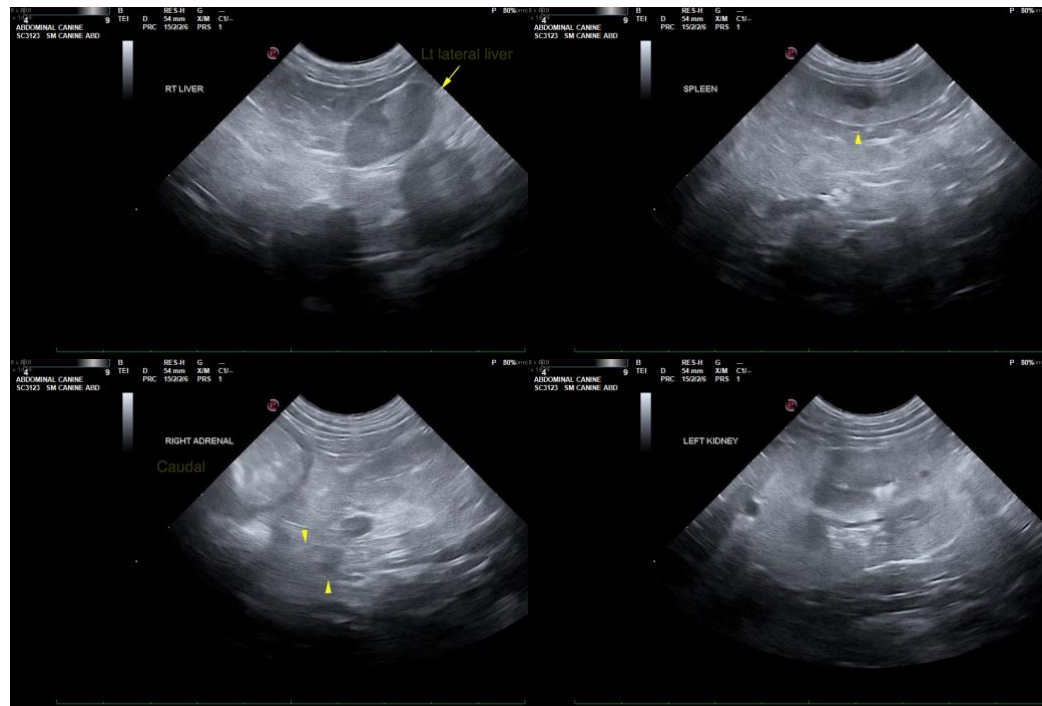
Dr. Kelly  
Schwanebeck, DVM

**INVOICE**

10398

**DATE**

2/17/22



The information and recommendations provided are based on the images presented by the referring veterinarian/sonographer. No evaluation can be communicated regarding pathology that was not visible in the image/video clips provided.

Thank you for this referral. If the clinical or image interpretation does not parallel your findings or if I can be of any further assistance, please contact me.

**Andrea Nicastro, DVM, Diplomate DACVIM (Small Animal Internal Medicine)**  
info@SonoPath.com