

**PATIENT PRESENTING CLINICAL SIGNS**

Annie Payne History: P presented for second opinion due to ongoing vomiting, diarrhea, and weight loss

**SPECIES ULTRASONOGRAPHIC EXAMINATION OF THE ABDOMEN**

**Canine Urinary System**

**BREED**

Golden Retriever

**SEX**

Female Spayed

**AGE**

11

**WEIGHT**

65.8 lbs

**INTERPRETED BY**

Andrea Nicastro, DVM,  
 Diplomate ACVIM  
 (Sm Animal Internal Med)

**IMAGING PERFORMED BY**

Kathleen Byrnes

**HOSPITAL NAME**

PCC High Country

**REFERRING VET**

Dr. Watson

**INVOICE**

22567

**DATE**

2-16-26

The urinary bladder wall is normal in thickness. The mucosal surface is smooth. The bladder is moderately distended. Luminal contents are anechoic. No cystic calculi are observed. The region of the trigone and visible portion of the proximal urethra are normal.

The left kidney is normal in size (6.64 cm in length) with a normal shape, architecture and smooth peripheral margins. There is a normal 1:3 cortex to medulla ratio with minimal-to-mild corticomedullary distinction. There is no evidence of pyelectasia, nephroliths, infarcts or hydroureter. Renal vasculature is normal.

The right kidney is normal in size (6.51 cm in length) with a normal shape, architecture and smooth peripheral margins. There is a normal 1:3 cortex to medulla ratio with minimal-to-mild corticomedullary distinction. There is no evidence of pyelectasia, nephroliths, infarcts or hydroureter. Renal vasculature is normal.

**Adrenal Glands**

The left adrenal gland is normal in size (0.41 cm at cranial pole) (0.73 cm at caudal pole) with a normal shape and homogenous parenchyma. The glandular echogenicity and detail are unremarkable. Capsule, cortex, and medullary definition are normal. The phrenicoabdominal vein and surrounding vasculature are normal.

The right adrenal gland is normal in size (1.87 cm at cranial pole) (0.57 cm at caudal pole) with a normal shape and homogenous parenchyma. The glandular echogenicity and detail are unremarkable. Capsule, cortex, and medullary definition are normal. The phrenicoabdominal vein and surrounding vasculature are normal.

**Spleen**

The spleen is normal in size (2.08 cm in width at the level of the hilus) with a normal capsular contour. There is appropriate echogenicity and echotexture. No focal lesions are observed. Splenic vasculature is normal.

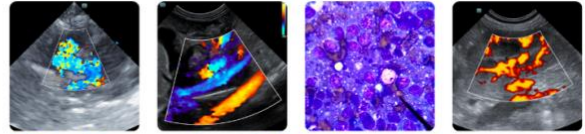
**Liver**

The liver is subjectively normal in size with normal contours and structure. There is appropriate echogenicity and echotexture. No overt structural evidence of inflammatory, infiltrative, or regenerative pathology is evident. Vascular and biliary tracts are of normal volume with no evidence of congestion.

The gallbladder lumen is moderately distended. The wall is thin and smooth. A moderate amount of gravity-dependent, echogenic-to-mineralized debris/sand is observed within the lumen. The cystic and common bile ducts are normal/not seen.

**Gastrointestinal**

The gastric lumen is severely distended with echogenic fluid, and is hypermotile. The gastric wall is normal in thickness with a normal layering pattern. The duodenal lumen is fluid-distended. An intussusception is observed in the region of the small intestine. The wall in this region is moderately thickened (up to 0.81 cm) with retention of the normal layering pattern. The mesentery effacing the serosal surface in this region is hyperechoic. Distal to the intussusception, the small intestinal segments are empty. Discreet masses are not identified. The colonic wall is normal.



**PATIENT** *Pancreas*

Annie Payne

A portion of the pancreas is obscured by the gastric distention. In the visualized portion, no obvious abnormalities are seen.

**SPECIES** *Lymph Nodes*

Canine

The abdominal lymph nodes are normal/not visible.

**BREED** *Free Abdomen*

Golden Retriever

There is no obvious evidence of free fluid.

**SEX**

Female Spayed

*Other*

A brief echocardiogram reveals no evidence of pericardial effusion or obvious right atrial/auricular mass.

**ULTRASONOGRAPHIC FINDINGS**

**AGE**

11

**Primary Findings**

Small intestinal intussusception/obstruction with mild adjacent peritonitis. The bowel wall thickening in the region of the intussusception could be consistent with inflammatory disease or less likely, emerging neoplasia.

**WEIGHT**

65.8 lbs

**Secondary Findings**

Mild bilateral nonspecific age-related renal changes

**INTERPRETED BY**

Andrea Nicastro, DVM,  
 Diplomate ACVIM  
 (Sm Animal Internal Med)

**INTERPRETATION OF THE FINDINGS & FURTHER RECOMMENDATIONS**

An abdominal exploratory is recommended to surgically correct the intussusception. Gastrointestinal biopsies should be obtained at the time of surgery to assess for microscopic disease. Three-view thoracic radiographs are recommended prior to anesthesia to assess cardiopulmonary status.

**IMAGING PERFORMED BY**

Kathleen Byrnes

**HOSPITAL NAME**

PCC High Country

**REFERRING VET**

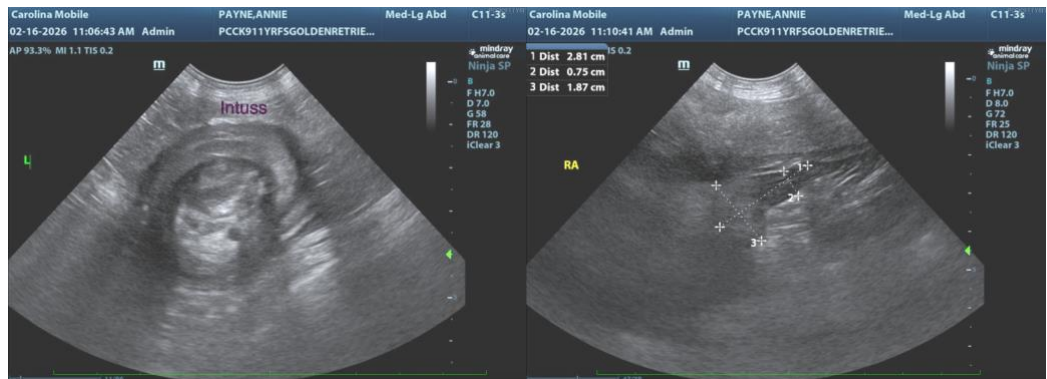Dr. Watson

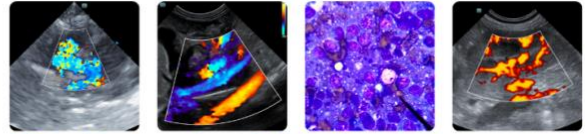
**INVOICE**

22567

**DATE**

2-16-26





**PATIENT**

Annie Payne

**SPECIES**

Canine

**BREED**

Golden Retriever

**SEX**

Female Spayed

**AGE**

11

**WEIGHT**

65.8 lbs

**INTERPRETED BY**

Andrea Nicastro, DVM,  
 Diplomate ACVIM  
 (Sm Animal Internal Med)

**IMAGING PERFORMED BY**

Kathleen Byrnes

**HOSPITAL NAME**

PCC High Country

**REFERRING VET**

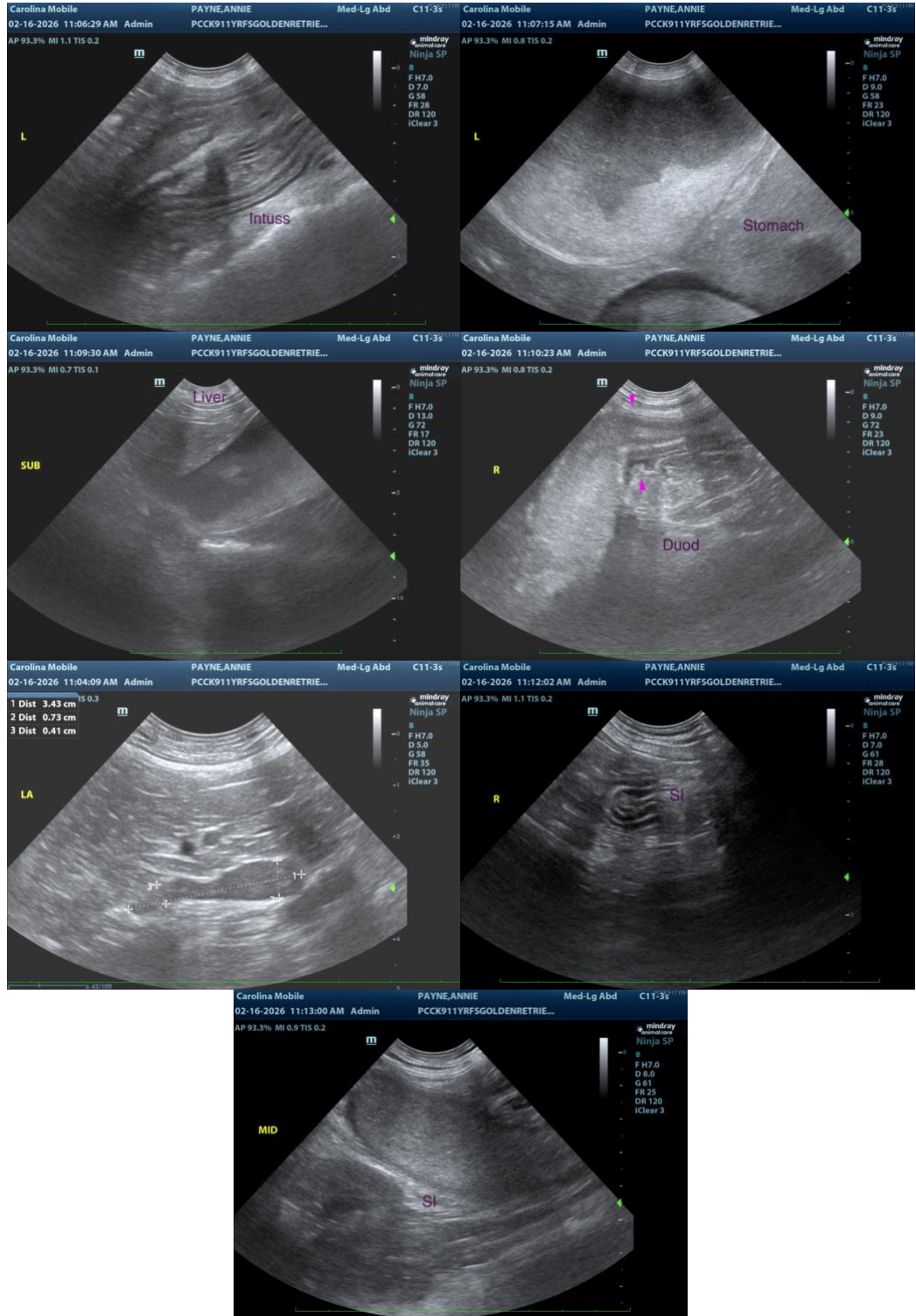
Dr. Watson

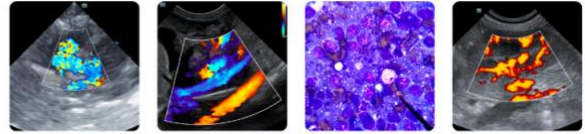
**INVOICE**

22567

**DATE**

2-16-26





**PATIENT**

Annie Payne

The information and recommendations provided are based on the images presented by the referring veterinarian/sonographer. No evaluation can be communicated regarding pathology that was not visible in the image/video clips provided.

**SPECIES**

Canine

Thank you for this referral. If the clinical or image interpretation does not parallel your findings or if I can be of any further assistance, please contact me.

**BREED**

Golden Retriever

**Andrea Nicastro, MPH, DVM, Diplomate DACVIM (Small Animal Internal Medicine)**  
[info@SonoPath.com](mailto:info@SonoPath.com)

**SEX**

Female Spayed

**AGE**

11

**WEIGHT**

65.8 lbs

**INTERPRETED BY**

Andrea Nicastro, DVM,  
Diplomate ACVIM  
(Sm Animal Internal Med)

**IMAGING  
PERFORMED BY**

Kathleen Byrnes

**HOSPITAL NAME**

PCC High Country

**REFERRING VET**

Dr. Watson

**INVOICE**

22567

**DATE**

2-16-26