

**PATIENT**Dekker Thomford
18828A**SPECIES**

Canine

BREED

German Shepherd

SEX

Neutered Male

AGE

7 years, 10 mos

WEIGHT

51.5 kg

INTERPRETED BYAndrea Nicastro, DVM,
Diplomate ACVIM
(Small Animal Internal
Medicine)**IMAGING PERFORMED BY**

Tom McNeill

HOSPITAL NAME

SVS Imaging CT

REFERRING VETMadison Veterinary
Specialists-Dr. Maller**INVOICE**

12223

DATE

2.16.23

PRESENTING CLINICAL SIGNS

History: Dekker presented to the MVS Emergency Service on Feb 15, 2023, at 11:30am, for evaluation of diarrhea, elevated liver enzymes.

Dekker developed noticeably bad diarrhea 2-3 weeks ago. Over the weekend he started having accidents in the house. This prompted owner to bring him into pcDVM yesterday where they did bloodwork. Owner was called with results today which revealed elevated liver enzymes and Dekker was referred to us. Per owner, Dekker is still eating and drinking okay. Normal urination. No vomiting, not lethargic. The only other symptom owner has noticed is malodorous flatulence. Hx of IBD treated with Prednisone. Dekker had been on Prednisone 10mg SID, which was increased to 20mg SID ~1 week ago.

Abnormal PE/Chem/CBC/UA Results:

CA 8.4
Na 151
K 5.4
TP 4.3
Alb 1.9
ALT 1677
AST 128
ALP 673
GGT 1198
T. Bili 1.2
HCT 51%
Plt 568k

ULTRASONOGRAPHIC EXAMINATION OF THE ABDOMEN**Urinary System**

The urinary bladder wall is normal in thickness and the mucosal surface is smooth. The bladder is mildly to moderately distended. A scant amount of echogenic debris is observed within the lumen. No masses, inflammatory changes or calculi are observed. Ureteral papillae and visualized portion of the proximal urethra, visible to a depth of 1-2 cm, are normal.

The prostate is normal in size (1.20 cm in width) and shape. Parenchyma is homogenous. The prostatic urethra appears normal without evidence of dilation or obstruction.

The left kidney is normal in size (8.37 cm in length) with a normal shape, architecture and smooth peripheral margins. There is a normal 1:3 cortex to medulla ratio with minimal loss of corticomedullary distinction. There is no evidence of pyelectasia, nephroliths, infarcts or hydronephrosis.

The right kidney is normal in size (9.29 cm in length) with a normal shape, architecture and smooth peripheral margins. There is a normal 1:3 cortex to medulla ratio with minimal loss of corticomedullary distinction. There is no evidence of pyelectasia, nephroliths, infarcts or hydronephrosis.

Adrenal Glands

The left adrenal gland is small in size (0.38 cm at cranial pole) (0.48 cm at caudal pole) with normal curvilinear peripheral contours. The glandular echogenicity and detail are unremarkable. Capsule, cortex, and medullary definition are normal. The phrenicoabdominal vein and surrounding vasculature are normal.

The region of the right adrenal gland is evaluated. No obvious pathology is observed.

Spleen

The spleen is subjectively normal in size with a normal capsular contour. There is appropriate

**PATIENT**

Dekker Thomford
18828A

SPECIES

Canine

BREED

German Shepherd

SEX

Neutered Male

AGE

7 years, 10 mos

WEIGHT

51.5 kg

INTERPRETED BY

Andrea Nicastro, DVM,
Diplomate ACVIM
(Small Animal Internal
Medicine)

IMAGING PERFORMED BY

Tom McNeill

HOSPITAL NAME

SVS Imaging CT

REFERRING VET

Madison Veterinary
Specialists-Dr. Maller

INVOICE

12223

DATE

2.16.23

echogenicity and echotexture. No focal lesions are observed. Splenic vasculature is normal.

Liver

The liver is normal to slightly prominent in size with normal curvilinear peripheral contours. The parenchyma is hypoechoic relative to the spleen. A 1.10 hypoechoic nodule is observed on the left side. The remaining parenchyma is homogenous in appearance. Hepatic vasculature and intrahepatic biliary tracts are of normal volume with no evidence of congestion. There is appropriate echogenicity and echotexture. No overt structural evidence of inflammatory, infiltrative, or regenerative pathology is evident. Vascular and biliary tracts are of normal volume with no evidence of congestion. No pathological hepatic lymphadenopathy observed.

The gall bladder lumen is mildly distended. The wall is thin and smooth. Luminal contents are anechoic. The cystic and common bile ducts are normal/not seen.

Gastrointestinal

The stomach and intestine are free of stasis and exhibit normal peristaltic activity. The gastric lumen is mildly distended with ingesta and gas. The gastric wall and pylorus are normal in thickness with a normal layering pattern. The pyloric outflow tract is patent. The small intestinal lumen is segmentally dilated with chyme. The small intestinal wall is normal to borderline thickened (up to 0.49 cm) with retention of the normal layering pattern. There is questionable mucosal speckling in a few segments. Discreet masses are not identified. The colonic wall is normal. There is no obvious evidence of an obstructive pattern.

Pancreas

The region of the pancreas is isoechoic relative to surrounding omental fat. No obvious parenchymal abnormalities are observed. There is no evidence of regional inflammation or effusion.

Free Abdomen

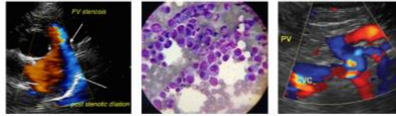
There is no obvious evidence free fluid. few prominent mesenteric lymph nodes are visualized (the largest measuring 4.52 cm in length). The nodes are normal in shape and echogenicity.

ULTRASONOGRAPHIC FINDINGS**Primary Findings**

- Given the severely elevated liver values, with a relatively normal-appearing liver sonographically, an acute hepatopathy (i.e., infectious/inflammatory toxicity) is suspected. Leptospirosis is of concern. A chronic smoldering hepatopathy (i.e., chronic hepatitis) with acute exacerbation is also possible. Infiltrative neoplasia is possible but considered less likely given the sonographic appearance of the liver. The hypoechoic hepatic nodule trends toward the benign (i.e., regenerative nodule, inflammatory focus) with a lower possibility of an emerging tumor.

Secondary Findings

- The prominent abdominal lymph nodes are most consistent with reactive lymphadenitis or lymphoid hyperplasia. Neoplastic infiltration is considered less likely.
- The significance of the intestinal mucosal speckling is unclear. It can be associated with enteritis.
- The small adrenal glands may be a normal variant for this patient or may be secondary to chronic steroid administration with subsequent adrenal atrophy.



PATIENT

Dekker Thomford
18828A

SPECIES

Canine

BREED

German Shepherd

SEX

Neutered Male

AGE

7 years, 10 mos

WEIGHT

51.5 kg

INTERPRETED BY

Andrea Nicastro, DVM,
Diplomate ACVIM
(Small Animal Internal
Medicine)

IMAGING PERFORMED BY

Tom McNeill

HOSPITAL NAME

SVS Imaging CT

REFERRING VET

Madison Veterinary
Specialists-Dr. Maller

INVOICE

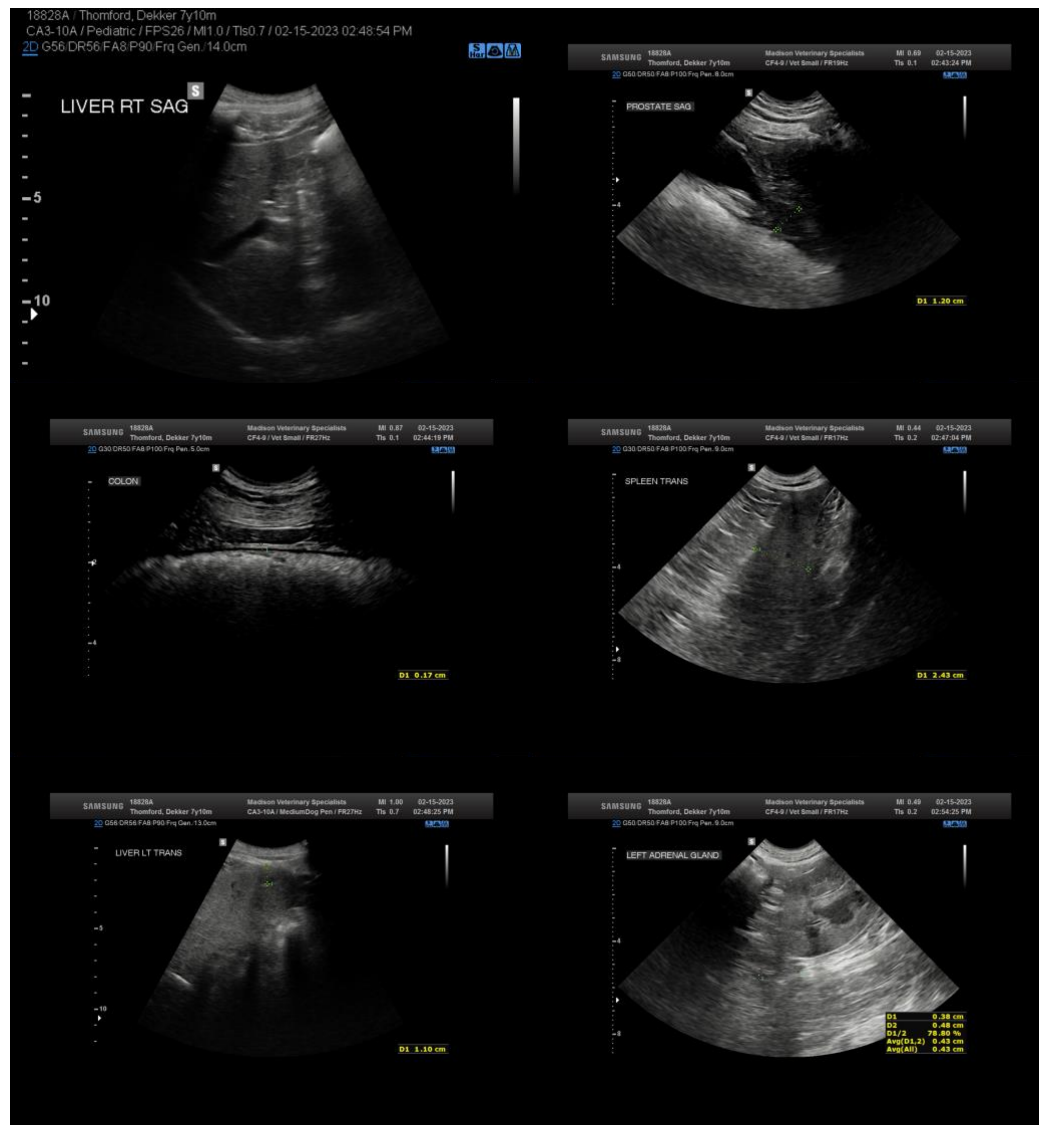
12223

DATE

2.16.23

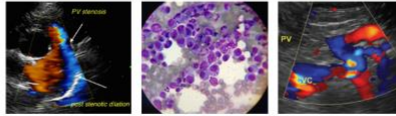
INTERPRETATION OF THE FINDINGS & FURTHER RECOMMENDATIONS

- Leptospirosis testing (i.e., blood and urine PCR; serology) is recommended.
- Hepatic tissue sampling (i.e., fine-needle aspirate or biopsies (i.e., laparoscopic or surgical)) should also be considered (if clotting status is appropriate). If biopsies are pursued, aerobic and anaerobic bile cultures should also be performed as well as hepatic copper quantitation. While awaiting test results, empirical treatment for Leptospirosis/bacterial cholangiohepatitis/hepatotoxicity is recommended (including amoxicillin-clavulanic acid, hepatic antioxidants, and symptomatic care).
- Given the diarrhea, a probiotic is recommended along with a fiber supplement and a bland diet.
- Also consider a fecal evaluation for ova and Giardia +/- prophylactic deworming with Fenbendazole.



IMAGING PERFORMED BY

svsimagingqc.net 309-737-3070



Clinical Sonography & Telectology

EDUCATIONAL TELECONSULTATION SERVICES™

1-800-838-4268 info@sonopath.com SonoPath.com

PATIENT

Dekker Thomford
18828A

SPECIES

Canine

BREED

German Shepherd

SEX

Neutered Male

AGE

7 years, 10 mos

WEIGHT

51.5 kg

INTERPRETED BY

Andrea Nicastro, DVM,
Diplomate ACVIM
(Small Animal Internal
Medicine)

IMAGING PERFORMED BY

Tom McNeill

HOSPITAL NAME

SVS Imaging CT

REFERRING VET

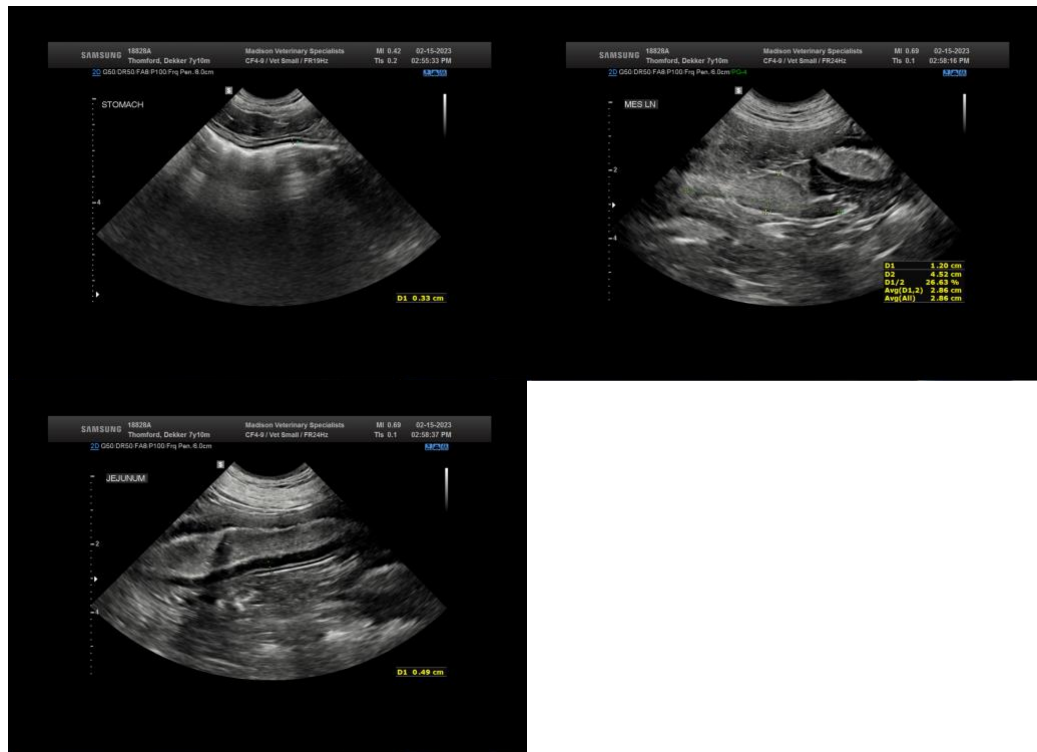
Madison Veterinary
Specialists-Dr. Maller

INVOICE

12223

DATE

2.16.23



The information and recommendations provided are based on the images presented by the referring veterinarian/sonographer. No evaluation can be communicated regarding pathology that was not visible in the image/video clips provided.

Thank you for this referral. If the clinical or image interpretation does not parallel your findings or if I can be of any further assistance, please contact me.

Andrea Nicastro, MPH, DVM, Diplomate DACVIM (Small Animal Internal Medicine)
info@SonoPath.com