



**PATIENT**

Joe Honeycutt

**PRESENTING CLINICAL SIGNS**

History: Urinary concerns; seeing pt for the first time tomorrow, pending records from Banfield.

**SPECIES**

Feline

**BREED**

DSH

**SEX**

Neutered Male

**AGE**

7 years

**WEIGHT**

20 lbs

**INTERPRETED BY**

Andrea Nicastro, DVM,  
Diplomate ACVIM (Small  
Animal Internal Medicine)

**IMAGING PERFORMED BY**

Jenna Walsh, CVT

**HOSPITAL NAME**

Countryside AC

**REFERRING VET**

Dr. Cox

**DATE**

2/16/22

**INVOICE**

10393

**ULTRASONOGRAPHIC EXAMINATION OF THE ABDOMEN**

**Urinary System**

The urinary bladder, trigone, and pelvic urethra are normal in thickness and the mucosal surface is smooth. The bladder is mildly distended. A small to moderate amount of suspended echogenic debris is observed within the lumen. No masses, inflammatory changes or calculi are observed. Ureteral papillae and visualized portion of the proximal urethra, visible to a depth of 2 cm, are normal.

The left kidney is normal size (4.52 cm in length); normal shape and architecture with smooth peripheral margins. There is a normal 1:3 cortex to medulla ratio with mild to moderate loss of corticomedullary distinction. There is no evidence of pyelectasia, nephroliths, infarcts or hydronephrosis. Renal vasculature is normal.

The right kidney is normal size (4.20 cm in length); normal shape and architecture with smooth peripheral margins. There is a normal 1:3 cortex to medulla ratio with mild to moderate loss of corticomedullary distinction. There is no evidence of pyelectasia, nephroliths, infarcts or hydronephrosis. Renal vasculature is normal.

**Adrenal Glands**

The left adrenal gland is normal size (0.63 cm length; 0.46 cm width). Normal shape and glandular echogenicity. The phrenicoabdominal vein and surrounding vasculature are normal.

The right adrenal gland is normal size (0.66 cm length; 0.36 cm width). Normal shape and glandular echogenicity. The phrenicoabdominal vein and surrounding vasculature are normal.

**Spleen**

The spleen is normal in size (1.01 cm in width at the level of the hilus) with a normal capsular contour. There is appropriate echogenicity and echotexture. No focal lesions are observed. Splenic vasculature is normal.

**Liver**

The liver is subjectively normal in size with normal contours and structure. There is appropriate echogenicity and echotexture. No overt structural evidence of inflammatory, infiltrative, or regenerative pathology is evident. Vascular and biliary tracts are of normal volume with no evidence of congestion. No pathological hepatic lymphadenopathy observed.

The gall bladder lumen is moderately distended. The wall is thin and smooth. Luminal contents are anechoic. The cystic and common bile ducts are normal.

**Gastrointestinal**

The stomach and intestine are free of stasis and exhibit normal peristaltic activity. The gastric lumen is not distended. The gastric wall and pylorus are normal in thickness with a normal layering pattern. The pyloric outflow tract is patent. The small intestinal lumen is not dilated. The small



**PATIENT**

Joe Honeycutt

**SPECIES**

Feline

**BREED**

DSH

**SEX**

Neutered Male

**AGE**

7 years

**WEIGHT**

20 lbs

**INTERPRETED BY**

Andrea Nicastro, DVM,  
Diplomate ACVIM (Small  
Animal Internal Medicine)

**IMAGING PERFORMED BY**

Jenna Walsh, CVT

**HOSPITAL NAME**

Countryside AC

**REFERRING VET**

Dr. Cox

**DATE**

2/16/22

**INVOICE**

10393

intestinal wall thickness is normal with a normal layering pattern and appropriate mural detail. Discreet masses are not identified. The colonic wall is normal. No obstructive disease is noted.

**Pancreas**

The base and limbs of the pancreas are visible with normal curvilinear peripheral contours. The parenchyma is largely isoechoic relative to surrounding omental fat and slightly mottled in appearance. The pancreatic duct is visible but not overtly dilated. There is no evidence of peripancreatic inflammation or effusion.

**Free Abdomen**

The peritoneal cavity is normal. There is no evidence of inflammation or effusion. The abdominal lymph nodes are normal/not visible. A 1.49 cm slightly irregular medial ileal lymph node is visualized.

**ULTRASONOGRAPHIC FINDINGS**

**Primary Findings**

- The urinary bladder debris could be consistent with cells, crystals and/or exfoliated material.
- Bilateral non-specific chronic renal changes

**Secondary Findings**

- The pancreatic changes are most consistent with age-related parenchymal remodeling, potentially secondary to a prior inflammatory episode, early fibrosis or chronic pancreatitis.
- The prominent medial iliac lymph node is likely reactive.

**INTERPRETATION OF THE FINDINGS & FURTHER RECOMMENDATIONS**

- Baseline lab work, including a CBC, chemistry panel, urinalysis and T4 is recommended, if not already performed.
- Urine culture and sensitivity
- Further recommended should be based the above diagnostics and on whether the patient is having upper or lower urinary tract signs



**PATIENT**

Joe Honeycutt

**SPECIES**

Feline

**BREED**

DSH

**SEX**

Neutered Male

**AGE**

7 years

**WEIGHT**

20 lbs

**INTERPRETED BY**

Andrea Nicastro, DVM,  
Diplomate ACVIM (Small  
Animal Internal Medicine)

**IMAGING PERFORMED BY**

Jenna Walsh, CVT

**HOSPITAL NAME**

Countryside AC

**REFERRING VET**

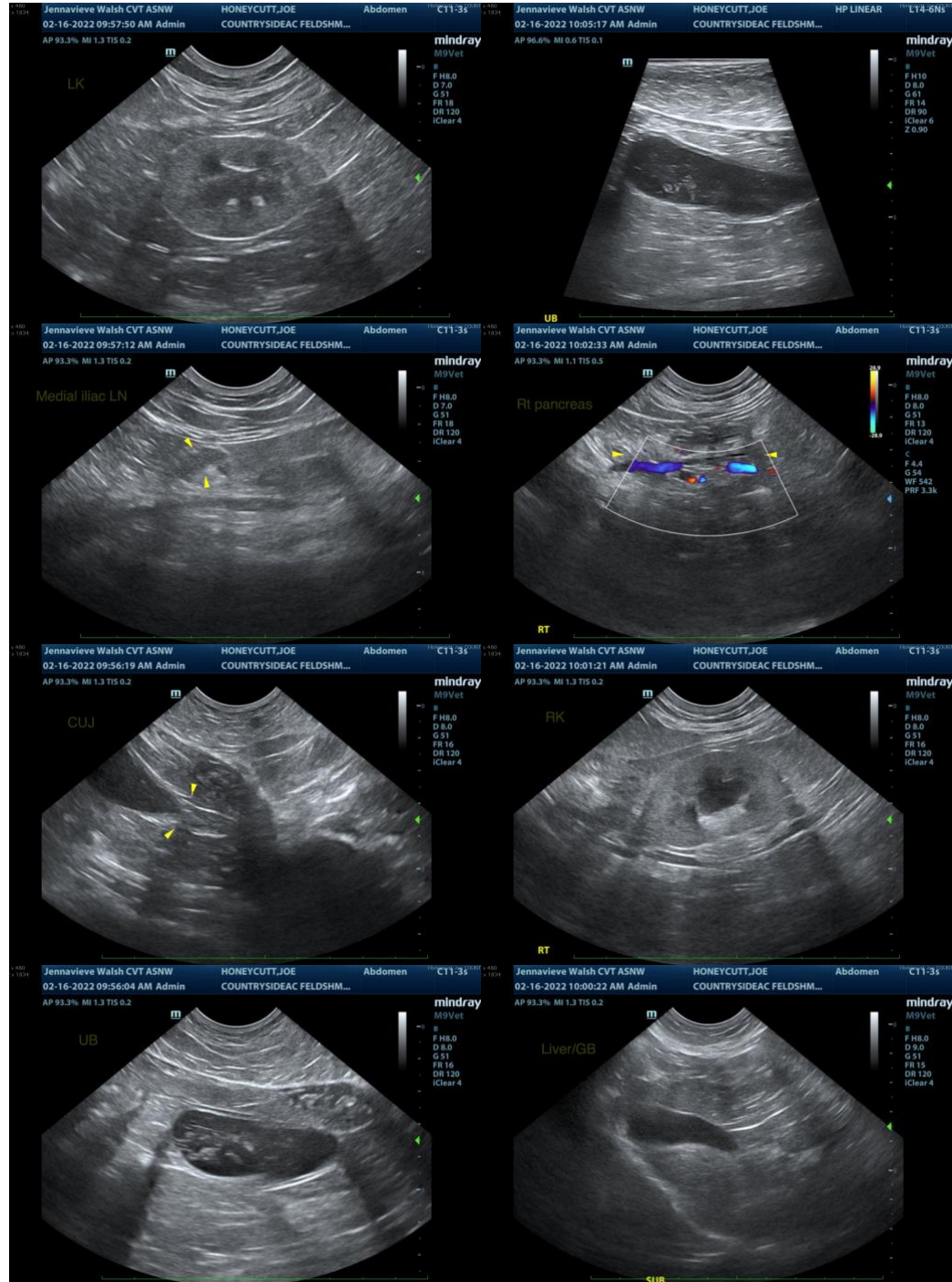
Dr. Cox

**DATE**

2/16/22

**INVOICE**

10393





**PATIENT**

Joe Honeycutt

**SPECIES**

Feline

**BREED**

DSH

**SEX**

Neutered Male

**AGE**

7 years

**WEIGHT**

20 lbs

**INTERPRETED BY**

Andrea Nicastro, DVM,  
Diplomate ACVIM (Small  
Animal Internal Medicine)

**IMAGING PERFORMED BY**

Jenna Walsh, CVT

**HOSPITAL NAME**

Countryside AC

**REFERRING VET**

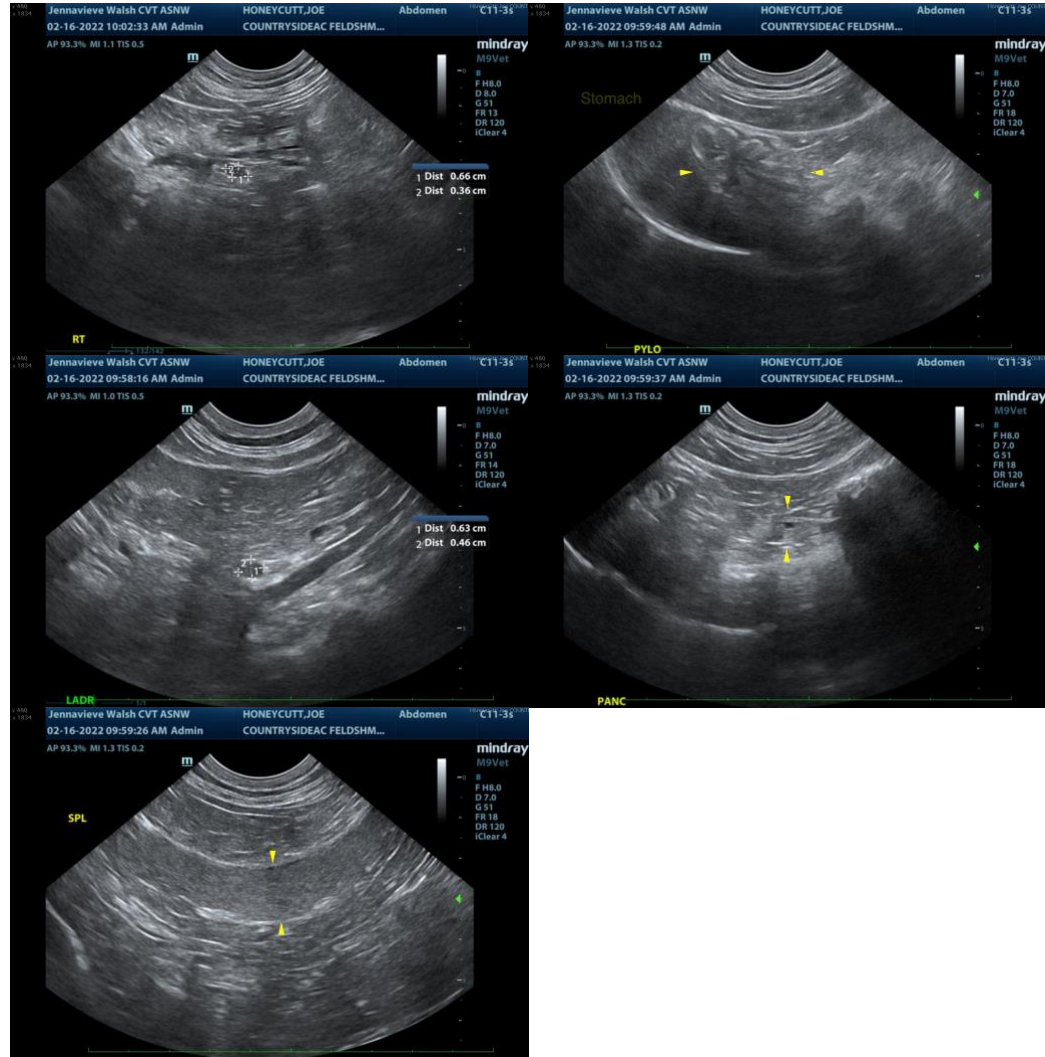
Dr. Cox

**DATE**

2/16/22

**INVOICE**

10393



The information and recommendations provided are based on the images presented by the referring veterinarian/sonographer. No evaluation can be communicated regarding pathology that was not visible in the image/video clips provided.

Thank you for this referral. If the clinical or image interpretation does not parallel your findings or if I can be of any further assistance, please contact me.

Andrea Nicastro, DVM, Diplomate ACVIM (Small Animal Internal Medicine)  
andrea\_nicastro2@hotmail.com