

**DATE PRESENTING CLINICAL SIGNS**

2/16/22

PATIENT

Gracie Norman

SPECIES

Canine

BREED

Mix

SEX

Spayed Female

AGE

6/15/13

WEIGHT

46.6 Lbs.

INTERPRETED BY

Andrea Nicastro, DMV,
 Diplomate DACVIM
 (Small Animal
 Internal Medicine)

HOSPITAL NAME

Northwind AH

REFERRING VET

Dr. Jones

INVOICE

13959

History: p has history (4 years) of intermittent blood in urine and recurrent UTI. No bacteria on UA, USG 1022, bloodwork wnl. Concerned about possible mass in bladder or urethra, etc. Additional History: Creat 1.7, BUN 17, SDMA 11, Normal T4

Current Medications: Carprofen 35mg bid
 Lab Results: Attached separately. BW wnl, UA wnl sh 1022
 Radiographs: no stones on eval, wnl abd.
 Date of Previous IntraPet Ultrasound: No previous IntraPet scans.
 Sedation: Not required to complete full diagnostic ultrasound.
 Stat Report: Not requested.

Imaging Performed By: Andi Parkinson, RDMS.

ULTRASONOGRAPHIC EXAMINATION OF THE ABDOMEN**Urinary System**

The urinary bladder is moderately distended. The wall in the ventral apical region is mildly thickened (up to 0.29 cm). The mucosal surface is smooth. A large amount of aggregated echogenic to mineralized debris is suspended within the lumen. In addition, a small to moderate amount of gravity dependent mineralized sand is observed. The debris obscures portions of the bladder wall, making it difficult to evaluate in its entirety. The region of the trigone and the visible portion of the proximal urethra appear normal.

The left kidney presented normal size (5.68 cm in length); normal shape and architecture with smooth peripheral margins. There is a normal 1:3 cortex to medulla ratio with normal corticomedullary distinction. There is no evidence of pyelectasia, nephroliths, infarcts or hydronephrosis.

The right kidney presented normal size (5.79 cm in length); normal shape and architecture with smooth peripheral margins. There is a normal 1:3 cortex to medulla ratio with normal corticomedullary distinction. There is no evidence of pyelectasia, nephroliths, infarcts or hydronephrosis.

Adrenal Glands

The left adrenal gland is normal size (0.50 cm at cranial pole) (0.58 cm at caudal pole) (2.12 cm in length); normal shape; homogenous parenchyma. The glandular echogenicity and detail are unremarkable. Capsule, cortex, and medullary definition are normal. The phrenicoabdominal vein and surrounding vasculature are normal.

The right adrenal gland is normal size (0.63 cm at cranial pole) (xxx cm at caudal pole) (xxx cm in length); normal shape; homogenous parenchyma. The glandular echogenicity and detail are unremarkable. Capsule, cortex, and medullary definition are normal. The phrenicoabdominal vein and surrounding vasculature are normal.

Spleen

The spleen is normal in size (1.70 cm in width at the level of the hilus) with a normal capsular contour. There is appropriate echogenicity and echotexture. No focal lesions are observed. Splenic vasculature is normal.

Liver

The liver is subjectively normal in size with normal contours and structure. There is appropriate echogenicity and echotexture. No overt structural evidence of inflammatory, infiltrative or regenerative pathology is evident. Vascular and biliary tracts are of normal volume with no evidence of congestion. No pathological hepatic lymphadenopathy observed.

The gall bladder lumen is moderately distended. The wall is thin and smooth. Luminal contents are anechoic. The cystic and common bile ducts are normal.

Gastrointestinal

The stomach and intestine are free of stasis and exhibit normal peristaltic activity. The gastric lumen is not distended. The gastric wall and pylorus are normal in thickness with a normal layering pattern. The small intestinal lumen is not dilated. The small intestinal wall thickness is normal with a normal layering pattern and appropriate mural detail. Discreet masses are not identified. The colonic wall is normal. No obstructive or overt infiltrative disease is noted.

Pancreas

The region of the pancreas is isoechoic relative to surrounding omental fat. No obvious parenchymal abnormalities are observed. There is no evidence of regional inflammation or effusion.

Free Abdomen

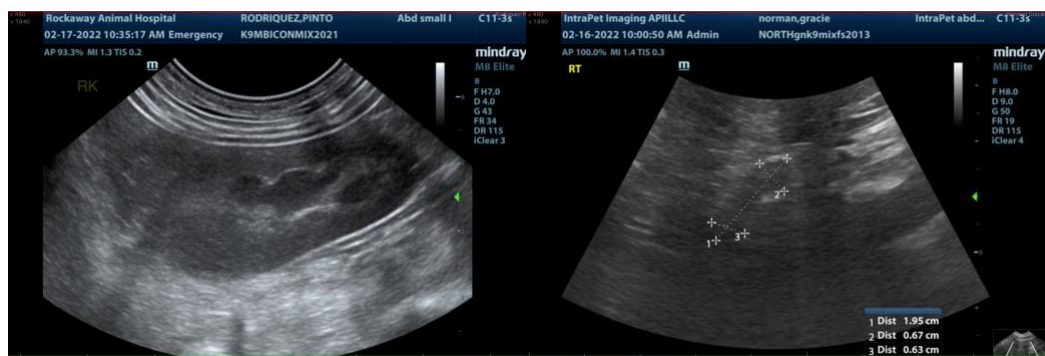
The peritoneal cavity is normal. There is no evidence of inflammation or effusion. The abdominal lymph nodes are normal/not visible.

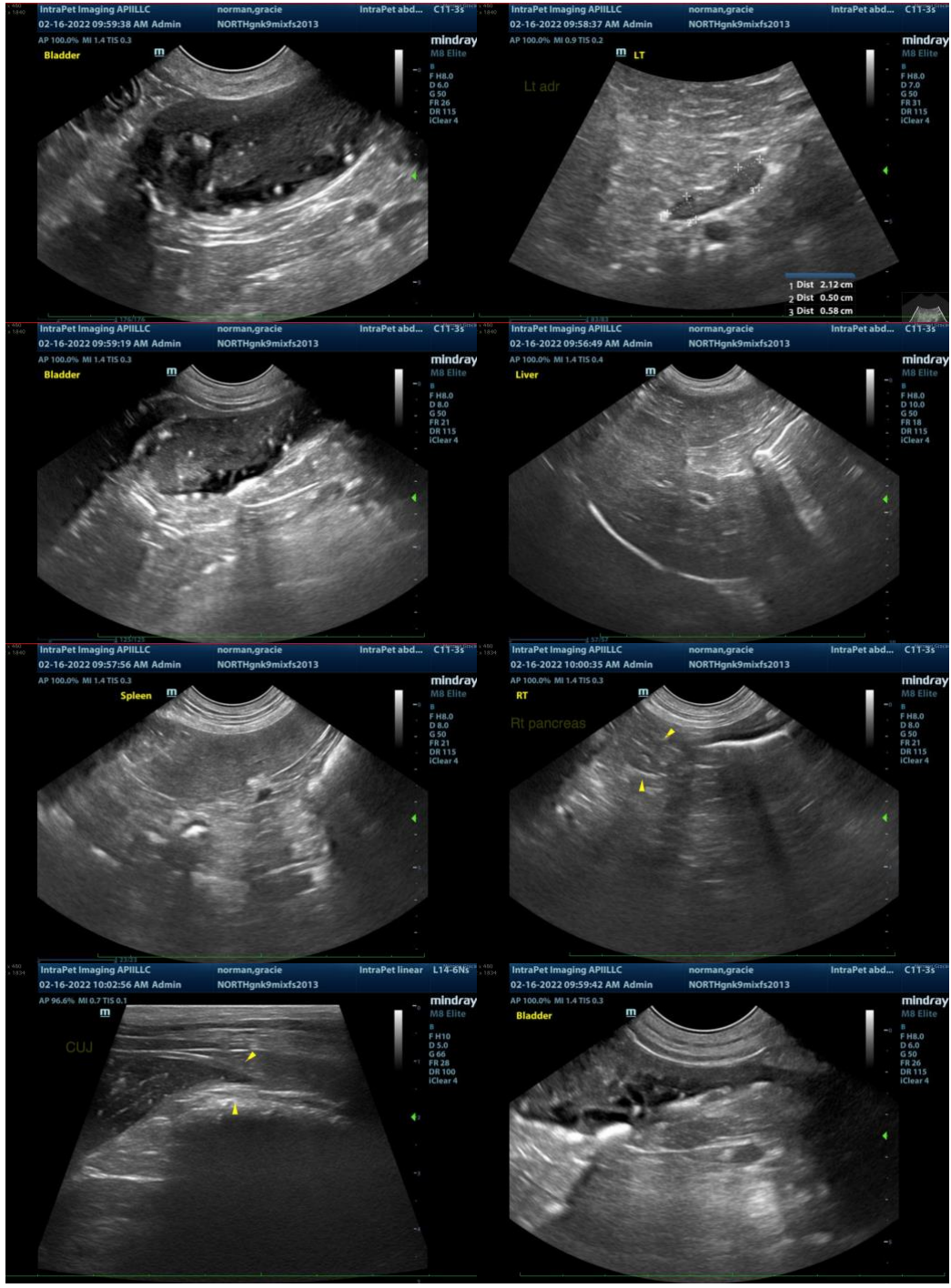
ULTRASONOGRAPHIC FINDINGS

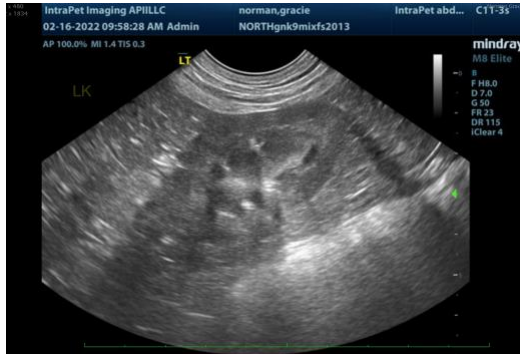- Excessive urinary bladder debris/sand. The mild bladder wall thickening is most consistent with cystitis. An obvious urinary bladder mass is not identified in the study. However, because portions of the bladder wall were obscured by the excessive luminal debris, a small mass cannot be completely excluded.

INTERPRETATION OF THE FINDINGS & FURTHER RECOMMENDATIONS

- A urine culture and sensitivity is recommended. Antibiotic therapy should be based on culture and sensitivity results. An extended antibiotic course (i.e., 3-4 weeks) may be warranted given the recurrence of the urinary tract infections. A urine culture and sensitivity should be repeated 5-7 days after the last dose of antibiotics. Also consider supplementation with cranadin .







The information and recommendations provided are based on the images presented by the referring veterinarian. No evaluation can be communicated regarding pathology that was not visible in the image/video clips provided.

Thank you for this referral. If the clinical or image interpretation does not parallel your findings or if I can be of any further assistance please contact me.

Andrea Nicastro, DVM, Diplomate DACVIM (Small Animal Internal Medicine)
info@SonoPath.com