



PATIENT

Chip Filosa

PRESENTING CLINICAL SIGNS

History: re check previous u/s shows tubular pyloric structure

SPECIES

Canine

ULTRASONOGRAPHIC EXAMINATION OF THE ABDOMEN

Urinary System

The urinary bladder, trigone, and pelvic urethra are normal in thickness and the mucosal surface is smooth. The bladder lumen is moderately distended with anechoic urine. No masses, inflammatory changes or calculi are observed. Ureteral papillae and visualized portion of the proximal urethra, visible to a depth of 2 cm, are normal.

BREED

English Bulldog

The prostate is not definitively visualized due to its pelvic location.

SEX

Neutered Male

The left kidney presented normal size (4.81 cm in length); normal shape and architecture with smooth peripheral margins. There is a normal 1:3 cortex to medulla ratio with normal corticomedullary distinction. There is no evidence of pyelectasia, nephroliths, infarcts or hydronephrosis. Renal vasculature is normal.

AGE

4 Years

The right kidney presented normal size (4.32 cm in length); normal shape and architecture with smooth peripheral margins. There is a normal 1:3 cortex to medulla ratio with normal corticomedullary distinction. There is no evidence of pyelectasia, nephroliths, infarcts or hydronephrosis. Renal vasculature is normal.

WEIGHT

52.5 Lbs.

Adrenal Glands

The left adrenal gland is normal size (0.45 cm at cranial pole) (0.42 cm at caudal pole) (1.70 cm in length); normal shape; homogenous parenchyma. The glandular echogenicity and detail are unremarkable. Capsule, cortex, and medullary definition are normal. The phrenicoabdominal vein and surrounding vasculature are normal.

INTERPRETED BY

Andrea Nicastro, DMV,
Diplomate DACVIM
(Small Animal
Internal Medicine)

The right adrenal gland is normal size (1.07 cm at cranial pole) (0.63 cm at caudal pole) (2.29 cm in length); normal shape; homogenous parenchyma. The glandular echogenicity and detail are unremarkable. Capsule, cortex, and medullary definition are normal. The phrenicoabdominal vein and surrounding vasculature are normal.

IMAGING PERFORMED BY

Jenn

Spleen

The spleen is normal in size (1.41 cm in width at the level of the hilus) with a normal capsular contour. There is appropriate echogenicity and echotexture. No focal lesions are observed. Splenic vasculature is normal.

HOSPITAL NAME

Rockaway AH

REFERRING VET

Liver

The liver is subjectively normal in size with normal contours and structure. There is appropriate echogenicity and echotexture. No overt structural evidence of inflammatory, infiltrative or regenerative pathology is evident. Vascular and biliary tracts are of normal volume with no evidence of congestion. No pathological hepatic lymphadenopathy observed.

Dr. Maniar

INVOICE

13944

The gall bladder lumen is moderately distended. The wall is thin and smooth. Luminal contents are anechoic. The cystic and common bile ducts are normal.

DATE

Gastrointestinal

2/16/22



PATIENT

Chip Filosa

SPECIES

Canine

BREED

English Bulldog

SEX

Neutered Male

AGE

4 Years

WEIGHT

52.5 Lbs.

INTERPRETED BY

Andrea Nicastro, DMV,
Diplomate DACVIM
(Small Animal
Internal Medicine)

IMAGING PERFORMED BY

Jenn

HOSPITAL NAME

Rockway AH

REFERRING VET

Dr. Maniar

INVOICE

13944

DATE

2/16/22

A 4.0 cm, tubular translucent structure is observed in the region of the pyloric antrum. This structure was observed in the previous ultrasounds. There is no evidence of other ingesta within the gastric lumen. The gastric is normal in thickness with a normal layering pattern. The small intestinal lumen is not dilated. The small intestinal wall thickness is normal with a normal layering pattern and appropriate mural detail. Discreet masses are not identified. The colonic wall is normal.

Pancreas

The region of the pancreas is isoechoic relative to surrounding omental fat. No obvious parenchymal abnormalities are observed. There is no evidence of regional inflammation or effusion.

Free Abdomen

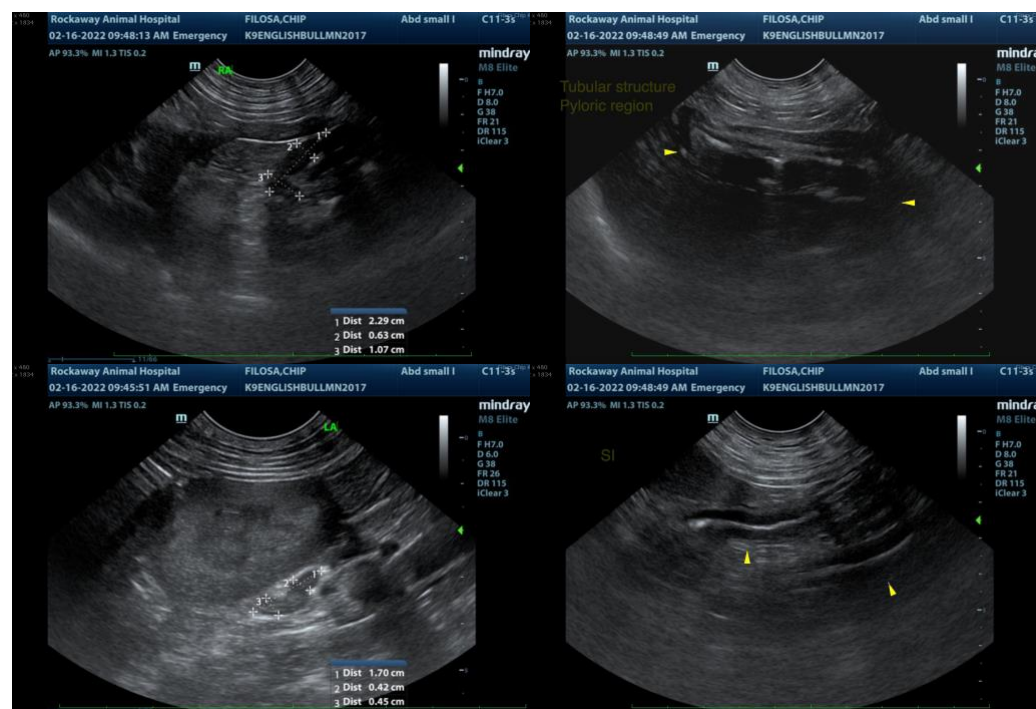
The peritoneal cavity is normal. There is no evidence of inflammation or effusion. The abdominal lymph nodes are normal/not visible.

ULTRASONOGRAPHIC FINDINGS

- Persistent tubular foreign material in the pyloric antrum

INTERPRETATION OF THE FINDINGS & FURTHER RECOMMENDATIONS

Removal of the foreign material via endoscopy or gastrotomy is recommended.





PATIENT

Chip Filosa

SPECIES

Canine

BREED

English Bulldog

SEX

Neutered Male

AGE

4 Years

WEIGHT

52.5 Lbs.

INTERPRETED BY

Andrea Nicastro, DMV,
Diplomate DACVIM
(Small Animal
Internal Medicine)

**IMAGING
PERFORMED BY**

Jenn

HOSPITAL NAME

Rockaway AH

REFERRING VET

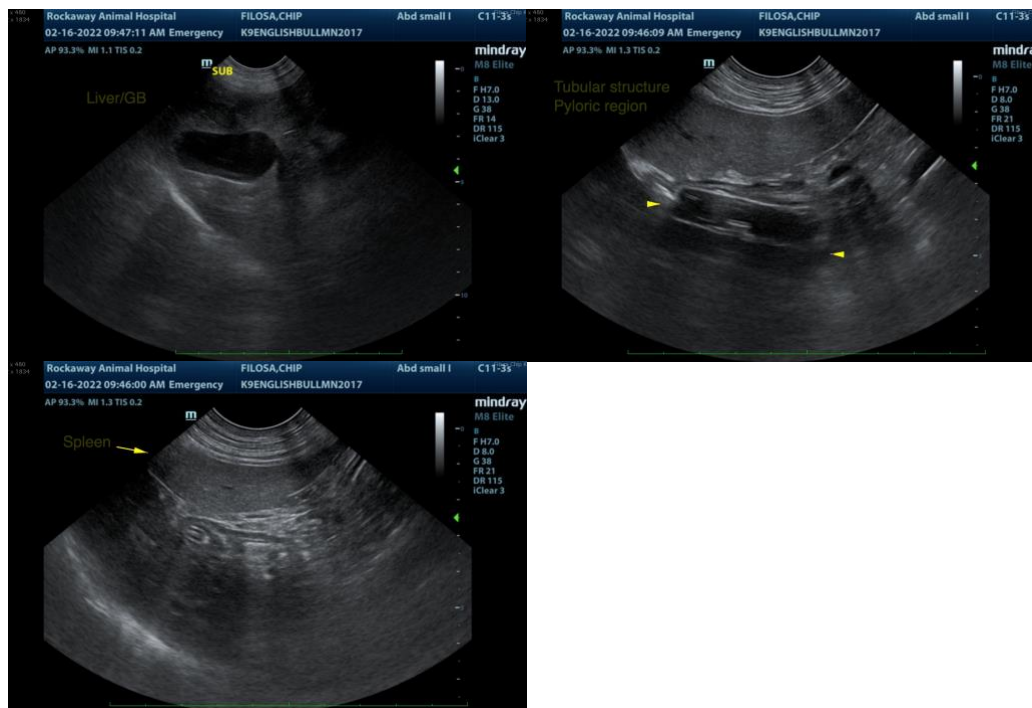
Dr. Maniar

INVOICE

13944

DATE

2/16/22



The information and recommendations provided are based on the images presented by the referring veterinarian. No evaluation can be communicated regarding pathology that was not visible in the image/video clips provided.

Thank you for this referral. If the clinical or image interpretation does not parallel your findings or if I can be of any further assistance please contact me.

Andrea Nicastro, DVM, Diplomate DACVIM (Small Animal Internal Medicine)
info@SonoPath.com