



PATIENT PRESENTING CLINICAL SIGNS

Opal Bechtol

SPECIES

Feline

BREED

DSH

SEX

Spayed Female

AGE

11.5 years

WEIGHT

2.8 kg

INTERPRETED BY

Andrea Nicastro,
DMV, Diplomate
DACVIM (Small Animal
Internal Medicine)

IMAGING PERFORMED BY

Dr. Callihan/Pacific
Crest Mobile

HOSPITAL NAME

Pacific Crest Mobile
Vet

REFERRING VET

Dr. McInnes

INVOICE

10362

DATE

2/15/22

History: Abdominal ultrasound was requested as urgent call-in on 2/7/2022, had presented to primary care vet Dr. McInnes for dental prophylaxis. Recent history PU/PD, weight loss, increased appetite. A new heart murmur was auscultated and abdominal mass palpated on pre-procedure exam. Bloodwork showed elevated thyroid. UA was pending but appeared dilute on cystocentesis. Study was not submitted at time of exam but owner has opted to seek oncology consultation so interpretation is requested for appointment owner has today.

Abnormal PE/Chem/CBC/UA Results: Aspirates of spleen and abdominal lymph nodes were submitted for interpretation and Dr. McGill (DABVP) interpretation follows: **OBSERVATIONS Spleen:** Submitted are 8 excellent videos of splenic cellular collections from Opal. The cellular collections consist of large numbers of lymphocytes with scattered atypical lymphocytes identified. There are dense collections of cells that are difficult to identify. The cells may be lymphocytes as well. There are many small lymphocytes throughout the collection. Those cells appear to be mature. Scattered inflammatory cells are identified. **Nodules:** Submitted are 7 excellent videos of cells collected from the abdominal nodules in Opal. The cells are large round cells with clear to slightly granulated cytoplasm. The nuclei are round and dark stained. There are scattered eosinophils throughout the cellularity. This dense round cellularity is characteristic of intestinal mast cells in the cat. They are present in all of the videos. **INTERPRETATION OF THE FINDINGS & FURTHER RECOMMENDATIONS Spleen -** Large numbers of lymphoid cells suggesting lymphoid hyperplasia or possible early small to intermediate cell lymphoma. **Nodules -** Feline intestinal mast cell tumor **COMMENTS** The cellularity in the nodules is diagnostic for the presence of feline mast cell disease in the abdominal cavity and likely in the intestine. All of the videos have those cells. This is a difficult neoplastic process to treat and thus an unfavorable prognosis is warranted with the observation of the cells. Other organs may be involved including the spleen and liver, but I was unable to confirm mast cells in the spleen. The changes in the spleen suggest an increased lymphocytic infiltration. This could be the result of small cell lymphoma or could be the result of early lymphoma. This may also be due to lymphocytic hyperplasia. There are some degenerate cells present. With mast cell disease, working up the lymphocytes in the spleen is probably not a good exercise. Again, an unfavorable prognosis is warranted in my opinion with the mast cell neoplasia.

ULTRASONOGRAPHIC EXAMINATION OF THE ABDOMEN

Urinary System

The urinary bladder is mildly distended. The wall is of appropriate thickness for the level of repletion. The mucosal surface is slightly irregular. A scant amount of suspended echogenic debris is observed within the lumen. No obvious cystic calculi are observed. The region of the trigone appears normal.

The left kidney is small in size (3.25 cm in length); with an irregular shape. The cortex is variably thickened. There is moderate loss of corticomedullary distinction. A cortical infarct is observed at the caudal pole. There is no evidence of pyelectasia, nephroliths or hydronephrosis.

The right kidney is small in size (2.62 cm in length); with a slightly irregular shape. The cortex is variably thickened. There is moderate loss of corticomedullary distinction. There is no obvious evidence of pyelectasia, nephroliths or hydronephrosis.

Adrenal Glands

The region of the adrenal glands is evaluated. No obvious pathology is seen.

Spleen

The spleen is normal in size (00.88 cm in width at the level of the hilus) with a normal capsular contour. There is appropriate echogenicity and echotexture. No focal lesions are observed. Splenic



PATIENT vasculature is normal.

Opal Bechtol

Liver

The liver is subjectively normal in size with normal contours and structure. There is appropriate echogenicity and echotexture. No overt structural evidence of inflammatory, infiltrative, or regenerative pathology is evident. Vascular and biliary tracts are of normal volume with no evidence of congestion. No pathological hepatic lymphadenopathy observed.

SPECIES

Feline

The gall bladder lumen is moderately distended. The wall is thin and smooth. Luminal contents are anechoic. The cystic and common bile ducts are normal.

BREED

DSH

Gastrointestinal

The gastric lumen is over distended with ingesta. The gastric wall and pylorus are normal in thickness with a normal layering pattern. The pyloric outflow tract is suspected to be patent. The small intestinal lumen is segmentally dilated with chyme. The small intestinal wall thickness is normal with a normal layering pattern and appropriate mural detail. Discreet masses are not identified. The colonic wall is normal. No obstructive disease is noted.

SEX

Spayed Female

AGE

11.5 years

Pancreas

The pancreas is largely obscured by the gastric distention. In the visualized portions, no obvious pathology is seen.

WEIGHT

2.8 kg

Free Abdomen

There is no evidence of free fluid. The mesenteric lymph nodes are severely enlarged, irregular, and hypoechoic to heterogenous with a mass effect (4.56 cm in length), involving some of the nodes. The mesentery effacing the nodes is hyperechoic.

ULTRASONOGRAPHIC FINDINGS

INTERPRETED BY

Andrea Nicastro,
DMV, Diplomate
DACVIM (Small Animal
Internal Medicine)

Primary Findings

- Based on the lymph node cytology results, systemic mast cell disease is likely.

Secondary Findings

- Bilateral degenerative renal changes with a left cortical infarct

IMAGING PERFORMED BY

Dr. Callihan/Pacific
Crest Mobile

INTERPRETATION OF THE FINDINGS & FURTHER RECOMMENDATIONS

- Three-view thoracic radiographs are recommended to assess for pulmonary metastases.
- A fine-needle aspirate of the liver can be considered to further assess for mast cell disease.
- For further recommendations, consultation with a board-certified oncologist is recommended.

HOSPITAL NAME

Pacific Crest Mobile
Vet

REFERRING VET

Dr. McInnes

INVOICE

10362

DATE

2/15/22



PATIENT

Opal Bechtol

SPECIES

Feline

BREED

DSH

SEX

Spayed Female

AGE

11.5 years

WEIGHT

2.8 kg

INTERPRETED BY

Andrea Nicastro,
DMV, Diplomate
DACVIM (Small Animal
Internal Medicine)

**IMAGING
PERFORMED BY**

Dr. Callihan/Pacific
Crest Mobile

HOSPITAL NAME

Pacific Crest Mobile
Vet

REFERRING VET

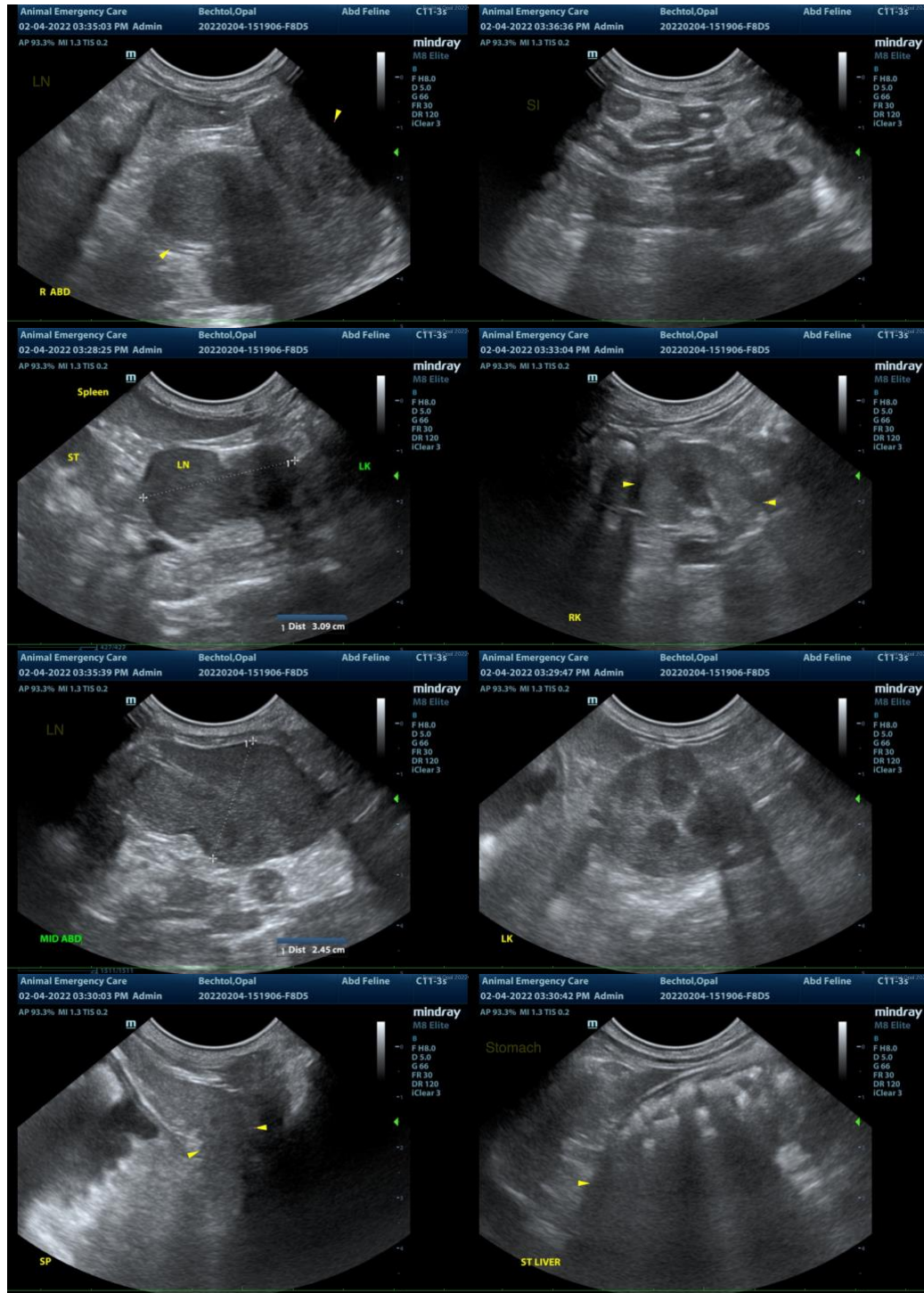
Dr. McInnes

INVOICE

10362

DATE

2/15/22





PATIENT

Opal Bechtol

SPECIES

Feline

BREED

DSH

SEX

Spayed Female

AGE

11.5 years

WEIGHT

2.8 kg

INTERPRETED BY

Andrea Nicastro,
DMV, Diplomate
DACVIM (Small Animal
Internal Medicine)

**IMAGING
PERFORMED BY**

Dr. Callihan/Pacific
Crest Mobile

HOSPITAL NAME

Pacific Crest Mobile
Vet

REFERRING VET

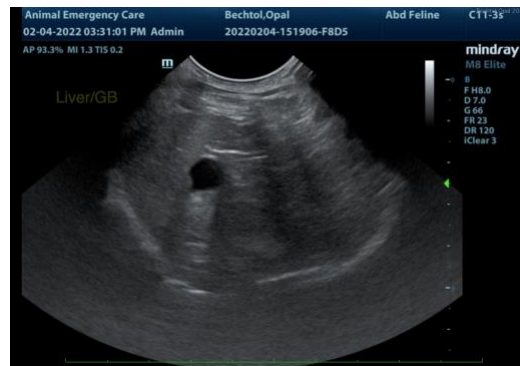Dr. McInnes

INVOICE

10362

DATE

2/15/22



The information and recommendations provided are based on the images presented by the referring veterinarian/sonographer. No evaluation can be communicated regarding pathology that was not visible in the image/video clips provided.

Thank you for this referral. If the clinical or image interpretation does not parallel your findings or if I can be of any further assistance, please contact me.

Andrea Nicastro, DVM, Diplomate DACVIM (Small Animal Internal Medicine)
info@SonoPath.com