



**PATIENT**

Lucas Santiago

**SPECIES**

Canine

**BREED**

Miniature Schnauzer

**SEX**

Male, neutered

**AGE**

9 Yrs.

**WEIGHT**

18 lbs.

**INTERPRETED BY**

Andrea Nicastro, DVM,  
Diplomate ACVIM  
(*Small Animal Internal  
Medicine*)

**IMAGING  
PERFORMED BY**

Dr. Ferrer

**HOSPITAL NAME**

Paseos VC

**REFERRING VET**

Dr. Martes

**INVOICE**

14584

**DATE**

2/14/23

**PRESENTING CLINICAL SIGNS**

**History:** Patient was presented on 2/10/23 for evaluation of an acute history of decreased appetite. Patient had been eating less since the day before. The only change in diet was that he was given rice on 2/5/23. He does not have vomiting or diarrhea. He is BAR at home. He is not up to date on preventives. On physical exam, he has a grade II/VI heart murmur, periodontal disease and lenticular sclerosis.

**Abnormal PE/Chem/CBC/UA Results:** CBC - mild, regenerative hypochromic macrocytic anemia; lymphocytosis, leukocytosis and monocytosis RBC 3.57 M/ $\mu$ L 5.65 - 8.87, HCT 31.4 % 37.3 - 61.7, HGB 8.8 g/dL 13.1 - 20.5, MCV 88.0 fL 61.6 - 73.5, MCHC 28.0 g/dL 32.0 - 37.9, RDW 25.9 % 13.6 - 21.7, RETIC 278.5 K/ $\mu$ L 10.0 - 110.0, RETIC-HGB 20.8 pg 22.3 - 29.6, WBC \* 22.09 K/ $\mu$ L 5.05 - 16.76, LYM \* 9.67 K/ $\mu$ L 1.05 - 5.10, MONO \* 1.77 K/ $\mu$ L 0.16 - 1.12, MPV 16.2 fL 8.7 - 13.2 CHEM - hyperproteinemia and hyperglobulinemia; increased ALP TP 8.4 g/dL 5.2 - 8.2, GLOB 4.9 g/dL 2.5 - 4.5, ALKP 288 U/L 23 - 212 4dx - negative fecal - negative radiographs - suspect splenomegaly CBC review and immune panel - Coomb's positive; autoagglutination positive; spherocytes

**ULTRASONOGRAPHIC EXAMINATION OF THE ABDOMEN**

*Urinary System*

The urinary bladder and visible portion of the pelvic urethra are normal for the degree of luminal distension. The urine is anechoic with no evidence of debris. Cystic calculi and discrete masses are not observed. The region of the trigone and the visible portion of the proximal urethra are normal.

The prostate is normal in size (0.85 cm in width) and shape. Parenchyma is homogenous. The prostatic urethra appears normal without evidence of dilation or obstruction.

The left kidney is normal in size (5.29 cm in length) with a normal shape, smooth peripheral margins and normal internal architecture. There is mild loss of corticomedullary distinction. Several hyperechoic shadowing diverticular foci are observed. There is no evidence of pyelectasia, infarcts or hydronephrosis.

The right kidney is normal size (5.03 cm in length) with a normal shape, smooth peripheral margins and normal internal architecture. There is mild to moderate loss of corticomedullary distinction. Several hyperechoic shadowing diverticular foci are observed. There is no evidence of pyelectasia, infarcts or hydronephrosis.

*Adrenal Glands*

The left adrenal gland is normal size (0.47 cm at cranial pole) (0.54 cm at caudal pole) (2.39 cm in length); normal shape; homogenous parenchyma. The glandular echogenicity and detail are unremarkable. Capsule, cortex, and medullary definition are normal. The phrenicoabdominal vein and surrounding vasculature are normal.

The right adrenal gland is normal size (0.67 cm at cranial pole) (0.46 cm at caudal pole) (2.18 cm in length); normal shape; homogenous parenchyma. The glandular echogenicity and detail are unremarkable. Capsule, cortex, and medullary definition are normal. The phrenicoabdominal vein and surrounding vasculature are normal.

*Spleen*

The spleen is prominent in size (1.93 cm in width at the level of the hilus) with slightly swollen peripheral contours. The parenchyma is subtly mottled in appearance. No focal lesions are observed. Splenic vasculature is normal.

*Liver*



**PATIENT**

Lucas Santiago

The liver is subjectively enlarged with slightly swollen peripheral contours. The parenchyma is isoechoic to slightly hypoechoic relative to the spleen and diffusely homogeneous in appearance. No distinct focal lesions are observed. Vascular and biliary tracts are of normal volume with no evidence of congestion. The gall bladder lumen is moderately distended. The wall is thin and smooth. A moderate amount of aggregated, echogenic partially dependent debris/sludge is observed within the lumen. The cystic and common bile ducts are normal/not seen.

**SPECIES**

Canine

**Gastrointestinal**

**BREED**

Miniature Schnauzer

The stomach and intestine are free of stasis and exhibit normal peristaltic activity. The gastric lumen is not distended. The gastric wall and pylorus are normal in thickness with a normal layering pattern. The pyloric outflow tract is patent. The small intestinal lumen is not dilated. The small intestinal wall thickness is normal with a normal layering pattern and appropriate mural detail. Discreet masses are not identified. The ileocecolic junction and colonic wall are normal. No obstructive disease is noted.

**SEX**

Male, neutered

**Pancreas**

**AGE**

9 Yrs.

The right limb of the pancreas is visible with normal curvilinear peripheral contours. The parenchyma is largely isoechoic relative to surrounding omental fat and slightly mottled in appearance. The pancreatic duct is visible but not overtly dilated. There is no evidence of peripancreatic inflammation or effusion.

**Free Abdomen**

**WEIGHT**

18 lbs.

There is no obvious evidence of free fluid. 1-2 medial iliac lymph nodes are visible, the largest measuring 1.25 cm in length. A few prominent mesenteric lymph nodes are also seen, the largest measuring 1.68 cm in length. The nodes are normal in shape and echogenicity.

**INTERPRETED BY**

Andrea Nicastro, DVM,  
Diplomate ACVIM  
(Small Animal Internal  
Medicine)

**ULTRASONOGRAPHIC FINDINGS**

**Primary Findings:**

- The splenic parenchymal changes are most consistent with a benign process such as lymphoid hyperplasia, extramedullary hematopoiesis, splenitis or antigenic stimulation with a low possibility of infiltrative neoplasia (i.e., lymphoma, mast cell neoplasia).

**Secondary Findings:**

- Suspected benign diffuse hepatopathy. Vacuolar hepatopathy (i.e., idiopathic, endocrine) is a top differential with a lower possibility of inflammatory disease, infiltrative neoplasia or other hepatopathies.
- The pancreatic changes are most consistent with age-related parenchymal remodeling, potentially secondary to a prior inflammatory episode, early fibrosis or chronic pancreatitis.
- Bilateral, chronic renal changes with dystrophic mineralization.

**IMAGING PERFORMED BY**

Dr. Ferrer

**HOSPITAL NAME**

Paseos VC

**REFERRING VET**

Dr. Martes

**INTERPRETATION OF THE FINDINGS & FURTHER RECOMMENDATIONS**

**INVOICE**

14584

- Thoracic radiographs are recommended to assess for occult neoplasia in the chest.
- A comprehensive tick panel, including PCR and serology (submission to North Carolina State University's Vector Borne Disease Diagnostic Lab) is recommended. <https://cvm.ncsu.edu/research/labs/clinical-sciences/vector-borne-disease/>.

**DATE**

2/14/23



## PATIENT

Lucas Santiago

- Depending on the results of the above diagnostics as well as the CBC path review, immune panel and splenic cytology, initiation of treatment for immune mediated hemolytic anemia (i.e., immunosuppressive agents) may be warranted.

## SPECIES

Canine

## BREED

Miniature Schnauzer

## SEX

Male, neutered

## AGE

9 Yrs.

## WEIGHT

18 lbs.

## INTERPRETED BY

Andrea Nicastro, DVM,  
Diplomate ACVIM  
(Small Animal Internal  
Medicine)

## IMAGING PERFORMED BY

Dr. Ferrer

## HOSPITAL NAME

Paseos VC

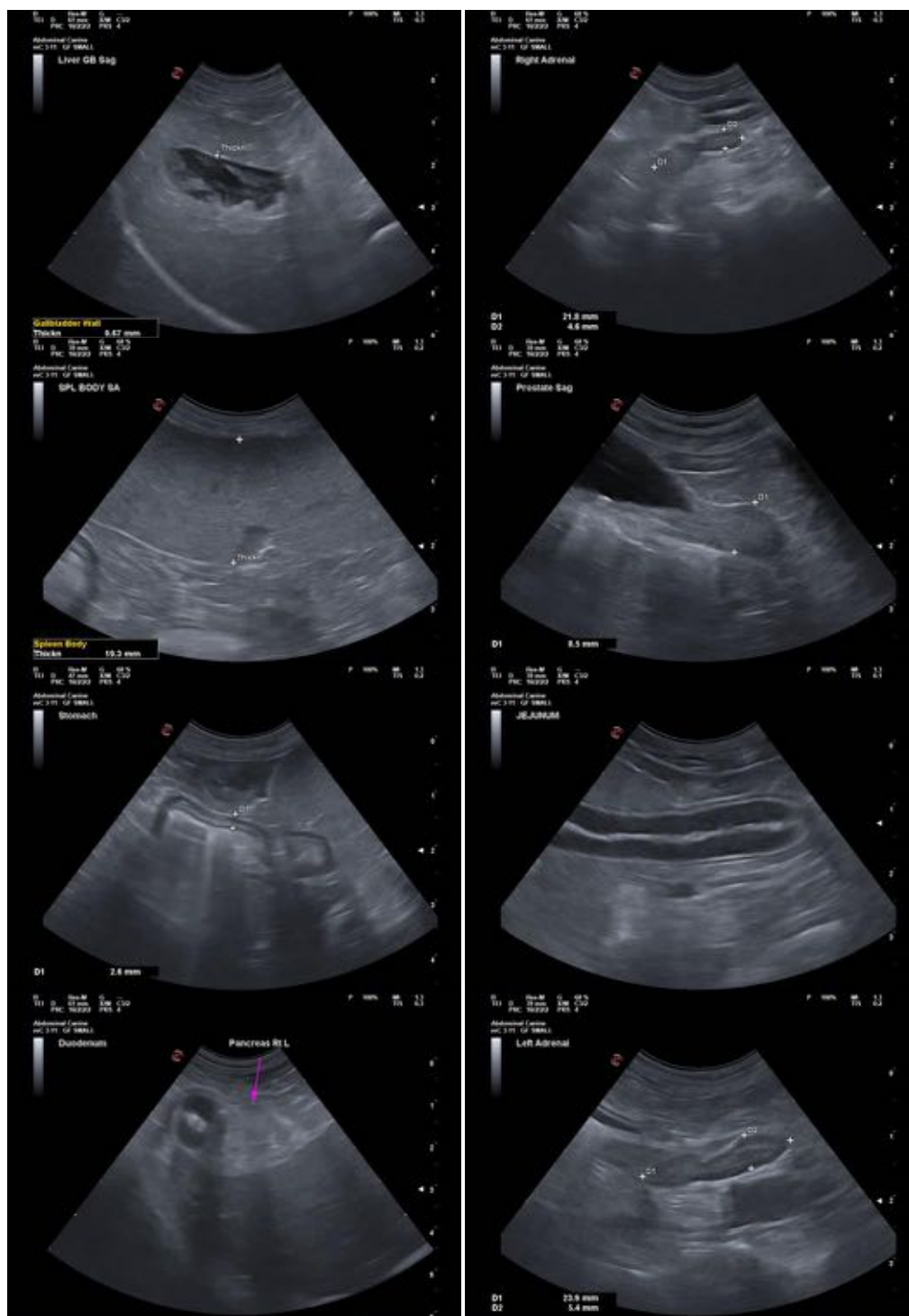
## REFERRING VET

Dr. Martes

## INVOICE

14584

DATE  
2/14/23



The information and recommendations provided are based on the images presented by the referring



**PATIENT**

Lucas Santiago

veterinarian/sonographer. No evaluation can be communicated regarding pathology that was not visible in the image/video clips provided.

**SPECIES**

Canine

Thank you for this referral. If the clinical or image interpretation does not parallel your findings or if I can be of any further assistance please contact me.

Andrea Nicastro, MPH, DVM, Diplomate DACVIM (Small Animal Internal Medicine)  
[info@SonoPath.com](mailto:info@SonoPath.com)

**BREED**

Miniature Schnauzer

**SEX**

Male, neutered

**AGE**

9 Yrs.

**WEIGHT**

18 lbs.

**INTERPRETED BY**

Andrea Nicastro, DVM,  
Diplomate ACVIM  
(*Small Animal Internal  
Medicine*)

**IMAGING  
PERFORMED BY**

Dr. Ferrer

**HOSPITAL NAME**

Paseos VC

**REFERRING VET**

Dr. Martes

**INVOICE**

14584

**DATE**

2/14/23