

PATIENT PRESENTING CLINICAL SIGNS

PATIENT Snickers Hom
SPECIES Feline
BREED Himalayan
SEX Neutered Male
AGE 14 years
WEIGHT 11.4 lbs

History: stranguria, change in bowel movement diameter; large liver and possible ascites on abd rads; wt loss
 Abnormal PE/Chem/CBC/UA Results: nsf on BW and UA

ULTRASONOGRAPHIC EXAMINATION OF THE ABDOMEN

Urinary System

The urinary bladder is mildly distended with mostly anechoic urine. In the region of the apex, a 1.32 x 0.59 cm echogenic tissue structure is observed adjacent to +/- invading the serosal surface. The remaining urinary bladder wall is normal in thickness for the level of repletion. Cystic calculi are not seen. The region of the trigone and the visualized portion of the proximal urethra are normal.

The left kidney is normal size (4.58 cm in length); normal shape and architecture with smooth peripheral margins. There is a normal 1:3 cortex to medulla ratio with moderate loss of corticomedullary distinction. There is no evidence of pyelectasia, nephroliths, infarcts or hydroureter. Renal vasculature is normal.

The right kidney is normal size (5.14 cm in length); normal shape and architecture with smooth peripheral margins. There is a normal 1:3 cortex to medulla ratio with normal corticomedullary distinction. There is no evidence of pyelectasia, nephroliths, infarcts or hydroureter. Renal vasculature is normal.

Adrenal Glands

The left adrenal gland is normal size (0.57 cm length; 0.28 cm width). Normal shape and glandular echogenicity. The phrenicoabdominal vein and surrounding vasculature are normal.

The right adrenal gland is normal size (0.77 cm length; 0.43 cm width). Normal shape and glandular echogenicity. The phrenicoabdominal vein and surrounding vasculature are normal.

Spleen

The spleen is normal in size (0.97 cm in width at the level of the hilus) with a normal capsular contour. There is appropriate echogenicity and echotexture. A few small hyperechoic nodules are visualized. Splenic vasculature is normal.

Liver

The liver is subjectively normal in size with slightly irregular peripheral contours and structure. A 2.43 x 1.60 cm hyperechoic to heterogenous multi-septated cystic mass is observed the caudal aspect. The remaining parenchyma is homogenous. Hepatic vasculature and intrahepatic biliary tracts are of normal volume with no evidence of congestion.

The gall bladder lumen is mildly to moderately distended. The wall is normal in thickness. Luminal contents are mostly anechoic. The cystic and common bile ducts are visible/tortuous and borderline dilated (up to 0.31 cm in diameter). The common bile duct can be followed to its entry point into the duodenal papilla. There is no obvious evidence of an intraluminal obstruction.

Gastrointestinal

The stomach and intestine are free of stasis and exhibit normal peristaltic activity. The gastric lumen is not distended. The gastric wall and pylorus are normal in thickness with a normal layering pattern. The pyloric outflow tract is patent. The small intestinal lumen is not dilated. The small intestinal wall thickness is normal with a normal layering pattern and appropriate mural detail. Discreet masses are not identified. The colonic wall is normal. No obstructive disease is noted.

INTERPRETED BY

Andrea Nicastro, DMV,
 Diplomate DACVIM
 (Small Animal
 Internal Medicine)

IMAGING PERFORMED BY

Diane McFadden

HOSPITAL NAME

Newton VH

REFERRING VET

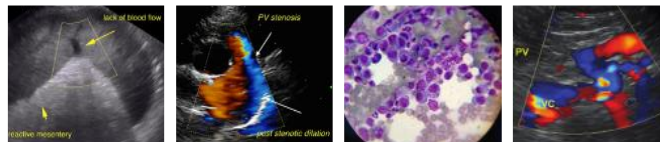
Dr. Chabora

INVOICE

10342

DATE

2/14/22



PATIENT

Snickers Hom

Pancreas

The left limb is prominent in size with minimal deviation from the normal peripheral contours. The parenchyma is hypoechoic relative to surrounding omental fat. No distinct focal lesions are observed. The pancreatic duct is visible but not overtly dilated (0.21 cm in diameter).

SPECIES

Feline

Free Abdomen

A >6 cm hyperechoic mass effect is observed within the omentum in the cranial to mid-abdominal region. The remainder of the omentum is hyperechoic and irregular with several small, irregular hypoechoic nodules throughout the abdomen. A small to moderate amount of free fluid is present. The abdominal lymph nodes are normal/not visible.

BREED

Himalayan

ULTRASONOGRAPHIC FINDINGS

SEX

Neutered Male

Primary Findings

- The omental mass effect and diffuse omental changes are concerning for carcinomatosis. Other differentials include feline infectious peritonitis, severe steatitis, other

AGE

14 years

Secondary Findings

- Bilateral degenerative renal changes with dystrophic mineralization
- The hepatic mass is most consistent with a biliary cystadenoma or cystadenocarcinoma.
- The hyperechoic splenic nodules are likely benign (i.e., myelolipomas or foci of lymphoid hyperplasia).
- The pancreatic changes are suggestive of chronic pancreatitis with a questionable active component.
- The borderline dilation of the cystic/common bile ducts may be secondary to partial extraluminal obstruction from the omental mass effect.
- The echogenic tissue at the serosal surface of the bladder apex may represent enflamed mesentery, granuloma, or tumor.

WEIGHT

11.4 lbs

INTERPRETED BY

Andrea Nicastro, DMV,
Diplomate DACVIM
(Small Animal
Internal Medicine)

INTERPRETATION OF THE FINDINGS & FURTHER RECOMMENDATIONS

IMAGING PERFORMED BY

Diane McFadden

- Three-view thoracic radiographs are recommended to assess for pulmonary metastases.
- A fine-needle aspirate of the omental mass effect is recommended if clotting status is appropriate. Submission of the abdominal fluid for cytology should also be considered. If cytologic evaluations are inconclusive, surgical biopsies of the omentum may be necessary to get a definitive diagnosis.
- Also consider an fPLI to further assess for pancreatitis.

HOSPITAL NAME

Newton VH

REFERRING VET

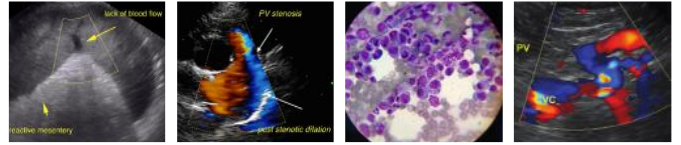
Dr. Chabora

INVOICE

10342

DATE

2/14/22



PATIENT

Snickers Hom

SPECIES

Feline

BREED

Himalayan

SEX

Neutered Male

AGE

14 years

WEIGHT

11.4 lbs

INTERPRETED BY

Andrea Nicastro, DMV,
Diplomate DACVIM
(Small Animal
Internal Medicine)

**IMAGING
PERFORMED BY**

Diane McFadden

HOSPITAL NAME

Newton VH

REFERRING VET






Dr. Chabora

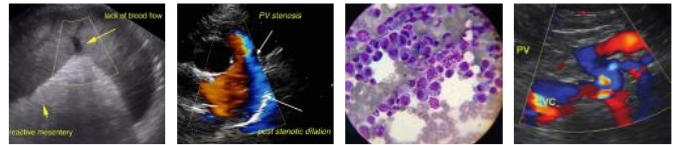
INVOICE

10342

DATE

2/14/22

 <p>A picture containing text, electronics Description automatically generated</p>	 <p>Graphical user interface, website Description automatically generated</p>
 <p>A screenshot of a ultrasound Description automatically generated with medium confidence</p>	 <p>Graphical user interface, website Description automatically generated</p>
 <p>A picture containing website Description automatically generated</p>	 <p>A screenshot of a computer Description automatically generated with medium confidence</p>
 <p>Graphical user interface Description automatically generated with medium confidence</p>	 <p>Graphical user interface Description automatically generated</p>



PATIENT

Snickers Hom

SPECIES

Feline

BREED

Himalayan

SEX

Neutered Male

AGE

14 years

WEIGHT

11.4 lbs

INTERPRETED BY

Andrea Nicastro, DMV,
Diplomate DACVIM
(Small Animal
Internal Medicine)

**IMAGING
PERFORMED BY**

Diane McFadden

HOSPITAL NAME

Newton VH

REFERRING VET






Dr. Chabora

INVOICE

10342

DATE

2/14/22

 A picture containing text, indoor, silver Description automatically generated	 Graphical user interface, website Description automatically generated
 A picture containing text, indoor Description automatically generated	 Graphical user interface, website Description automatically generated
 Graphical user interface, website Description automatically generated	

The information and recommendations provided are based on the images presented by the referring veterinarian/sonographer. No evaluation can be communicated regarding pathology that was not visible in the image/video clips provided.

Thank you for this referral. If the clinical or image interpretation does not parallel your findings or if I can be of any further assistance, please contact me.

Andrea Nicastro, DVM, Diplomate DACVIM (Small Animal Internal Medicine)
info@SonoPath.com