



## PATIENT

Maize Brumbach

## PRESENTING CLINICAL SIGNS

## SPECIES

Canine

History: Bloodwork on 1/17/22 showed probable hypercalcemia, recheck on calcium on 2/3/22 showed 12.2 mg/dL (hypercalcemia), Owner reported shortness of breath in January, recorded 42 breaths/min sleeping on 2/3/22, reported breathing more shallow and more frequent than in January. IDEXX results 2/10/22 confirm primary hyper-parathyroidism

## BREED

Border Collie Mix

## ULTRASONOGRAPHIC EXAMINATION OF THE ABDOMEN

## SEX

Spayed Female

### Left Thyroid

The left thyroid lobe measures 2.67 x 0.27 cm in the sagittal plane. Two normal-sized parathyroid glands are visible. The more cranial gland measures 0.22 cm in length, the more caudal gland measures 0.21 cm in length.

## AGE

12 years

### Right Thyroid

The right thyroid lobe measures 2.54 x 0.59 cm in the sagittal plane. A 1.05 x 0.64 cm hypoechoic parathyroid nodule is present. The nodular is somewhat vascular in appearance. The remainder of the lobe is unremarkable.

## WEIGHT

23.45 kg

A cervical lymph node is observed on the left side, measuring 0.78 cm in length. A cervical lymph node is also observed on the right side measuring 1.50 cm in length.

## INTERPRETED BY

Andrea Nicastro, DVM,  
Diplomate ACVIM (Small  
Animal Internal Medicine)

The left and right salivary glands are visualized and are subjectively normal in size, symmetrical, with no obvious pathology.

## ULTRASONOGRAPHIC FINDINGS

- Right parathyroid tumor. Differentials include adenoma, adenocarcinoma or hyperplastic change.

## IMAGING PERFORMED BY

Loetitia Saint-Jacques, RVT

## INTERPRETATION OF THE FINDINGS & FURTHER RECOMMENDATIONS

- Three-view thoracic radiographs are recommended to assess for pulmonary metastases.
- Consultation with a board-certified surgeon is recommended to discuss a right parathyroidectomy.

## HOSPITAL NAME

Roundhill AH

## REFERRING VET

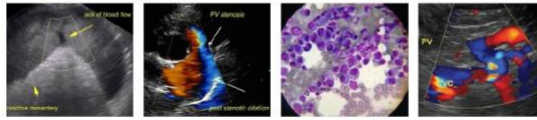
Dr. Carl Kelly

## INVOICE

10365

## DATE

2/14/22



**PATIENT**

Maize Brumbach

**SPECIES**

Canine

**BREED**

Border Collie Mix

**SEX**

Spayed Female

**AGE**

12 years

**WEIGHT**

23.45 kg

**INTERPRETED BY**

Andrea Nicastro, DVM,  
Diplomate ACVIM (Small  
Animal Internal Medicine)

**IMAGING PERFORMED BY**

Loetitia Saint-Jacques, RVT

**HOSPITAL NAME**

Roundhill AH

**REFERRING VET**

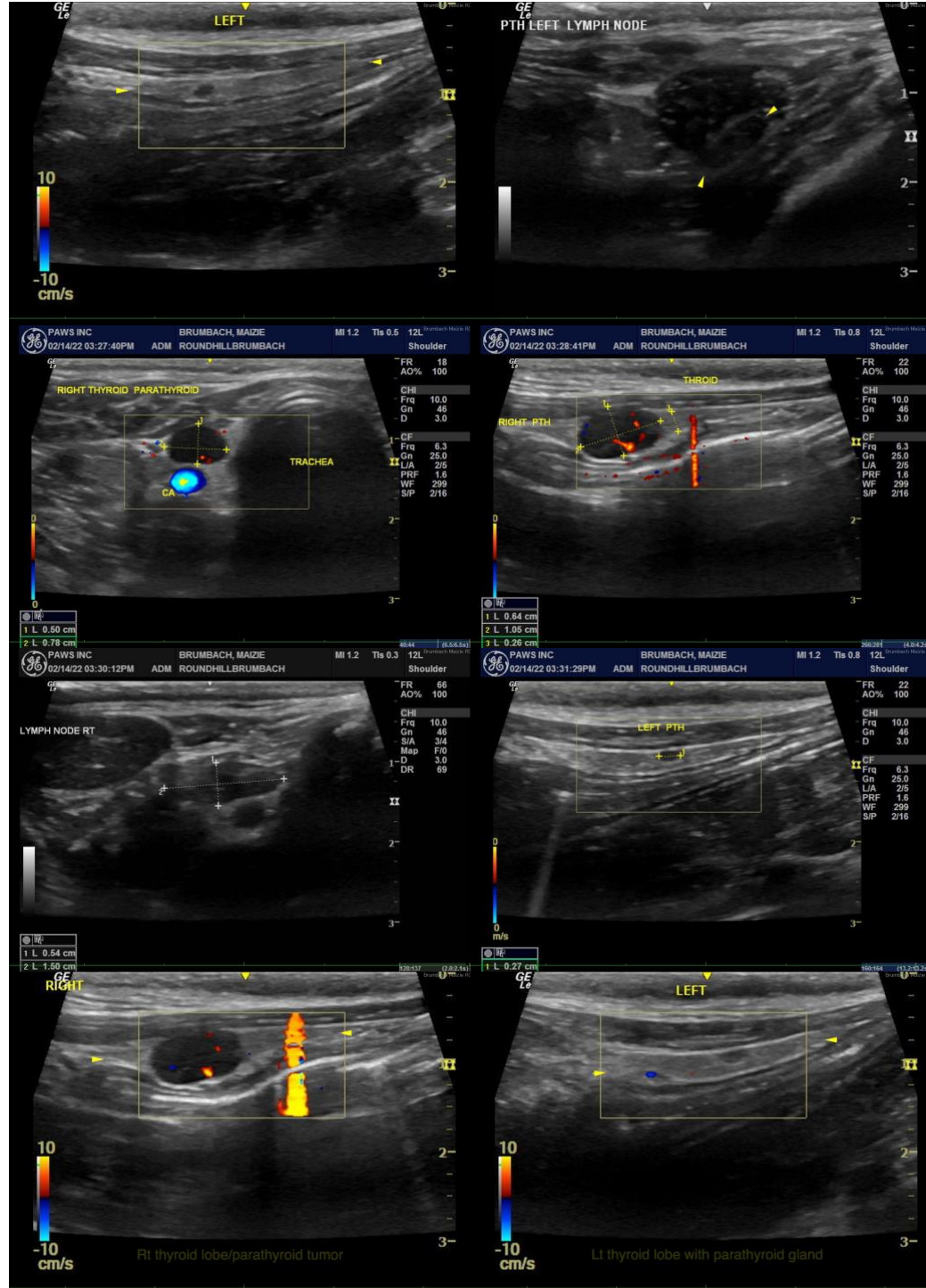
Dr. Carl Kelly

**INVOICE**

10365

**DATE**

2/14/22



The information and recommendations provided are based on the images presented by the referring veterinarian/sonographer. No evaluation can be communicated regarding pathology that was not visible in the image/video clips provided.



**PATIENT**

Maize Brumbach Thank you for this referral. If the clinical or image interpretation does not parallel your findings or if I can be of any further assistance, please contact me.

**SPECIES**

Andrea Nicastro, DVM, Diplomate DACVIM (Small Animal Internal Medicine)  
info@SonoPath.com

Canine

**BREED**

Border Collie Mix

**SEX**

Spayed Female

**AGE**

12 years

**WEIGHT**

23.45 kg

**INTERPRETED BY**

Andrea Nicastro, DVM,  
Diplomate ACVIM (Small  
Animal Internal Medicine)

**IMAGING PERFORMED  
BY**

Loetitia Saint-Jacques, RVT

**HOSPITAL NAME**

Roundhill AH

**REFERRING VET**

Dr. Carl Kelly

**INVOICE**

10365

**DATE**

2/14/22