



PATIENT

Johnny Flanders

SPECIES

Canine

BREED

Australian Shep. Mix

SEX

Neutered Male

AGE

14 years

WEIGHT

50 lbs

INTERPRETED BY

Andrea Nicastro, DVM,
Diplomate ACVIM (*Small
Animal Internal Medicine*)

IMAGING PERFORMED BY

Loetitia Saint-Jacques, RVT

HOSPITAL NAME

Incline VH

REFERRING VET

Dr. Kris Moger

INVOICE

10365

DATE

2/14/22

PRESENTING CLINICAL SIGNS

History: Johnny Flanders 14-yr-od MN Australian shep mix 50# Seen for episode of idiopathic vestibular disease on 1/24/22 Bloodwork ran at that time was all normal except Calcium 14.2mg/dL Hypercalcemia of malignancy panel ran: Ionized CA++ 1.78 (1.25-1.45) PTH 23.70 (1.1-10.6) 3-view chest rads were unremarkable Primary hyperparathyroidism was diagnosed, ultrasound scheduled to locate PT tumor

ULTRASONOGRAPHIC EXAMINATION OF THE ABDOMEN

Left Thyroid

The left thyroid lobe measures 2.33 x 0.46 cm. A 0.69 x 0.44 cm hypoechoic parathyroid nodule is observed. The lesion causes slight capsular expansion.

Right Thyroid

The right thyroid gland measures 3.39 x 0.57 cm in the sagittal plane. A normal-sized (0.25 cm) parathyroid gland is visualized.

A 0.73 x 0.27 cm cervical lymph node is observed on the left side. A 1.89 x 0.44 cm cervical lymph node is observed on the right side.

Both left and right salivary glands are visualized and are subjectively normal in size, symmetrical and homogenous in appearance. No obvious pathology is observed.

ULTRASONOGRAPHIC FINDINGS

Primary Findings

- Left parathyroid nodule/tumor. Differentials include adenoma, adenocarcinoma or focus of hyperplasia.

INTERPRETATION OF THE FINDINGS & FURTHER RECOMMENDATIONS

- Consultation with a board-certified surgeon is recommended to discuss a left parathyroidectomy.



PATIENT

Johnny Flanders

SPECIES

Canine

BREED

Australian Shep. Mix

SEX

Neutered Male

AGE

14 years

WEIGHT

50 lbs

INTERPRETED BY

Andrea Nicastro, DVM,
Diplomate ACVIM (*Small Animal Internal Medicine*)

IMAGING PERFORMED BY

Loetitia Saint-Jacques, RVT

HOSPITAL NAME

Incline VH

REFERRING VET

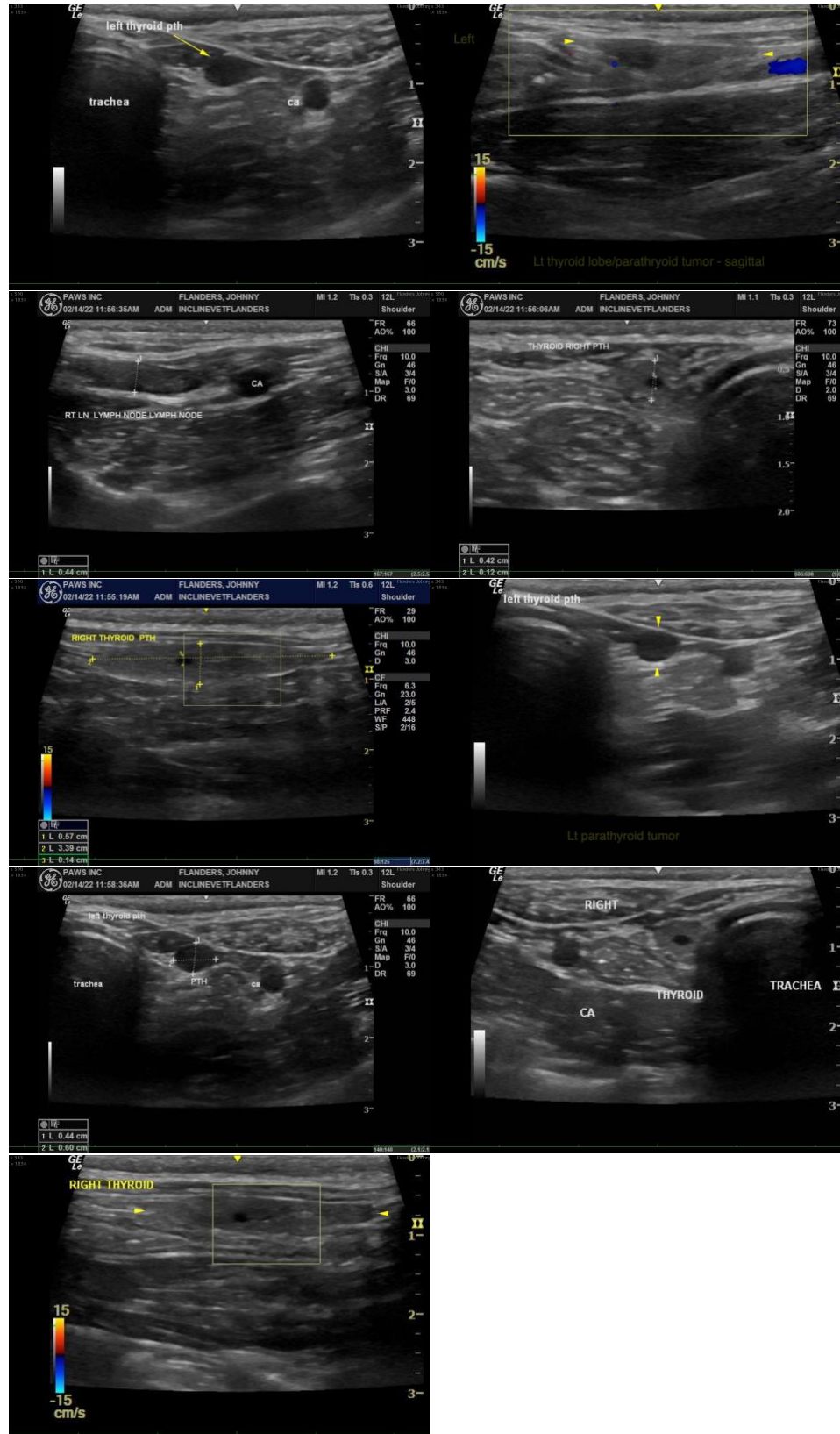
Dr. Kris Moger

INVOICE

10365

DATE

2/14/22





PATIENT

Johnny Flanders

The information and recommendations provided are based on the images presented by the referring veterinarian/sonographer. No evaluation can be communicated regarding pathology that was not visible in the image/video clips provided.

SPECIES

Canine

Thank you for this referral. If the clinical or image interpretation does not parallel your findings or if I can be of any further assistance, please contact me.

BREED

Australian Shep. Mix

Andrea Nicastro, DVM, Diplomate DACVIM (Small Animal Internal Medicine)
info@SonoPath.com

SEX

Neutered Male

AGE

14 years

WEIGHT

50 lbs

INTERPRETED BY

Andrea Nicastro, DVM,
Diplomate ACVIM (*Small Animal Internal Medicine*)

IMAGING PERFORMED BY

Loetitia Saint-Jacques, RVT

HOSPITAL NAME

Incline VH

REFERRING VET

Dr. Kris Moger

INVOICE

10365

DATE

2/14/22