

**DATE**

2/14/2022

**PRESENTING CLINICAL SIGNS**

History: Vomiting, not eating as much, drinking a lot more. Urinary incontinence. Dog has history of mast cell tumor, current blood work indicated leukocytosis with mature neutrophilia, blood chemistry border line TP, Globulin and creatinine. Owner reported dog has urine leakage overnight and PU/PD as well. There is no weight associated with. Radiology consulted and x-rays report was unremarkable.

Lab Results: Attached separately.

Radiographs: Report attached separately.

Date of Previous IntraPet Ultrasound: No previous IntraPet scans.

Sedation: Not required to complete full diagnostic ultrasound.

Stat Report: Not requested.

Imaging Performed By: Rachel Brilahrt, RDMS

Additional history: Urine Specific Gravity 1.009. 1+ proteinuria. Inactive sediment. Urine culture negative.

**PATIENT**

Jamie Parsons

**SPECIES**

Canine

**BREED**

DSH

**SEX**

Spayed Female

**AGE**

5/3/2011

**WEIGHT**

54.1 lbs

**PRESENTING CLINICAL SIGNS****ULTRASONOGRAPHIC EXAMINATION OF THE ABDOMEN****Urinary System**

The urinary bladder is moderately distended with anechoic urine. The wall is normal in thickness with a smooth mucosal surface. No cystic calculi are observed. The region of the trigone is normal. The proximal urethra is mildly thickened (up to 0.51 cm in width). The urethra lumen is not overtly dilated.

The left kidney is normal in size (5.76 cm in length) with a normal shape, smooth peripheral margins, and normal internal architecture. There is mild loss of corticomedullary distinction. Mild pyelectasia is present (0.20 cm in the longitudinal plane). There is no evidence of infarcts or hydroureter. Renal vasculature is normal.

**INTERPRETED BY**

Andrea Nicastro, DMV,  
Diplomate DACVIM  
(Small Animal  
Internal Medicine)

The right kidney is normal size (5.73 cm in length); normal shape and architecture with smooth peripheral margins. There is a normal 1:3 cortex to medulla ratio with minimal to mild loss of corticomedullary distinction. A few nonobstructive nephroliths are visualized. There is no evidence of pyelectasia infarcts or hydroureter. Renal vasculature is normal.

**HOSPITAL NAME**

Glen Burnie AH

**Adrenal Glands**

The left adrenal gland is normal size (0.66 cm at cranial pole) (0.59 cm at caudal pole) (3.07 cm in length); normal shape; homogenous parenchyma. The glandular echogenicity and detail are unremarkable. Capsule, cortex, and medullary definition are normal. The phrenicoabdominal vein and surrounding vasculature are normal.

**REFERRING VET**

Dr. Shah

The right adrenal gland is normal size (0.93 cm at cranial pole) (0.75 cm at caudal pole) (3.04 cm in length); normal shape; homogenous parenchyma. The glandular echogenicity and detail are unremarkable. Capsule, cortex, and medullary definition are normal. The phrenicoabdominal vein and surrounding vasculature are normal.

**INVOICE**

10349

**Spleen**

The spleen is normal in size (1.81 cm in width at the level of the hilus) with a normal capsular contour. There is appropriate echogenicity and echotexture. No focal lesions are observed. Splenic vasculature is normal.

### ***Liver***

The liver is subjectively normal in size with normal contours and structure. There is appropriate echogenicity and echotexture. No overt structural evidence of inflammatory, infiltrative or regenerative pathology is evident. Vascular and biliary tracts are of normal volume with no evidence of congestion. No pathological hepatic lymphadenopathy observed. The gall bladder lumen is moderately distended. The wall is thin and smooth. A small amount of aggregated echogenic, partially dependent debris/sludge is observed within the lumen.

### ***Gastrointestinal***

The stomach and intestine are free of stasis and exhibit normal peristaltic activity. The gastric lumen is not distended. The gastric wall and pylorus are normal in thickness with a normal layering pattern. The small intestinal lumen is not dilated. The small intestinal wall thickness is normal with a normal layering pattern and appropriate mural detail. Discreet masses are not identified. The colonic wall is normal. No obstructive or overt infiltrative disease is noted.

### ***Pancreas***

The region of the pancreas is isoechoic relative to surrounding omental fat. No obvious parenchymal abnormalities are observed. There is no evidence of regional inflammation or effusion.

### ***Free Abdomen***

The peritoneal cavity is normal. There is no evidence of inflammation or effusion. A 1.48 cm medial ileac lymph node is visible.

## **ULTRASONOGRAPHIC FINDINGS**

### **Primary Findings**

- Minor age-related renal changes with trace left pyelectasia and right non-obstructive nephrolithiasis.
- The slightly thickened urethra may be a normal variant for this patient or may be secondary to urethritis or less likely, emerging neoplasia.

### **Secondary Findings**

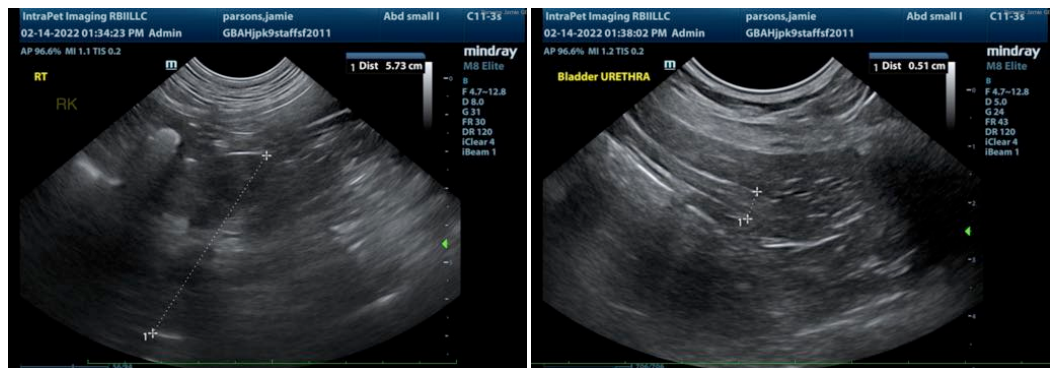
- The prominent medial ileac lymph node is likely reactive.

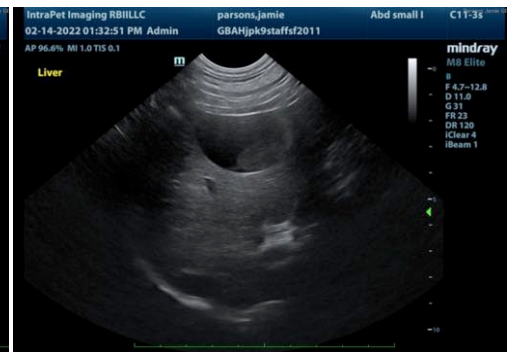
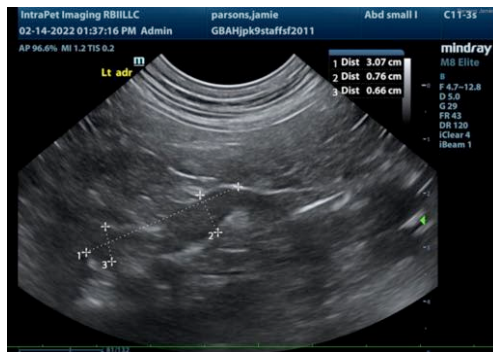
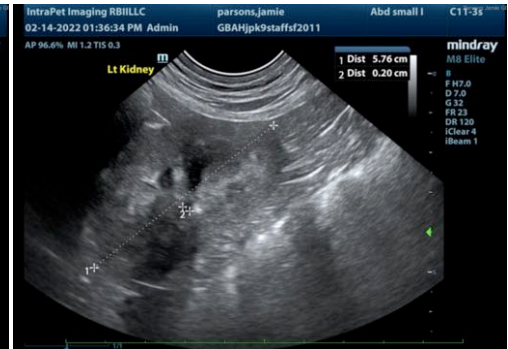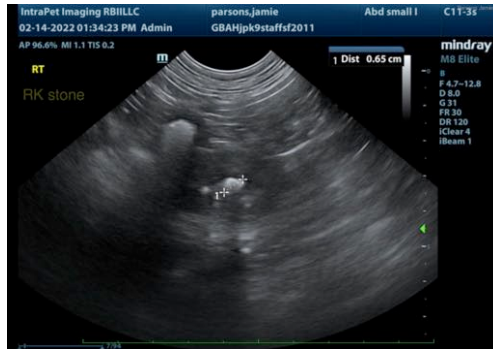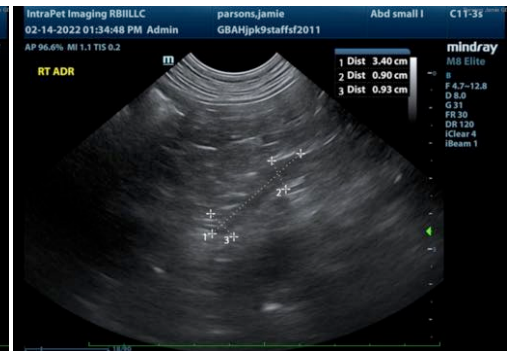
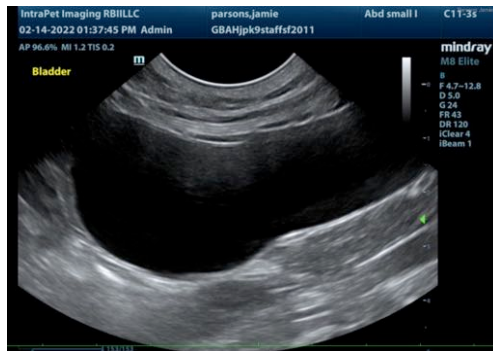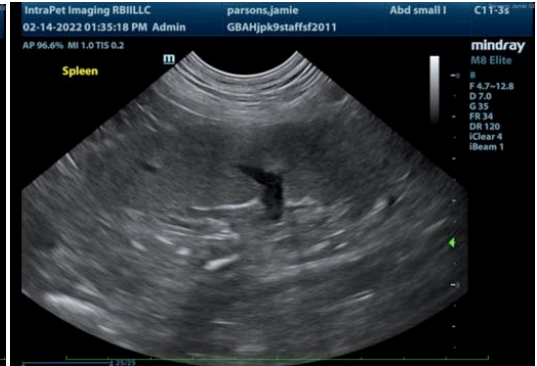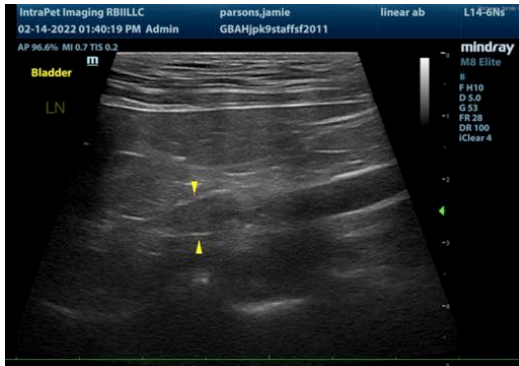
\*\*An obvious cause for the patient's clinical signs is not identified in this study.

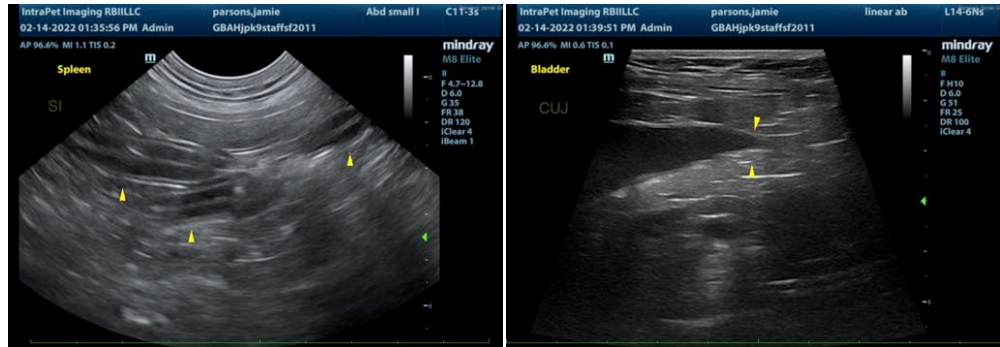
## **INTERPRETATION OF THE FINDINGS & FURTHER RECOMMENDATIONS**

- Regarding the vomiting, consider the following:
  1. Three-view thoracic radiographs to assess for occult esophageal disease.
  2. Malabsorption panel including serum cobalamin, folate, TLI and PLI
  3. Fecal evaluation for ova and Giardia
  4. A resting cortisol level to screen for hypoadrenocorticism. If resting cortisol level is < 2.0 mcg/dL, an ACTH stimulation test is recommended.
  5. +/- hypoallergenic diet trial

- If the above diagnostics are inconclusive and the patient does not respond to supportive care, endoscopic or surgical gastrointestinal biopsies may be warranted.
- Regarding the PU/PD, consider the following:
  1. Pre-and postprandial serum bile acids to assess for occult hepatic dysfunction.
  2. Leptospirosis testing (i.e., blood and urine PCR, serology)
  3. Consider empirical treatment for occult pyelonephritis (i.e., fluoroquinolone). If clinical signs do not improve within 5-7 days of initiating therapy, antibiotics should be discontinued and further diagnostics pursued.
  4. Further testing for Cushing's Disease (i.e., low-dose dexamethasone suppression test) can be considered. However, Cushing's disease is rare in patients with a normal ALP
  5. +/- DDAVP trial to assess for central diabetes insipidus
  6. +/- a modified water deprivation test
- Regarding the incontinence, empirical treatment for urethral sphincter mechanism incompetence (i.e., phenylpropanolamine or diethylstilbesterol) can be considered. However, if the patient does not respond to therapy, medication should be discontinued.
- Regarding the thickened urethra, a urine BRAF test can be considered to further asses for lower urinary tract neoplasia







The information and recommendations provided are based on the images presented by the referring veterinarian/sonographer. No evaluation can be communicated regarding pathology that was not visible in the image/video clips provided.

Thank you for this referral. If the clinical or image interpretation does not parallel your findings or if I can be of any further assistance, please contact me.

**Andrea Nicastro, DVM, Diplomate DACVIM (Small Animal Internal Medicine)**  
info@SonoPath.com