



PATIENT

Cuko Vitola

SPECIES

Feline

BREED

DSH

SEX

Neutered Male

AGE

11 years

WEIGHT

10.2 lbs

INTERPRETED BY

Andrea Nicastro, DMV,
Diplomate DACVIM
(Small Animal
Internal Medicine)

IMAGING PERFORMED BY

Dr. Ferrer DVM

HOSPITAL NAME

Paseos VC

REFERRING VET

Dr. Jenniffer Walker

INVOICE

10358

DATE

2/14/22

PRESENTING CLINICAL SIGNS

Cuko Vitola

History: Presented for an abdominal ultrasound to evaluate vomiting and losing weight. Originally presented on 12-30-21 for vomiting and was given Depomedrol, Metronidazole, and Famotidine. The pt originally improved but vomiting came back again and was mentioned during the visit on Feb 11, 2022, and recommended BW with GI panel and abdominal ultrasound.

Abnormal PE/Chem/CBC/UA Results: BW: CBC: unremarkable CHEM: Total Protein 2.4 (5.7 - 8.9 g/dL) Albumin 2.2 (2.3 - 3.9 g/dL) Globulin 0.2 (2.8 - 5.1 g/dL) Potassium 3.4 (3.5 - 5.8 mmol/L) T4: declined GI Panel: declined

ULTRASONOGRAPHIC EXAMINATION OF THE ABDOMEN

Urinary System

The urinary bladder, trigone, and pelvic urethra are normal in thickness and the mucosal surface is smooth. The bladder lumen is moderately distended. A small amount of suspended echogenic debris is observed within the lumen. No masses, inflammatory changes or calculi are observed. Ureteral papillae and visualized portion of the proximal urethra, visible to a depth of 2 cm, are normal.

The left kidney is borderline small in size (4.30 cm in length) with a slightly irregular shape, smooth peripheral margins, and normal internal architecture. There is moderate loss of corticomedullary distinction. The cortex is hyperechoic. Several hyperechoic shadowing diverticular foci are observed. Trace pyelectasia is present (0.16 cm in the transverse plane). There is no evidence of infarcts or hydroureter.

The right kidney is normal in size (2.99 cm in length) with a normal shape, smooth peripheral margins, and normal internal architecture. There is moderate loss of corticomedullary distinction. The cortex is hyperechoic. Several hyperechoic shadowing diverticular foci are observed. Trace pyelectasia is present (0.11 cm in the transverse plane). There is no evidence of infarcts or hydroureter.

Adrenal Glands

The left adrenal gland is normal size (0.31 cm width). Normal shape and glandular echogenicity. The phrenicoabdominal vein and surrounding vasculature are normal.

The right adrenal gland is normal size (0.32 cm width). Normal shape and glandular echogenicity. The phrenicoabdominal vein and surrounding vasculature are normal.

Spleen

The spleen is normal in size (00.69 cm in width at the level of the hilus) with a normal capsular contour. There is appropriate echogenicity and echotexture. No focal lesions are observed. Splenic vasculature is normal.

Liver

The liver is subjectively enlarged with slightly swollen peripheral contours. The parenchyma is hyperechoic relative to the spleen and diffusely homogeneous in appearance. A 0.84 cm target-like lesion is observed on the left side. Vascular and biliary tracts are of normal volume with no evidence of congestion. The gall bladder lumen is moderately distended. The wall is thin and smooth. A small amount of aggregated echogenic partially dependent debris is observed within the lumen. The cystic and common bile ducts are normal/not seen.



PATIENT

Cuko Vitola

The gall bladder lumen is moderately distended. The wall is thin and smooth. A moderate amount of partially dependent echogenic debris is observed within the lumen. The cystic and common bile ducts are normal.

SPECIES

Feline

Gastrointestinal

The stomach and intestine are free of stasis and exhibit normal peristaltic activity. The gastric lumen is not distended. The gastric wall and pylorus are normal in thickness with a normal layering pattern. The pyloric outflow tract is patent. The small intestinal lumen is not dilated. The duodenal and jejunal walls are normal to borderline thickened (up to 0.27 cm), with a normal layering pattern and appropriate mural detail. There is slight disruption in the normal normal 1: 1 muscularis to mucosal ratio in most segments. At the level of the ileocecolic junction, a 2.35 x 2.10 irregular hypoechoic to heterogenous mass effect is observed. The wall in this region has a complete loss of the normal layering pattern. The mesentery effacing the serosal surface in this region is hyperechoic. The first few centimeters of the proximal colonic wall are thickened (up to 0.31 cm), with slight loss of the normal layering pattern. The remaining colonic wall is normal. There is no obvious evidence of an obstructive pattern.

BREED

DSH

SEX

Neutered Male

Pancreas

The right limb of the pancreas is visible with normal curvilinear peripheral contours. The parenchyma is largely isoechoic relative to surrounding omental fat and slightly mottled in appearance. The pancreatic duct is visible but not overtly dilated. There is no evidence of peripancreatic inflammation or effusion.

AGE

11 years

WEIGHT

10.2 lbs

Free Abdomen

Trace free fluid is observed. A 1.19 cm medial ileac lymph node is visualized.

ULTRASONOGRAPHIC FINDINGS

INTERPRETED BY

Andrea Nicastro, DMV,
Diplomate DACVIM
(Small Animal
Internal Medicine)

Primary Findings

- Mass at the ileocecolic junction. Neoplasia (i.e., lymphoma, adenocarcinoma) is considered likely with a lower possibility of a severe inflammatory process (i.e., pyrogranulomatous). Regional peritonitis is present.
- The small intestinal wall changes can be consistent with inflammatory bowel disease or emerging lymphoma.

IMAGING PERFORMED BY

Dr. Ferrer DVM

Secondary Findings

- Bilateral degenerative renal changes with dystrophic mineralization
- The hepatic changes could be consistent with hepatic lipidosis, inflammatory disease, infiltrative neoplasia or other hepatopathy. The left hepatic nodule can be consistent with a metastatic lesion or a benign process such as a focus of lymphoid hyperplasia or a granuloma.
- Age-related pancreatic remodeling
- The lymph node change is most consistent with reactive lymphadenitis or lymphoid hyperplasia.

HOSPITAL NAME

Paseos VC

REFERRING VET

Dr. Jenniffer Walker

INVOICE

10358

INTERPRETATION OF THE FINDINGS & FURTHER RECOMMENDATIONS

DATE

2/14/22

- Three-view thoracic radiographs are recommended to assess for pulmonary metastases.



PATIENT

Cuko Vitola

- A fine-needle aspirate of the mass at the ileocecolic junction is recommended if clotting status is appropriate. A 25-gauge needle should be used. If cytology results are inconclusive and an aggressive approach is desired, an abdominal exploratory with biopsy of the mass (and liver biopsies) can be considered.

SPECIES

Feline

- Also consider a GI panel including serum cobalamin, folate, TLI and PLI

BREED

DSH

SEX

Neutered Male

AGE

11 years

WEIGHT

10.2 lbs

INTERPRETED BY

Andrea Nicastro, DMV,
Diplomate DACVIM
(Small Animal
Internal Medicine)

IMAGING PERFORMED BY

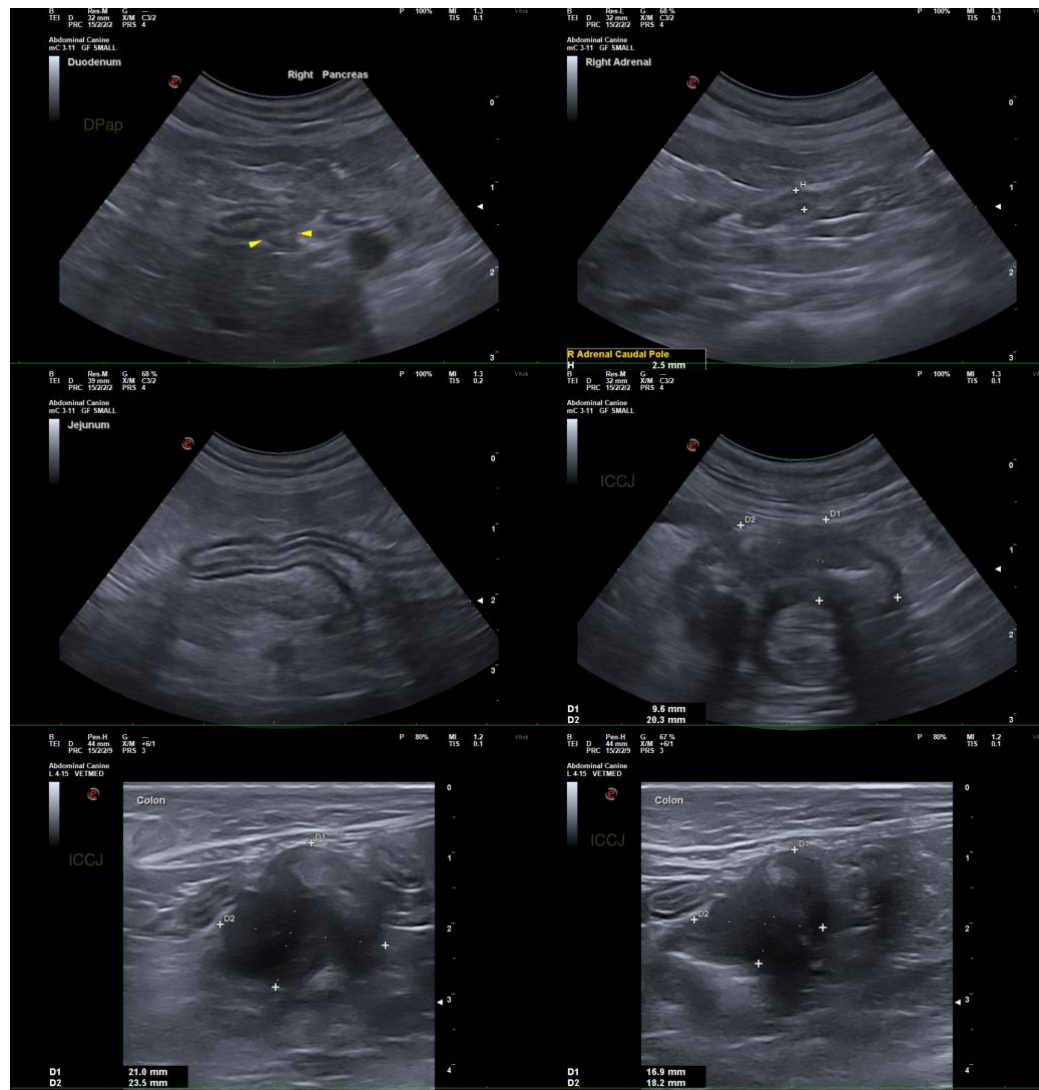
Dr. Ferrer DVM

HOSPITAL NAME

Paseos VC

REFERRING VET

Dr. Jenniffer Walker



INVOICE

10358

DATE

2/14/22



PATIENT

Cuko Vitola

SPECIES

Feline

BREED

DSH

SEX

Neutered Male

AGE

11 years

WEIGHT

10.2 lbs

INTERPRETED BY

Andrea Nicastro, DMV,
Diplomate DACVIM
(Small Animal
Internal Medicine)

**IMAGING
PERFORMED BY**

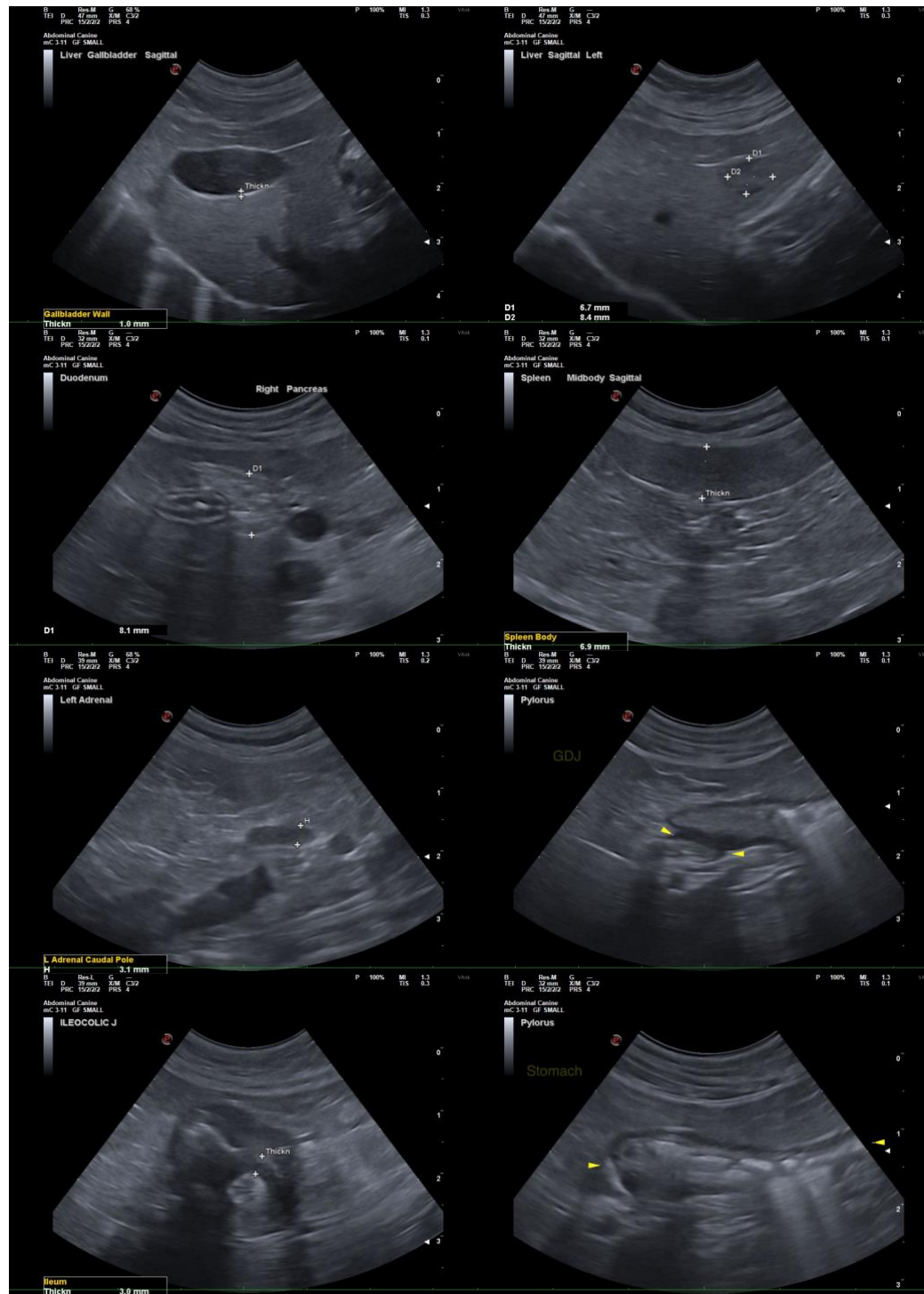
Dr. Ferrer DVM

HOSPITAL NAME

Paseos VC

REFERRING VET

Dr. Jenniffer Walker



INVOICE

10358

DATE

2/14/22

The information and recommendations provided are based on the images presented by the referring veterinarian/sonographer. No evaluation can be communicated regarding pathology that was not visible in the image/video clips provided.

Thank you for this referral. If the clinical or image interpretation does not parallel your findings or if I can be of any further assistance, please contact me.



PATIENT

Andrea Nicastro, DVM, Diplomate DACVIM (Small Animal Internal Medicine)
info@SonoPath.com

Cuko Vitola

SPECIES

Feline

BREED

DSH

SEX

Neutered Male

AGE

11 years

WEIGHT

10.2 lbs

INTERPRETED BY

Andrea Nicastro, DMV,
Diplomate DACVIM
(Small Animal
Internal Medicine)

**IMAGING
PERFORMED BY**

Dr. Ferrer DVM

HOSPITAL NAME

Paseos VC

REFERRING VET

Dr. Jenniffer Walker

INVOICE

10358

DATE

2/14/22