Charleston Mobile Veterinary Services
IN PARTNERSHIP WITH SONOPATH VETERINARY ULTRASOUND

SonoPath
FOSTERING THE ART OF VETERINARY MEDICINE™
www.charlestonmobile.net
info@charlestonmobile.net
800.403.5408

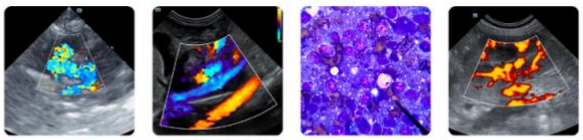

Clinical Sonography & Telecytology
Educational Teleconsultation Services™

PATIENT
Arnold Corthell

SPECIES
Canine

BREED
Labrador Retr

SEX
Neutered Male

AGE
1/15/2016

WEIGHT
57.6

INTERPRETED BY
Andrea Nicastro DVM
Diplomate ACVIM
(Sm Animal Internal Med)

IMAGING PERFORMED BY
Andrea Nicastro DVM
Diplomate ACVIM
(Sm Animal Internal Med)

HOSPITAL NAME
VC Myrtle Beach

REFERRING VET
Dr Boland

INVOICE
22550

DATE
2-13-26

PRESENTING CLINICAL SIGNS

Clinical Exam Findings:
- Chronic, intermittent vomiting for 1 yr.
- Recent increase over the past few weeks. Now vomiting 2-3 times weekly.
- Intermittent loose stools, diarrhea.

Abnormal lab-work values:
Glob 3.8, all other chems and CBC wnl
T4 = 1.3
PSL wnl
u/a: USG 1.040 - no significant findings
fecal: no ova or parasites noted, Giardia Elisa negative
Current Medications: Cerenia and Propectalin (started 2/10/26)
Radiographic Findings: None

ULTRASONOGRAPHIC EXAMINATION OF THE ABDOMEN

Urinary System
The urinary bladder wall is normal in thickness. The mucosal surface is smooth. The bladder is moderately distended. Luminal contents are anechoic. No cystic calculi are observed. The region of the trigone and the proximal urethra, visible to a depth of 3 cm, are normal.

The prostate is normal in size (0.98 cm in width) and shape. Parenchyma is homogenous. The prostatic urethra appears normal without evidence of dilation or obstruction.

The left kidney is normal in size (6.63 cm in length) with a normal shape, architecture and smooth peripheral margins. There is a normal 1:3 cortex to medulla ratio with minimal loss of corticomedullary distinction. There is no evidence of pyelectasia, nephroliths, infarcts or hydroureter. Renal vasculature is normal.

The right kidney is normal in size (6.50 cm in length) with a normal shape, architecture and smooth peripheral margins. There is a normal 1:3 cortex to medulla ratio with minimal loss of corticomedullary distinction. There is no evidence of pyelectasia, nephroliths, infarcts or hydroureter. Renal vasculature is normal.

Adrenal Glands
The left adrenal gland is subjectively normal in length (0.39 cm at cranial pole) (0.49 cm at caudal pole) with a slightly flattened contour. Glandular echogenicity and detail are normal. The phrenicoabdominal vein and surrounding vasculature are normal.

The right adrenal gland is normal in size (0.72 cm at cranial pole) (0.57 cm at caudal pole) with a normal shape and homogenous parenchyma. The glandular echogenicity and detail are unremarkable. Capsule, cortex, and medullary definition are normal. The phrenicoabdominal vein and surrounding vasculature are normal.

Spleen
The spleen is subjectively normal-in-size with a normal capsular contour. There is appropriate echogenicity and echotexture. No focal lesions are observed. Splenic vasculature is normal.

Liver
The liver is subjectively normal in size with normal contours and structure. There is appropriate echogenicity and echotexture. No overt structural evidence of inflammatory, infiltrative, or regenerative pathology is evident. Vascular and biliary tracts are of normal volume with no evidence of congestion. The

PATIENT
Arnold Corthell

SPECIES
Canine

BREED
Labrador Retr

SEX
Neutered Male

AGE
1/15/2016

WEIGHT
57.6

INTERPRETED BY
Andrea Nicastro DVM
Diplomate ACVIM
(Sm Animal Internal Med)

IMAGING PERFORMED BY
Andrea Nicastro DVM
Diplomate ACVIM
(Sm Animal Internal Med)

HOSPITAL NAME
VC Myrtle Beach

REFERRING VET
Dr Boland

INVOICE
22550

DATE
2-13-26

portal vein to caudal vena cava ratio is approximately 1: 1.

The gallbladder lumen is moderately distended. The wall is thin and smooth. Luminal contents are mostly anechoic. The cystic and common bile ducts are normal/not seen.

Gastrointestinal
The gastric lumen is not distended. The gastric wall and pylorus are normal in thickness with a normal layering pattern. The pyloric outflow tract is patent. The small intestinal lumen is not dilated. The small intestinal wall is normal in thickness with a normal layering pattern and appropriate mural detail. Discreet masses are not identified. The ileocecocolic junction and colonic wall are normal. There is no evidence of an obstructive pattern.

Pancreas
The region of the pancreas is isoechoic relative to surrounding omental fat. No obvious parenchymal abnormalities are observed. There is no evidence of regional inflammation or effusion (See also "Other" category).

Lymph Nodes
One-to-two prominent mesenteric lymph nodes are visualized (one measuring 1.2 x 0.83 cm). (See also "Other" category).

Free Abdomen
There is no obvious evidence of free fluid.

Other
In the cranial abdomen, a 1.39 x 1.19 cm cystic structure is visualized.
A brief echocardiogram reveals no evidence of pericardial effusion or obvious right atrial/auricular mass.

ULTRASONOGRAPHIC FINDINGS

- Cyst in the cranial abdomen, the origin of which is unclear. It may be arising from the mesentery, pancreas, other. Its significance is unclear. It likely represents a benign incidental finding. However, an emerging vascular tumor or abscess cannot be excluded.
- The slightly flattened left adrenal gland may be a normal variant for this patient or may be secondary to atrophy resulting from hypoadrenocorticism.
- The prominent abdominal lymph nodes are most consistent with reactive lymphadenitis or lymphoid hyperplasia. Neoplastic infiltration is considered less likely.

*An obvious cause for the patient's clinical signs is not definitively identified in this study. Considerations include a microscopic enteropathy (i.e., food allergy/intolerance, inflammatory bowel disease, infectious/parasitic disease), underlying metabolic issue, other.

INTERPRETATION OF THE FINDINGS & FURTHER RECOMMENDATIONS

- The following diagnostics/treatment recommendations can be considered:

  1. Texas GI panel including serum cobalamin, folate, PLI, TLI and resting cortisol level
  2. A fecal evaluation for ova/Giardia
  3. Prophylactic deworming with Fenbendazole.
  4. A 3-4-week hypoallergenic or hydrolyzed protein diet trial

PATIENT

Arnold Corthell

SPECIES

Canine

BREED

Labrador Retr

SEX

Neutered Male

AGE

1/15/2016

WEIGHT

57.6

INTERPRETED BY

Andrea Nicastro DVM
Diplomate ACVIM
(Sm Animal Internal Med)

IMAGING PERFORMED BY

Andrea Nicastro DVM
Diplomate ACVIM
(Sm Animal Internal Med)

HOSPITAL NAME

VC Myrtle Beach

REFERRING VET

Dr Boland

INVOICE

22550

DATE

2-13-26

5. Also consider initiating a probiotic with a high colony count +/- fiber supplement (i.e., psyllium).
6. Depending on the results of the above diagnostics/therapeutics, endoscopic or surgical gastrointestinal biopsies may be warranted.
7. Three-view thoracic radiographs should be performed prior to any anesthetic event.

- Regarding the cyst in the cranial abdomen, consider a recheck ultrasound in 2-3 months to assess for changes.

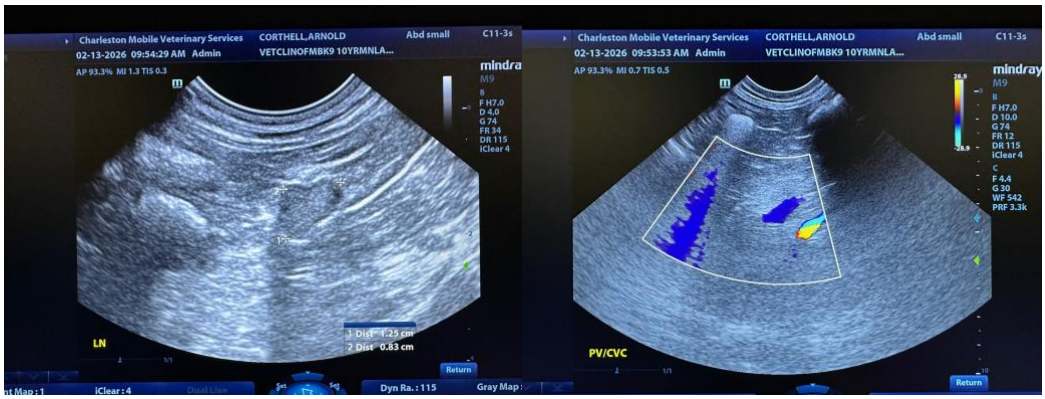

Charleston Mobile Veterinary Services
IN PARTNERSHIP WITH SONOPATH VETERINARY ULTRASOUND

SonoPath
FOSTERING THE ART OF VETERINARY MEDICINE™
www.charlestonmobile.net
info@charlestonmobile.net
800.403.5408

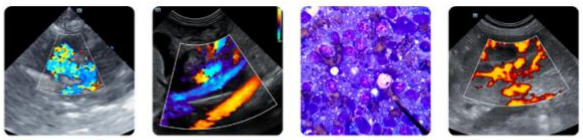

Clinical Sonography & Telecytology
Educational Teleconsultation Services™

PATIENT

Arnold Corthell

SPECIES

Canine

BREED

Labrador Retr

SEX

Neutered Male

AGE

1/15/2016

WEIGHT

57.6

INTERPRETED BY

Andrea Nicastro DVM
Diplomate ACVIM
(Sm Animal Internal Med)

IMAGING PERFORMED BY

Andrea Nicastro DVM
Diplomate ACVIM
(Sm Animal Internal Med)

HOSPITAL NAME

VC Myrtle Beach

REFERRING VET

Dr Boland

INVOICE

22550

DATE

2-13-26

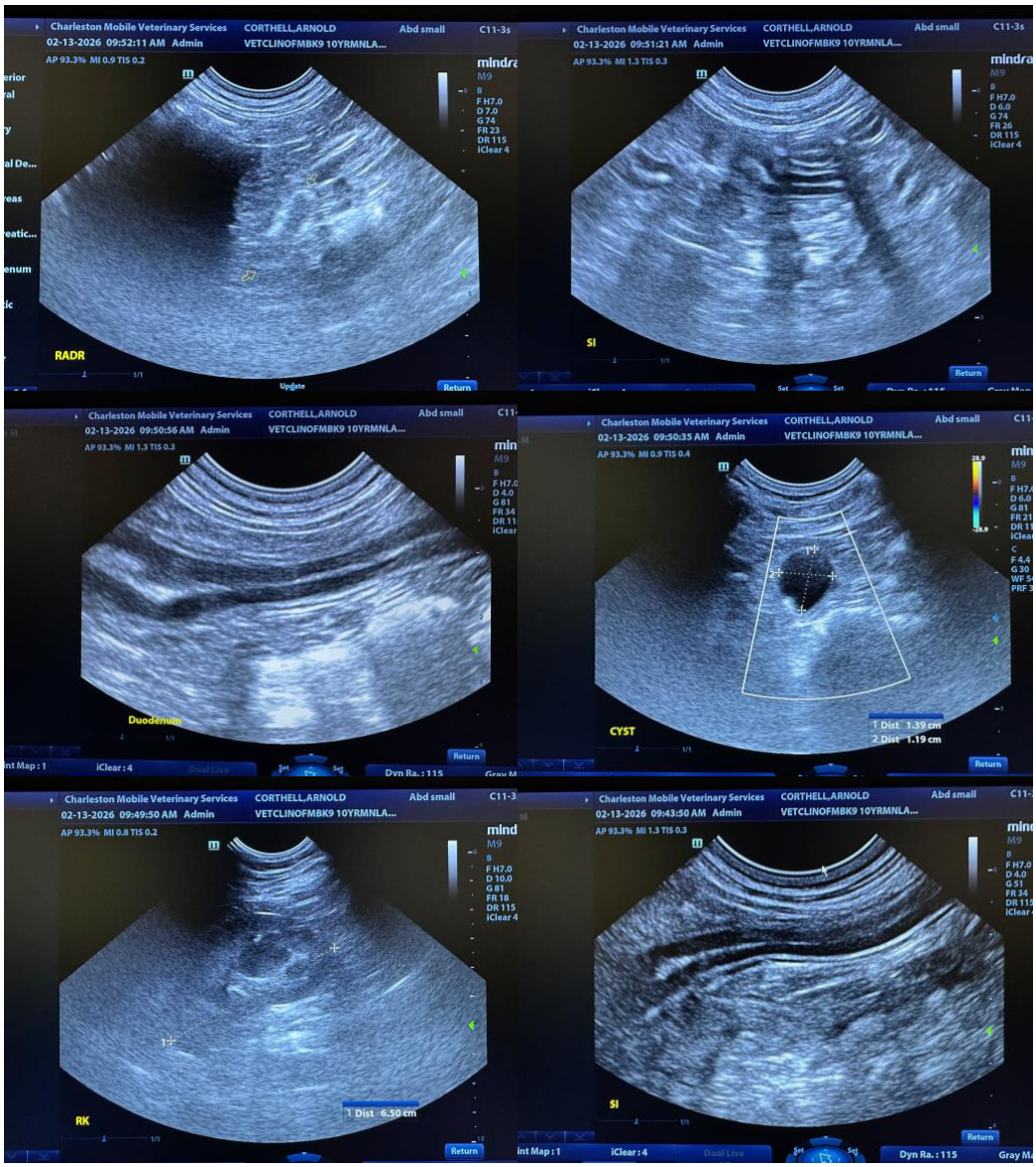

Charleston Mobile Veterinary Services
IN PARTNERSHIP WITH SONOPATH VETERINARY ULTRASOUND

SonoPath
FOSTERING THE ART OF VETERINARY MEDICINE™
www.charlestonmobile.net
info@charlestonmobile.net
800.403.5408

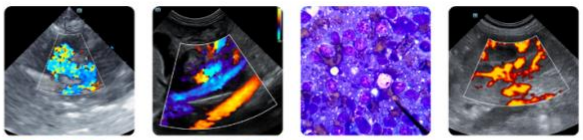

Clinical Sonography & Telecytology
Educational Teleconsultation Services™

PATIENT

Arnold Corthell

SPECIES

Canine

BREED

Labrador Retr

SEX

Neutered Male

AGE

1/15/2016

WEIGHT

57.6

INTERPRETED BY

Andrea Nicastro DVM
Diplomate ACVIM
(Sm Animal Internal Med)

IMAGING PERFORMED BY

Andrea Nicastro DVM
Diplomate ACVIM
(Sm Animal Internal Med)

HOSPITAL NAME

VC Myrtle Beach

REFERRING VET

Dr Boland

INVOICE

22550

DATE

2-13-26

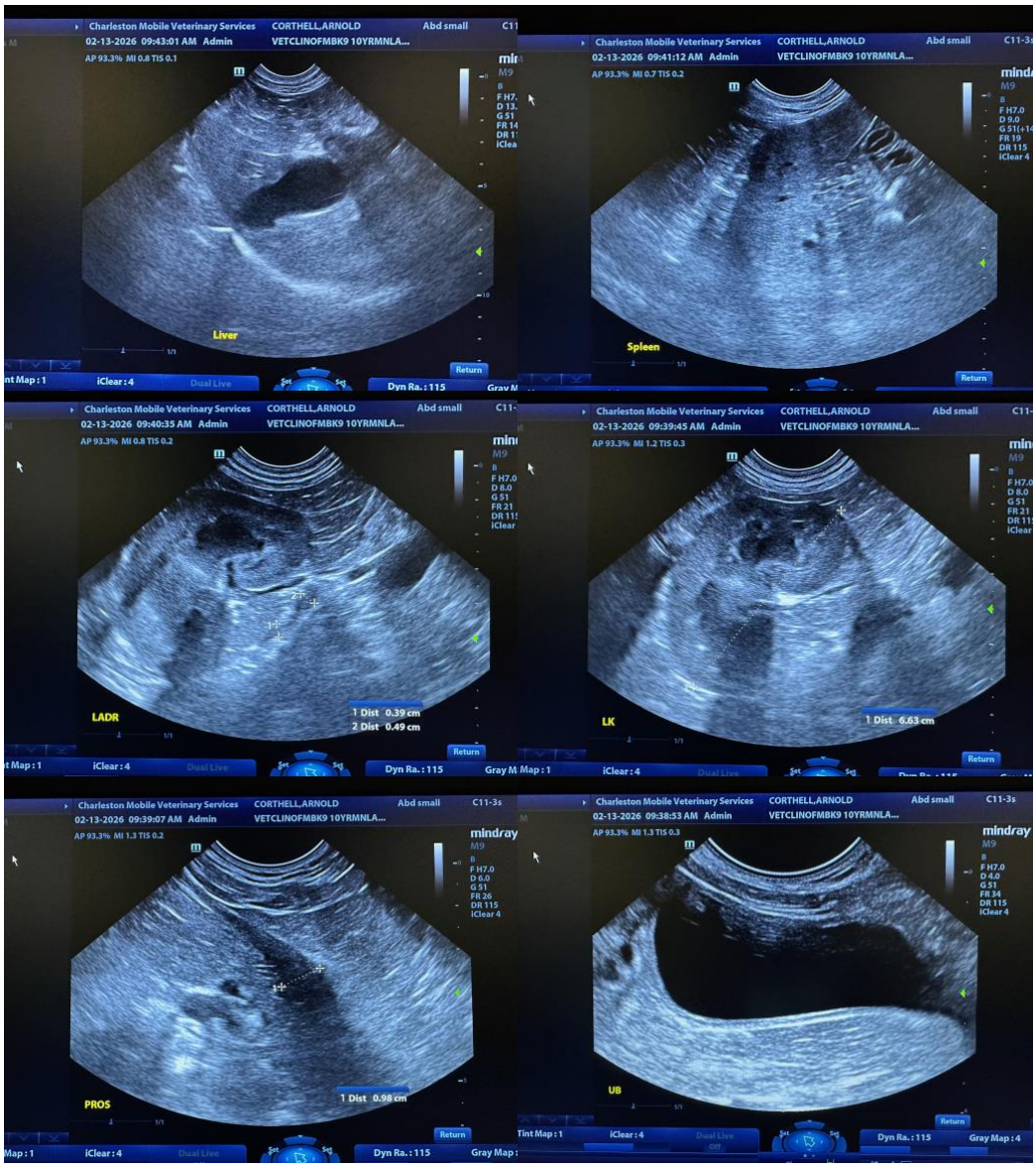

The information and recommendations provided are based on the images presented by the referring veterinarian/sonographer. No evaluation can be communicated regarding pathology that was not visible in the image/video clips provided.

Thank you for this referral. If the clinical or image interpretation does not parallel your findings or if I can be of any further assistance, please contact me.

Andrea Nicastro, MPH, DVM, Diplomate DACVIM (Small Animal Internal Medicine)
info@SonoPath.com