



PATIENT

Baxter Shannon

PRESENTING CLINICAL SIGNS

Recent straining to urinate and defecate, blood in the urine.

SPECIES

Canine

ULTRASONOGRAPHIC EXAMINATION OF THE ABDOMEN

Urinary System

The urinary bladder wall is mildly distended. The wall is diffusely thickened (up to 1.38 cm) with a 1.03 x 1.38 cm mass effect in the region of the trigone. The mass contains focus of mineralization. Focus of mineralization are also observed along the dorsal apical aspect. The mucosal surface is irregular. A small amount of echogenic debris is observed within the lumen. The proximal urethra is thickened (up to 1.11 cm in diameter). The proximal urethral lumen is not overtly dilated.

BREED

WHT

SEX

NM

The prostate is enlarged (1.96 cm in width), with a mass effect and smooth curvilinear peripheral contours. The parenchyma is heterogenous with ill-defined hyperechoic-to-mineralized foci within the parenchyma. The prostatic urethra is not overtly dilated.

AGE

14 years

The left kidney is normal in size (4.86 cm in length) with a normal shape, smooth peripheral margins, and normal internal architecture. There is mild loss of corticomedullary distinction. Several hyperechoic shadowing diverticular foci are observed. There is no evidence of pyelectasia, infarcts or hydronephrosis. Renal vasculature is normal.

WEIGHT

NP

The right kidney is normal in size (4.97 cm in length) with a normal shape, architecture and smooth peripheral margins. There is a normal 1:3 cortex to medulla ratio with minimal to mild loss of corticomedullary distinction. There is no evidence of pyelectasia, nephroliths, infarcts or hydronephrosis. Renal vasculature is normal.

INTERPRETED BY

Andrea Nicastro, DVM,
Diplomate ACVIM (*Small
Animal Internal Medicine*)

**IMAGING
PERFORMED BY**

Andrea Nicastro, DVM,
Diplomate ACVIM (*Small
Animal Internal Medicine*)

HOSPITAL NAME

Trinity Island VC

REFERRING VET

Kristi Oldham

Adrenal Glands

The left adrenal gland is normal in size (0.54 cm at cranial pole) (.051 cm at caudal pole) with a normal shape and homogenous parenchyma. The glandular echogenicity and detail are unremarkable. Capsule, cortex, and medullary definition are normal. The phrenicoabdominal vein and surrounding vasculature are normal.

The right adrenal gland is in normal size (1.03 cm at cranial pole) (0.53 cm at caudal pole) with a normal shape and homogenous parenchyma. The glandular echogenicity and detail are unremarkable. Capsule, cortex, and medullary definition are normal. The phrenicoabdominal vein and surrounding vasculature are normal.

Spleen

The spleen is normal in size (1.04 cm in width at the level of the hilus) with a normal capsular contour. There is appropriate echogenicity and echotexture. No focal lesions are observed. Splenic vasculature is normal.

Liver

The liver is subjectively normal in size with normal curvilinear peripheral contours. The parenchyma is hypoechoic relative to the spleen with minor changes consistent with age-related remodeling. No focal lesions are observed. Hepatic vasculature and biliary tracts are of normal volume with no evidence of congestion. The portal vein to caudal vena cava ratio is approximately 1: 1.

INVOICE

12215

DATE

2.13.23

The gall bladder lumen is moderately distended. The wall is thin and smooth. Luminal contents are anechoic. The cystic and common bile ducts are normal/not seen.

Gastrointestinal

The stomach and intestine are free of stasis and exhibit normal peristaltic activity. The gastric lumen is not distended. The gastric wall and pylorus are normal in thickness with a normal layering pattern. The pyloric outflow tract is patent. The small intestinal lumen is not dilated. The small intestinal wall thickness is normal with a normal layering pattern and appropriate mural detail. Discreet masses are not identified. The colonic wall is normal. There is no evidence of an obstructive pattern.

Pancreas

The right limb of the pancreas is normal in size with normal curvilinear peripheral contours. The parenchyma is largely isoechoic relative to surrounding omental fat and slightly mottled in appearance. The pancreatic duct is visible but not overtly dilated. There is no evidence of peripancreatic inflammation or effusion.

Free Abdomen

There is no obvious evidence free fluid. The abdominal lymph nodes are normal/not visible.

Other

A brief echocardiogram reveals no evidence of pericardial effusion or obvious right atrial/auricular mass.

ULTRASONOGRAPHIC FINDINGS

Primary Findings

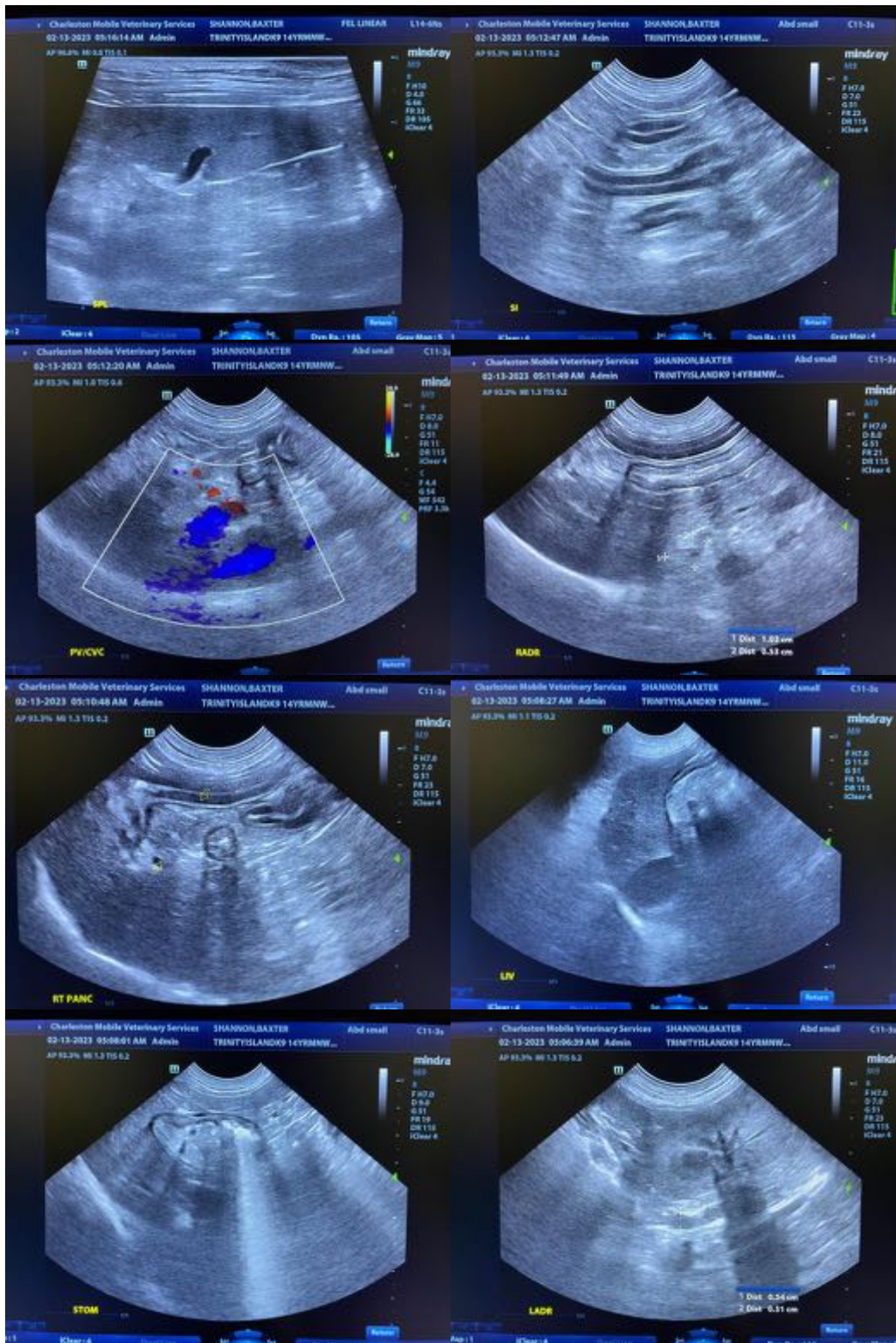
- Urinary bladder mass in the region of the trigone with extension into the proximal urethra and prostate. Neoplasia (i.e., transitional cell carcinoma, prostatic adenocarcinoma) is suspected with a lower possibility of an inflammatory process.

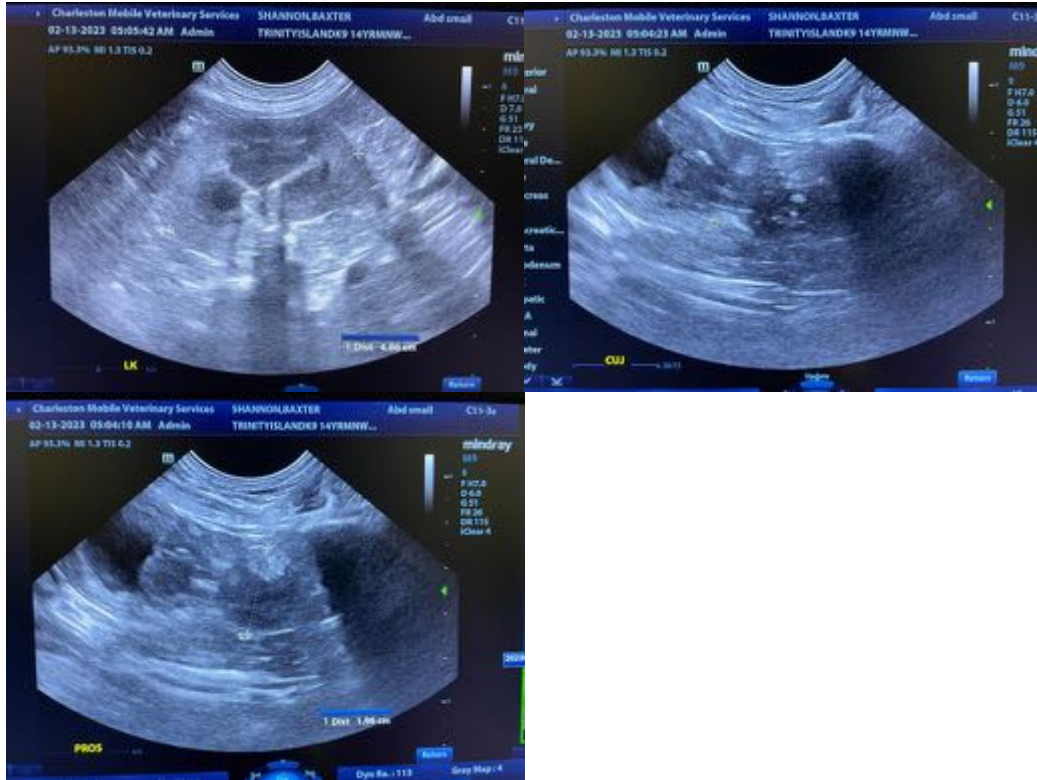
Secondary Findings

- Mild bilateral age-related renal changes
- The pancreatic changes are most consistent with age-related parenchymal remodeling, potentially secondary to a prior inflammatory episode, early fibrosis or chronic pancreatitis.
- The hepatic changes are consistent with age-related parenchymal remodeling and are not considered clinically significant at this time.

INTERPRETATION OF THE FINDINGS & FURTHER RECOMMENDATIONS

- A urine BRAF test can be considered to confirm lower urinary tract neoplasia.
- Thoracic radiographs can also be considered to evaluate for pulmonary metastatic disease.
- Consider initiation of piroxicam (0.3 mg/kg PO q 24hr) along with a stomach protectant (i.e., misoprostol; 2 mcg/kg PO q 12 hr), if further diagnostics (i.e., biopsies) are not to be pursued.
- If aggressive treatment is desired, consider consultation with a board-certified oncologist.





The information and recommendations provided are based on the images presented by the referring veterinarian/sonographer. No evaluation can be communicated regarding pathology that was not visible in the image/video clips provided.

Thank you for this referral. If the clinical or image interpretation does not parallel your findings or if I can be of any further assistance, please contact me.

Andrea Nicastro, MPH, DVM, Diplomate DACVIM (Small Animal Internal Medicine)
info@SonoPath.com