



PATIENT PRESENTING CLINICAL SIGNS

Kitty Christiaen History: Looking for cause for inappetence. No meds.

SPECIES ULTRASONOGRAPHIC EXAMINATION OF THE ABDOMEN

Feline

Urinary System

The urinary bladder, trigone, and pelvic urethra are normal in thickness and the mucosal surface is smooth. The bladder is moderately distended. A scant amount of suspended echogenic debris is observed within the lumen. No masses, inflammatory changes or calculi are observed. Ureteral papillae and visualized portion of the proximal urethra, visible to a depth of 1 cm, are normal.

BREED

DSH

SEX

Spayed Female

The left kidney is normal size (3.71 cm in length); normal shape and architecture with smooth peripheral margins. There is a normal 1:3 cortex to medulla ratio with normal corticomedullary distinction. There is no evidence of pyelectasia, nephroliths, infarcts or hydroureter. Renal vasculature is normal.

AGE

10 years

The right kidney is normal size (4.15 cm in length); normal shape and architecture with smooth peripheral margins. There is a normal 1:3 cortex to medulla ratio with minimal to mild loss of corticomedullary distinction. There is no evidence of pyelectasia, nephroliths, infarcts or hydroureter. Renal vasculature is normal.

WEIGHT

12.4 lbs

Adrenal Glands

The left adrenal gland is normal size (0.33 cm width). Normal shape and glandular echogenicity. The phrenicoabdominal vein and surrounding vasculature are normal.

INTERPRETED BY

The region of the right adrenal gland is evaluated. No obvious pathology is observed.

Andrea Nicaastro,
DVM, Diplomate ACVIM
(Small Animal Internal
Medicine)

Spleen

The spleen is normal in size (0.84 cm in width at the level of the hilus) with a normal capsular contour. There is appropriate echogenicity and echotexture. No focal lesions are observed. Splenic vasculature is normal.

IMAGING PERFORMED BY

Crystal Hill

Liver

The liver is enlarged with swollen irregular peripheral contours. The parenchyma is diffusely mottled and nodular in appearance. A 3.99 cm mass effect is observed in the right lateral lobe. Hepatic vasculature is of normal volume with no evidence of congestion.

HOSPITAL NAME

Norwich VC

The gall bladder lumen is moderately distended. The wall is thin and smooth. Luminal contents are anechoic. The cystic and common bile ducts are normal.

REFERRING VET

Dr. Saturno

Gastrointestinal

The stomach and intestine are free of stasis and exhibit normal peristaltic activity. The gastric lumen is not distended. The gastric wall and pylorus are normal in thickness with a normal layering pattern. The pyloric outflow tract is patent. The small intestinal lumen is not dilated. The small intestinal wall thickness is normal with a normal layering pattern and appropriate mural detail. Discreet masses are not identified. The colonic wall is normal. No obstructive disease is noted.

INVOICE

10328

Pancreas

The base is visible/prominent with normal curvilinear peripheral contours. The parenchyma hypoechoic relative to surrounding omental fat. No distinct focal lesions are observed. The pancreatic duct is not overtly dilated.

DATE

2/11/22



PATIENT

Kitty Christiaen

Free Abdomen

A small to moderate amount of free fluid is present within the abdomen. The mesentery throughout the abdomen is hyperechoic.

SPECIES

Feline

Lymph Nodes

(see "Other" category)

BREED

DSH

Other

An approximately 3.00 cm irregular hypoechoic mass effect is observed in the cranial abdomen, just caudal to the stomach. A few small irregular hypoechoic nodules are observed within the mesentery in the left cranial quadrant.

SEX

Spayed Female

ULTRASONOGRAPHIC FINDINGS

Primary Findings

- The hepatic changes are most consistent with infiltrative neoplasia. Differentials include carcinomatosis, round cell neoplasia, other.
- The origin of the mass effect in the cranial abdomen is unclear. It may be arising from liver, pancreas, mesentery, other
- The hypoechoic nodules in the cranial mesentery may represent metastatic lesions or prominent lymph nodes.
- Diffuse peritonitis is present, likely secondary to hepatic pathology.

AGE

10 years

WEIGHT

12.4 lbs

Secondary Findings

- The pancreatic changes may be a normal variant for this patient or could be consistent with mild, chronic pancreatitis. Correlation with clinical findings is recommended.
- Bilateral age-relate renal changes

INTERPRETED BY

Andrea Nicastro,
DVM, Diplomate ACVIM
(Small Animal Internal
Medicine)

IMAGING PERFORMED BY

Crystal Hill

INTERPRETATION OF THE FINDINGS & FURTHER RECOMMENDATIONS

HOSPITAL NAME

Norwich VC

- Three-view thoracic radiographs are recommended to assess for pulmonary metastases.
- Consider a fine-needle aspirate of the liver as well as cytology on the abdominal fluid (if clotting status is appropriate). Unfortunately, however, given the severity of the abdominal pathology, the prognosis is considered guarded and palliative care should be considered.

REFERRING VET

Dr. Saturno

INVOICE

10328

DATE

2/11/22



PATIENT

Kitty Christiaen

SPECIES

Feline

BREED

DSH

SEX

Spayed Female

AGE

10 years

WEIGHT

12.4 lbs

INTERPRETED BY

Andrea Nicaastro,
DVM, Diplomate ACVIM
(Small Animal Internal
Medicine)

**IMAGING
PERFORMED BY**

Crystal Hill

HOSPITAL NAME

Norwich VC

REFERRING VET

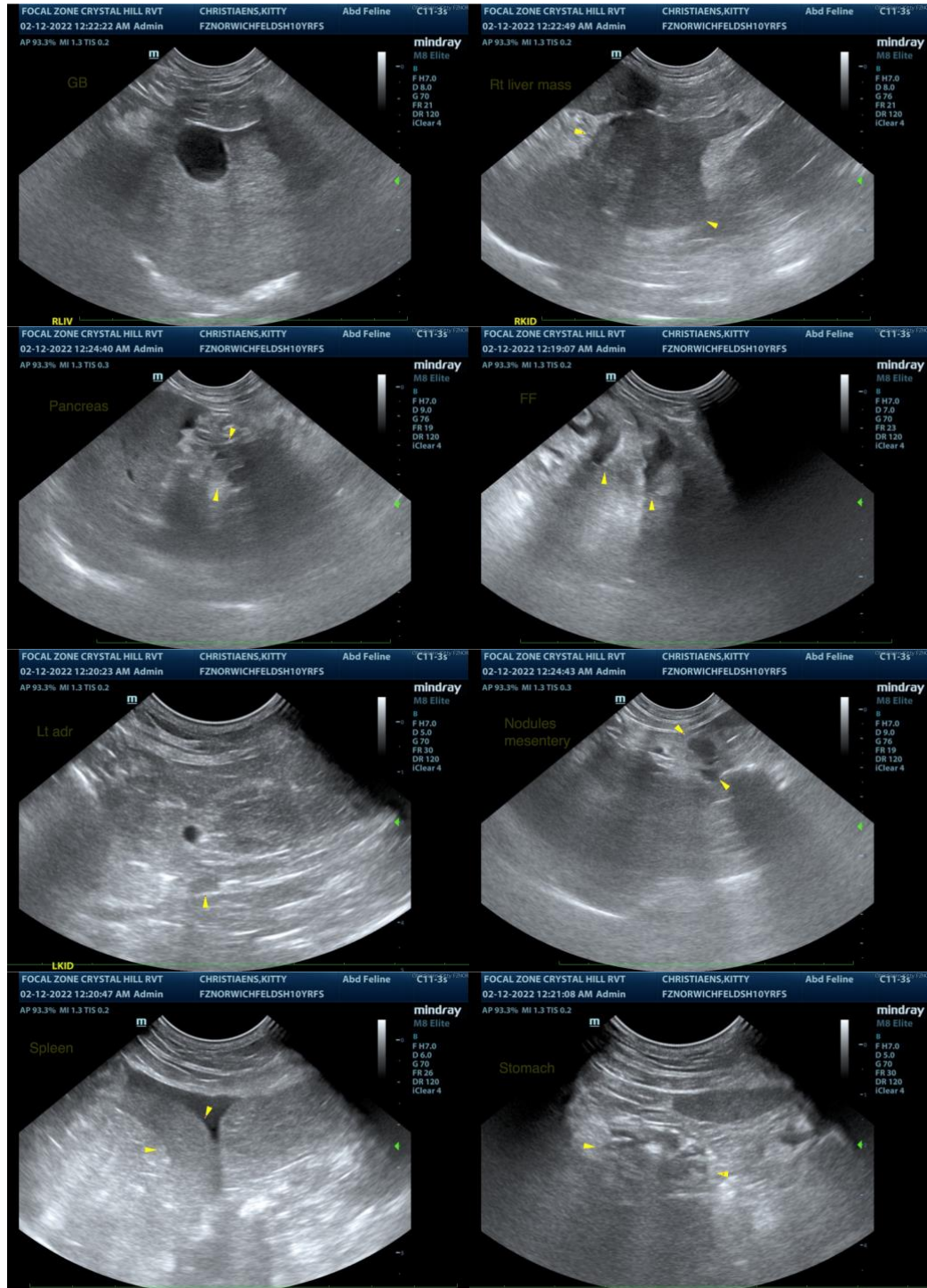
Dr. Saturno

INVOICE

10328

DATE

2/11/22





PATIENT

Kitty Christiaen

SPECIES

Feline

BREED

DSH

SEX

Spayed Female

AGE

10 years

WEIGHT

12.4 lbs

INTERPRETED BY

Andrea Nicastro,
DVM, Diplomate ACVIM
(Small Animal Internal
Medicine)

**IMAGING
PERFORMED BY**

Crystal Hill

HOSPITAL NAME

Norwich VC

REFERRING VET

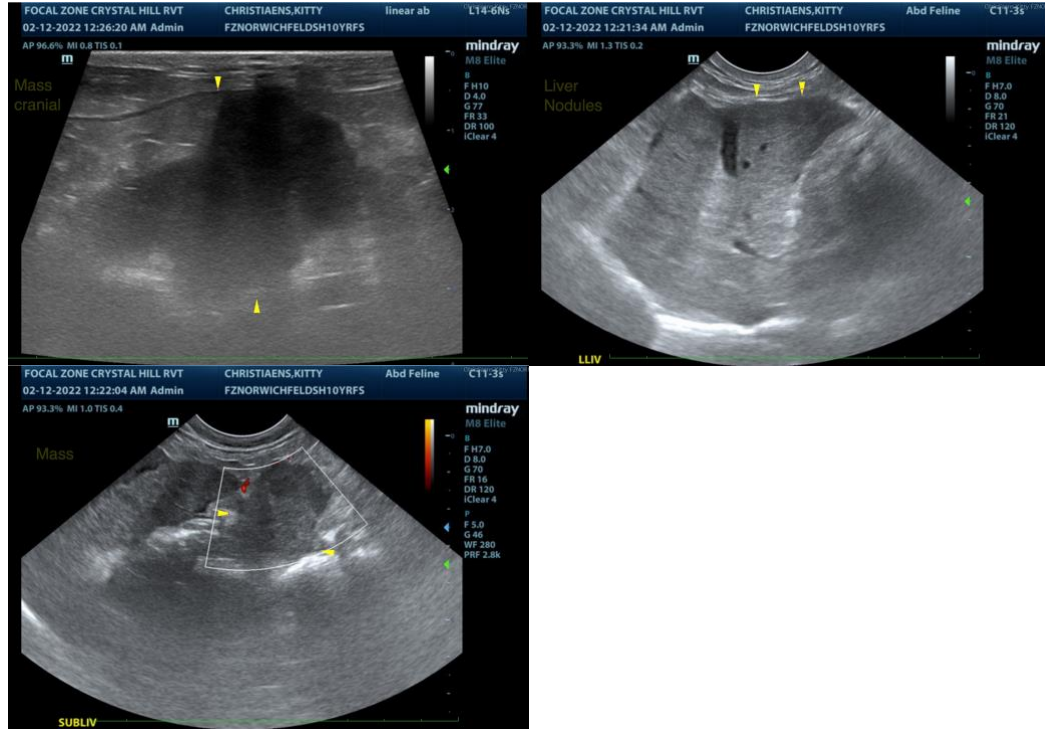
Dr. Saturno

INVOICE

10328

DATE

2/11/22



The information and recommendations provided are based on the images presented by the referring veterinarian/sonographer. No evaluation can be communicated regarding pathology that was not visible in the image/video clips provided.

Thank you for this referral. If the clinical or image interpretation does not parallel your findings or if I can be of any further assistance, please contact me.

Andrea Nicastro, DVM, Diplomate DACVIM (Small Animal Internal Medicine)
info@SonoPath.com