



PATIENT

Hayden Saenz

SPECIES

Canine

BREED

Beagle mix

SEX

Male, neutered

AGE

11 Yrs. 3 months

WEIGHT

40.6 lbs.

INTERPRETED BY

Andrea Nicastro, DVM,
Diplomate ACVIM
(Small Animal Internal
Medicine)

IMAGING PERFORMED BY

Dr. Sookhoo

HOSPITAL NAME

Calusa VC

REFERRING VET

Dr. Glotzer

INVOICE

13468

DATE

2/10/26

PRESENTING CLINICAL SIGNS

History: VOMITING AND HEMATOCHIEA. VOMITING STARTED THIS MORNING. P HAD VOMITED EIGHT TIMES. HEMATOCHIEA STARTED THIS MORNING AS WELL. P HAS BEEN HAVING STRAIGHT LIQUID HEMATOCHIEA. MULTIPLE TIMES HIS MORNING. O FEEDS A DIET OF COOKED VEGGIES, CHICKEN BREAST, TUMRIC, AND GINGER. P ALSO GETS METABOLIC TREATS. PER O P HAS NOT BEE FED ANYTHING NEW. NO NEW TREATS. P TAKES VETMEDIN 1/2 TABLET TWICE DAILY. P HAS NOT GOTTEN MEDICATION THIS MORNING. MEDICAL HISTORY OF COLITIS.

Abnormal PE/Chem/CBC/UA Results: CPL suspect pancreatitis 259ng/mL, PCV 55% TS 8 g/dL, Has Grade III-IV/VI heart murmur

ULTRASONOGRAPHIC EXAMINATION OF THE ABDOMEN

Urinary System

The urinary bladder is mildly distended with mostly anechoic urine. The wall is diffusely thickened (up to 0.58 cm) with a slightly irregular mucosal surface. No cystic calculi are observed. The region of the trigone is normal.

The left kidney is normal in size (6.29 cm in length) with a normal shape, architecture and smooth peripheral margins. There is a normal 1:3 cortex to medulla ratio with mild loss of corticomedullary distinction. There is no evidence of pyelectasia, nephroliths, infarcts or hydroureter. Renal vasculature is normal.

The right kidney is normal in size (6.78 cm in length) with a normal shape, architecture and smooth peripheral margins. There is a normal 1:3 cortex to medulla ratio with mild loss of corticomedullary distinction. At least one small cortical cyst is seen. There is no evidence of pyelectasia, nephroliths, infarcts or hydroureter. Renal vasculature is normal.

Adrenal Glands

The left adrenal gland is normal in size at the cranial pole and mildly enlarged at the caudal pole (0.51 cm at cranial pole) (0.75 cm at caudal pole). The glandular echogenicity and detail are unremarkable. The phrenicoabdominal vein and surrounding vasculature are normal.

The right adrenal gland is normal in size (0.71 cm at cranial pole) (0.57 cm at caudal pole) with a normal shape and homogenous parenchyma. The glandular echogenicity and detail are unremarkable. Capsule, cortex, and medullary definition are normal. The phrenicoabdominal vein and surrounding vasculature are normal.

Spleen

A 3.9 x 3.8 cm isoechoic to slightly heterogeneous, expansile mass is observed at the cranial aspect. In addition, a 1.5 x 1.0 cm hypoechoic nodule is observed at the mid to caudal aspect. The remaining parenchyma is relatively homogeneous in appearance. Splenic vasculature is normal with no evidence of thrombosis.

Liver

The liver is subjectively enlarged with slightly swollen peripheral contours. The parenchyma is isoechoic relative to the spleen and diffusely homogeneous in appearance. No distinct focal lesions are observed. Vascular and biliary tracts are of normal volume with no evidence of congestion.

The gall bladder lumen is moderately distended. The wall is thin and smooth. A small to moderate amount of gravity-dependent echogenic to mineralized debris/sand is observed within the lumen. The cystic and common bile ducts are normal/not seen.



PATIENT

Hayden Saenz

SPECIES

Canine

BREED

Beagle mix

SEX

Male, neutered

AGE

11 Yrs. 3 months

WEIGHT

40.6 lbs.

INTERPRETED BY

Andrea Nicastro, DVM,
Diplomate ACVIM
(Small Animal Internal
Medicine)

IMAGING PERFORMED BY

Dr. Sookhoo

HOSPITAL NAME

Calusa VC

REFERRING VET

Dr. Glotzer

INVOICE

13468

DATE

2/10/26

Gastrointestinal

The gastric lumen is not distended. The gastric wall and pylorus are normal in thickness with a normal layering pattern. The pyloric outflow tract is patent. The small intestinal lumen is segmentally distended with food and gas (mild). A few small intestinal segments are slightly plicated in appearance. The small intestinal wall is normal to borderline thickened (up to 0.42 cm). There is retention of the normal layering pattern. In some regions, there is evidence of mucosal striations. Discreet masses are not identified. The colonic wall is normal. There is no obvious evidence of an obstructive pattern.

Pancreas

The region of the pancreas is isoechoic relative to surrounding omental fat. No obvious parenchymal abnormalities are observed. There is no evidence of regional inflammation or effusion.

Lymph nodes

A few prominent mesenteric lymph nodes are visualized, one of the nodes measuring 0.77 x 0.61 cm. Surrounding mesentery is slightly hyperechoic.

Free Abdomen

There is no obvious evidence of free fluid.

ULTRASONOGRAPHIC FINDINGS

Primary Findings:

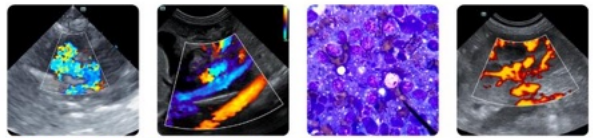
- Splenic mass. Neoplasia (i.e., round cell tumor, sarcoma) is suspected with a lower possibility of a non-neoplastic process (i.e., focus of lymphoid hyperplasia or similar). The smaller splenic nodule could be consistent with a metastatic lesion, emerging primary splenic tumor, benign focus, other.
- The intestinal changes are most consistent with enteritis. The mucosal striations could be consistent with lymphangiectasia and/or an inflammatory process.

Secondary Findings:

- Mild bilateral nonspecific, age-related renal changes
- The diffuse hepatic changes are most consistent with vacuolar hepatopathy (i.e., endocrine, idiopathic) with a lower possibility of inflammatory disease, infiltrative neoplasia, or other hepatopathy.
- Gallbladder debris/sand, non-mucocele
- The urinary bladder wall changes could be consistent with cystitis or may be artifactual due to lack of full repletion. Correlation with the patient's clinical history and urinalysis findings is recommended.
- The prominent abdominal lymph nodes are most consistent with reactive lymphadenitis or lymphoid hyperplasia. Neoplastic infiltration is considered less likely.
- Mild left adrenomegaly

INTERPRETATION OF THE FINDINGS & FURTHER RECOMMENDATIONS

- Regarding the splenic mass, consider the following:
 1. Three-view thoracic radiographs are recommended to assess for pulmonary metastases.



PATIENT

Hayden Saenz

SPECIES

Canine

BREED

Beagle mix

SEX

Male, neutered

AGE

11 Yrs. 3 months

WEIGHT

40.6 lbs.

INTERPRETED BY

Andrea Nicastro, DVM,
Diplomate ACVIM
(*Small Animal Internal
Medicine*)

IMAGING PERFORMED BY

Dr. Sookhoo

HOSPITAL NAME

Calusa VC

REFERRING VET

Dr. Glotzer

INVOICE

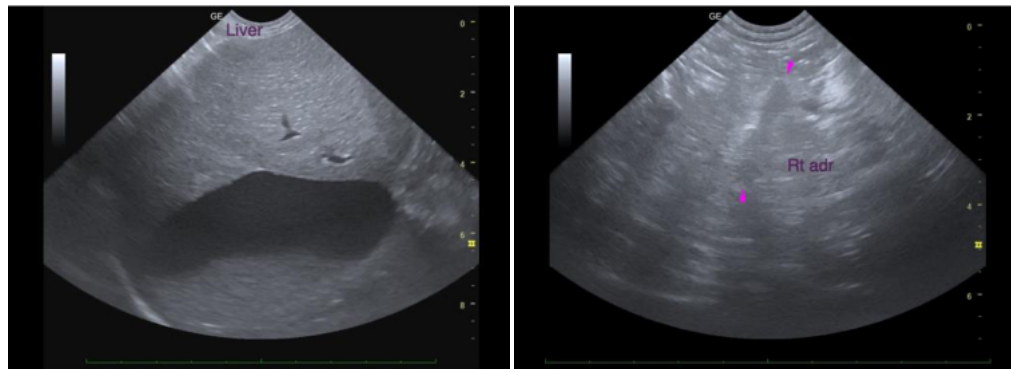
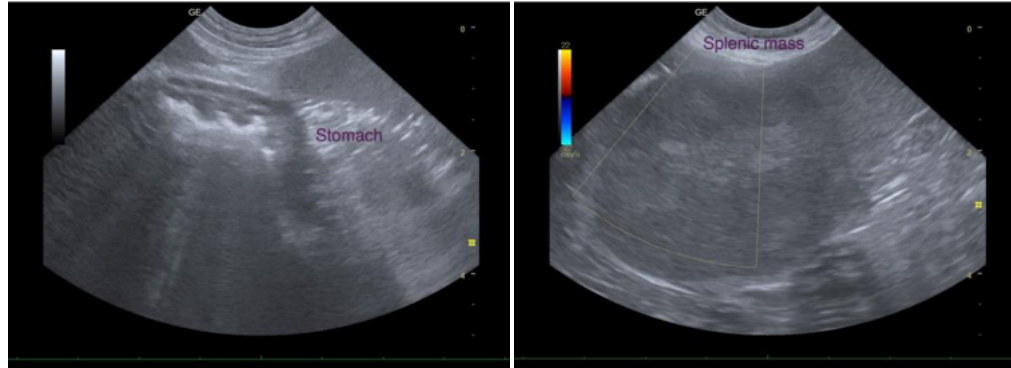
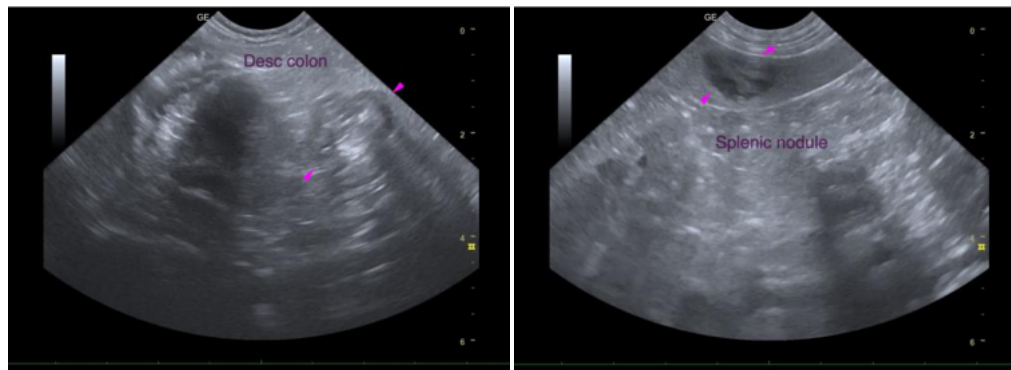
13468

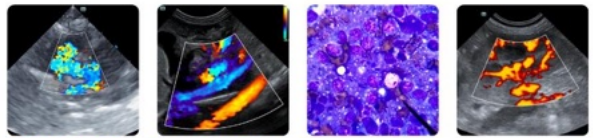
DATE

2/10/26

2. Fine needle aspiration (assuming normal clotting status). A 25-gauge needle should be used. If cytology results are inconclusive, consider a splenectomy with submission of the spleen for histopathology. Liver biopsies should also be obtained at the time of surgery to assess for micrometastatic disease.

- Regarding the patient's clinical signs, consider a fecal evaluation for ova and Giardia along with prophylactic deworming with fenbendazole.
- Supportive care for acute hemorrhagic gastroenteritis/colitis is recommended. If clinical signs persist, despite medical management, further GI workup may be indicated.





PATIENT

Hayden Saenz

SPECIES

Canine

BREED

Beagle mix

SEX

Male, neutered

AGE

11 Yrs. 3 months

WEIGHT

40.6 lbs.

INTERPRETED BY

Andrea Nicastro, DVM,
Diplomate ACVIM
(Small Animal Internal
Medicine)

IMAGING PERFORMED BY

Dr. Sookhoo

HOSPITAL NAME

Calusa VC

REFERRING VET

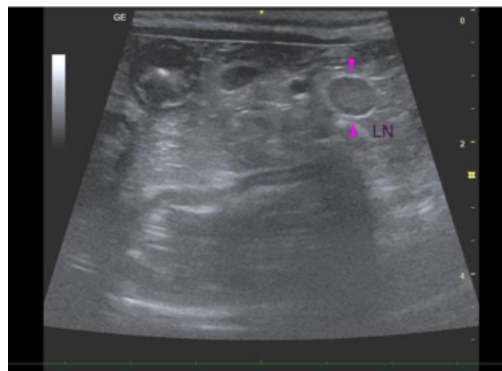
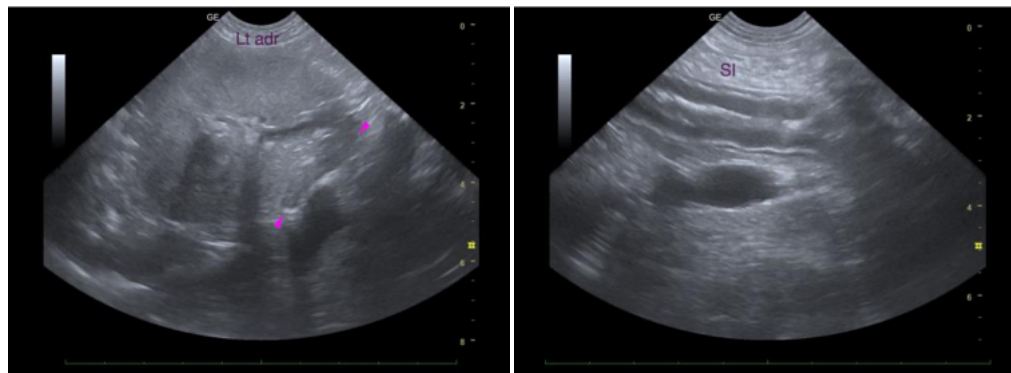
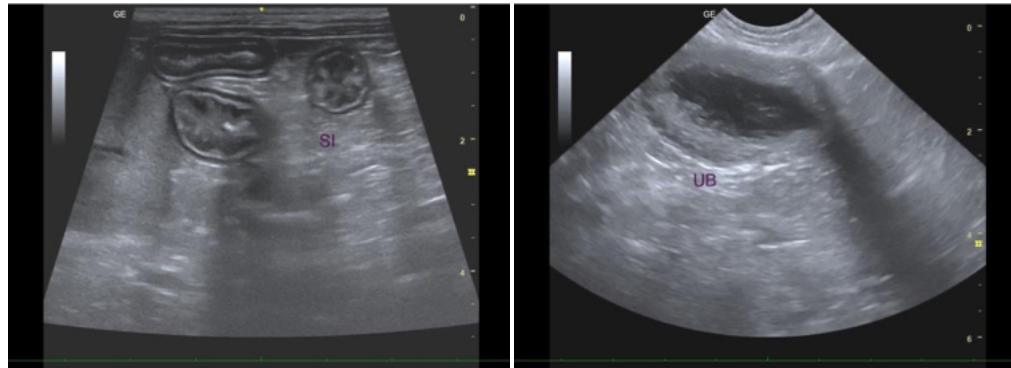
Dr. Glotzer

INVOICE

13468

DATE

2/10/26



The information and recommendations provided are based on the images presented by the referring veterinarian/sonographer. No evaluation can be communicated regarding pathology that was not visible in the image/video clips provided.

Thank you for this referral. If the clinical or image interpretation does not parallel your findings or if I can be of any further assistance please contact me.

Andrea Nicastro, MPH, DVM, Diplomate DACVIM (Small Animal Internal Medicine)
info@SonoPath.com