



PATIENT PRESENTING CLINICAL SIGNS

Karra Gartner
History: Presented yesterday for acute diarrhea with blood but was still energetic and eating well at that time. This morning appetite she is refusing food and less energetic, vomited. Got into a Peace Lily plant and 10 days ago and vomited acutely afterwards, but that resolved completely. Patient has been on a raw food diet her whole life. Started on IV fluids 2 hours prior to ultrasound, sedated with torb and low dose (3 mcg/kg) of dexmedetomidine for ultrasound.

SPECIES

Canine

BREED

Shepherd Poodle Mix

SEX

Intact Female

AGE

7.5 years

WEIGHT

14.5 kg/32 lbs

Abnormal PE/Chem/CBC/UA Results: CBC/Biochem/UA unremarkable except for dilute urine (after 2 hours on fluids, bladder too small to collect prior). Fecal negative.

ULTRASONOGRAPHIC EXAMINATION OF THE ABDOMEN

Urinary System

The urinary bladder wall is normal in thickness and the mucosal surface is smooth. The bladder is moderately distended. A scant amount of echogenic debris is observed within the lumen. No masses, inflammatory changes or calculi are observed. Ureteral papillae and visualized portion of the proximal urethra, visible to a depth of 2 cm, are normal.

The left kidney is normal in size (4.34 cm in length) with a normal shape, architecture and smooth peripheral margins. There is a normal 1:3 cortex to medulla ratio with minimal loss of corticomedullary distinction. There is no evidence of pyelectasia, nephroliths, infarcts or hydroureter. Renal vasculature is normal.

The right kidney is normal in size (5.08 cm in length) with a normal shape, architecture and smooth peripheral margins. There is a normal 1:3 cortex to medulla ratio with minimal loss of corticomedullary distinction. There is no evidence of pyelectasia, nephroliths, infarcts or hydroureter. Renal vasculature is normal.

Adrenal Glands

The left adrenal gland is normal in size (0.54 cm at cranial pole) (0.48 cm at caudal pole) with a normal shape and homogenous parenchyma. The glandular echogenicity and detail are unremarkable. Capsule, cortex, and medullary definition are normal. The phrenicoabdominal vein and surrounding vasculature are normal.

The right adrenal gland is in normal size (0.89 cm at cranial pole) (0.54 cm at caudal pole) with a normal shape and homogenous parenchyma. The glandular echogenicity and detail are unremarkable. Capsule, cortex, and medullary definition are normal. The phrenicoabdominal vein and surrounding vasculature are normal.

Spleen

The spleen is normal in size (1.88 cm in width at the level of the hilus) with a normal capsular contour. There is appropriate echogenicity and echotexture. No focal lesions are observed. Splenic vasculature is normal.

Liver

The liver is subjectively normal in size with normal contours and structure. There is appropriate echogenicity and echotexture. No overt structural evidence of inflammatory, infiltrative, or regenerative pathology is evident. Vascular and biliary tracts are of normal volume with no evidence of congestion. No pathological hepatic lymphadenopathy observed.

INTERPRETED BY

Andrea Nicastro, DVM,
Diplomate ACVIM (*Small Animal Internal Medicine*)

IMAGING PERFORMED BY

Elyse Hauer

HOSPITAL NAME

Mariposa VH

REFERRING VET

Elyse Hauer

INVOICE

12207

DATE

2.10.23

The gall bladder lumen is moderately distended. The wall is thin and smooth. Luminal contents are anechoic. The cystic and common bile ducts are normal/not seen.

Gastrointestinal

The gastric lumen is mildly fluid-distended. The gastric wall is normal to mildly thickened (up to 0.66 cm) with retention of the normal layering pattern. The pyloric outflow tract is patent. The small intestinal lumen is not dilated. The small intestinal wall is normal in thickness with a normal layering pattern and appropriate mural detail. Discreet masses are not identified. The colonic wall is normal. The lumen of the descending colon contains liquid fecal material. There is no obvious evidence of an obstructive pattern.

Pancreas

The right limb of the pancreas is visible with normal curvilinear peripheral contours. The parenchyma is largely isoechoic relative to surrounding omental fat and slightly mottled in appearance. The pancreatic duct is visible but not overtly dilated. There is no evidence of peripancreatic inflammation or effusion.

Free Abdomen

There is no obvious evidence free fluid. A few prominent mid- to caudal abdominal lymph nodes are visualized (the largest measuring 0.91 cm in length). Surrounding mesentery is hyperechoic.

ULTRASONOGRAPHIC FINDINGS

Primary Findings

- The gastric wall changes are most consistent with gastritis. The fluid within the gastric and colonic lumen is suggestive of gastritis/colitis.

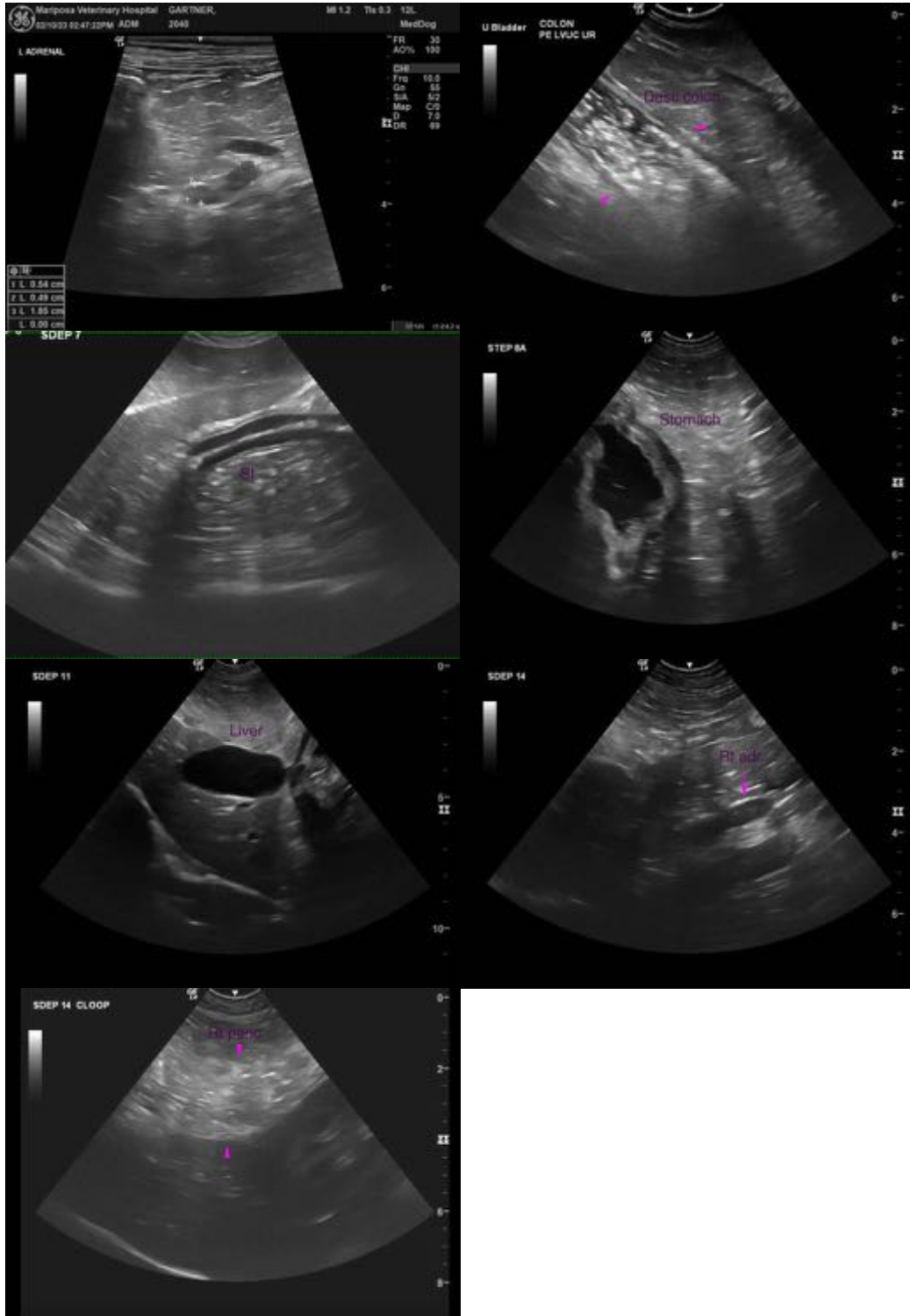
Secondary Findings

- The lymph node changes are most consistent with reactive lymphadenitis or lymphoid hyperplasia
- The pancreatic changes are most consistent with age-related parenchymal remodeling, potentially secondary to a prior inflammatory episode, early fibrosis or chronic pancreatitis.

*An obvious cause for the patient's clinical signs is not definitively identified in this study. Considerations include gastrointestinal disease (i.e., hemorrhage gastroenteritis, infectious/parasitic disease, dietary indiscretion, food allergy/intolerance), underlying metabolic issue, other.

INTERPRETATION OF THE FINDINGS & FURTHER RECOMMENDATIONS

- Despite the negative fecal evaluation, consider prophylactic deworming with Fenbendazole.
- Also consider a fecal PCR infectious disease panel.
- Medical management for acute hemorrhagic gastroenteritis is recommended. If the patient's clinical signs do not begin to improve within 48-72 hours of medical management, a more comprehensive GI work-up may be warranted.



The information and recommendations provided are based on the images presented by the referring veterinarian/sonographer. No evaluation can be communicated regarding pathology that was not visible in the image/video clips provided.

Thank you for this referral. If the clinical or image interpretation does not parallel your findings or if I can be of any further assistance, please contact me.

Andrea Nicastro, MPH, DVM, Diplomate DACVIM (Small Animal Internal Medicine)
info@SonoPath.com