

**DATE PRESENTING CLINICAL SIGNS**

2/10/2022 History: Hx of urinary stones, serial radiographs demonstrate enlarged splenic silhouette/concern for splenic mass; P recently developed decreased appetite but still eating and has occ vomiting.

**PATIENT**

Tina Fall

Additional History: Blood work from January 12<sup>th</sup>, 2022: ALP 329

**SPECIES**

Canine

Lab Results: Attached separately within request.

Radiographs: Enlarged splenic silhouette, single small urolith.

Date of Previous IntraPet Ultrasound: No previous IntraPet scans.

Sedation: Not required to complete full diagnostic ultrasound.

Stat Report: Not requested.

**BREED**

Pug Mix

Imaging Performed By: Stephanie Pearce RDCS, RVT.

**ULTRASONOGRAPHIC EXAMINATION OF THE ABDOMEN****Urinary System**

The urinary bladder, trigone, and pelvic urethra are normal in thickness and the mucosal surface is smooth. The bladder lumen is moderately distended. A small to moderate amount of aggregated echogenic suspended debris is observed within the lumen. No masses, inflammatory changes or calculi are observed. Ureteral papillae and visualized portion of the proximal urethra, visible to a depth of 2 cm, are normal.

**SEX**

Female Spayed

**AGE**

6-18-2008

The left kidney is normal in size (4.56 cm in length); with an irregular shape. There is a normal 1:3 cortex to medulla ratio with mild to moderate loss of corticomedullary distinction. Moderate pyelectasia (0.53 cm in the longitudinal plane) and caliectasis are present. Hyperechoic shadowing diverticular foci are seen. There is no evidence of hydroureter. Renal vasculature is normal.

**WEIGHT**

32.5 Lbs.

The right kidney presented normal size (5.24 cm in length); normal shape and architecture with smooth peripheral margins. There is a normal 1:3 cortex to medulla ratio with mild to moderate loss of corticomedullary distinction. Trace pyelectasia is present. There is no evidence of nephroliths, infarcts or hydroureter. Renal vasculature is normal.

**INTERPRETED BY**

Andrea Nicastro, DMV,  
Diplomate DACVIM  
(Small Animal  
Internal Medicine)

**Adrenal Glands**

The left adrenal gland is normal size (0.61 cm at cranial pole) (0.63 cm at caudal pole) (2.19 cm in length); normal shape; homogenous parenchyma. The glandular echogenicity and detail are unremarkable. Capsule, cortex, and medullary definition are normal. The phrenicoabdominal vein and surrounding vasculature are normal.

**HOSPITAL NAME**

Bayside Animal  
Medical Center

The right adrenal gland is normal size (0.60 cm at cranial pole) (0.59 cm at caudal pole) (2.03 cm in length); normal shape; homogenous parenchyma. The glandular echogenicity and detail are unremarkable. Capsule, cortex, and medullary definition are normal. The phrenicoabdominal vein and surrounding vasculature are normal.

**REFERRING VET**

Dr. Beigel

**Spleen**

A >6.5 cm irregular, hypoechoic to slightly heterogeneous, vascular mass is arising from the cranial aspect. The mass causes capsular expansion. In the remainder of the spleen, the margins are curvilinear, and the parenchyma is homogeneous. Splenic vasculature is normal with no evidence of thrombosis.

**INVOICE**

13867

**Liver**

The liver is subjectively prominent in size with normal curvilinear peripheral contours. The parenchyma is isoechoic relative to the spleen. An approximately 2 cm ill-defined isoechoic to slightly heterogeneous

nodule/mass is observed in the region of the right medial lobe. The remaining parenchyma is homogeneous. Hepatic vasculature and intrahepatic biliary tracts are of normal volume with no evidence of congestion.

The gall bladder lumen is moderately distended. The wall is thin and smooth. Luminal contents are mostly anechoic. The cystic and common bile ducts are normal.

### ***Gastrointestinal***

The stomach and intestine are free of stasis and exhibit normal peristaltic activity. The gastric lumen is not distended. The gastric wall and pylorus are normal in thickness with a normal layering pattern. The small intestinal lumen is not dilated. The small intestinal wall thickness is normal with a normal layering pattern and appropriate mural detail. Discreet masses are not identified. The colonic wall is normal. No obstructive or overt infiltrative disease is noted.

### ***Pancreas***

The pancreas is normal in size with normal peripheral contours. The pancreatic duct is normal. The base and limbs of the pancreas are isoechoic to surrounding omental fat. No focal lesions are observed. There is no evidence of peripancreatic inflammation or effusion.

### ***Free Abdomen***

There is no evidence of free fluid.

### ***Lymph Nodes***

\*See Other Category.

### ***Other***

Two, irregular cystic nodules/masses are observed in the right cranial quadrant. One measuring 3.54 cm x 1.98 cm, the other measuring 2.17 cm x 2.06 cm. Surrounding mesentery is hyperechoic.

## **ULTRASONOGRAPHIC FINDINGS**

### **Primary Findings**

- Large, vascular splenic mass. Neoplasia (i.e., round cell tumor, sarcoma) is considered likely with a lower possibility of benign pathology.
- The hepatic nodule trends toward the benign (i.e., regenerative nodule). However, a metastatic lesion cannot be completely excluded.
- The origin of the nodules/masses in the right cranial quadrant is unclear. They are suspected to be cystic lymph nodes. However, nodules within the mesentery cannot be completely excluded.

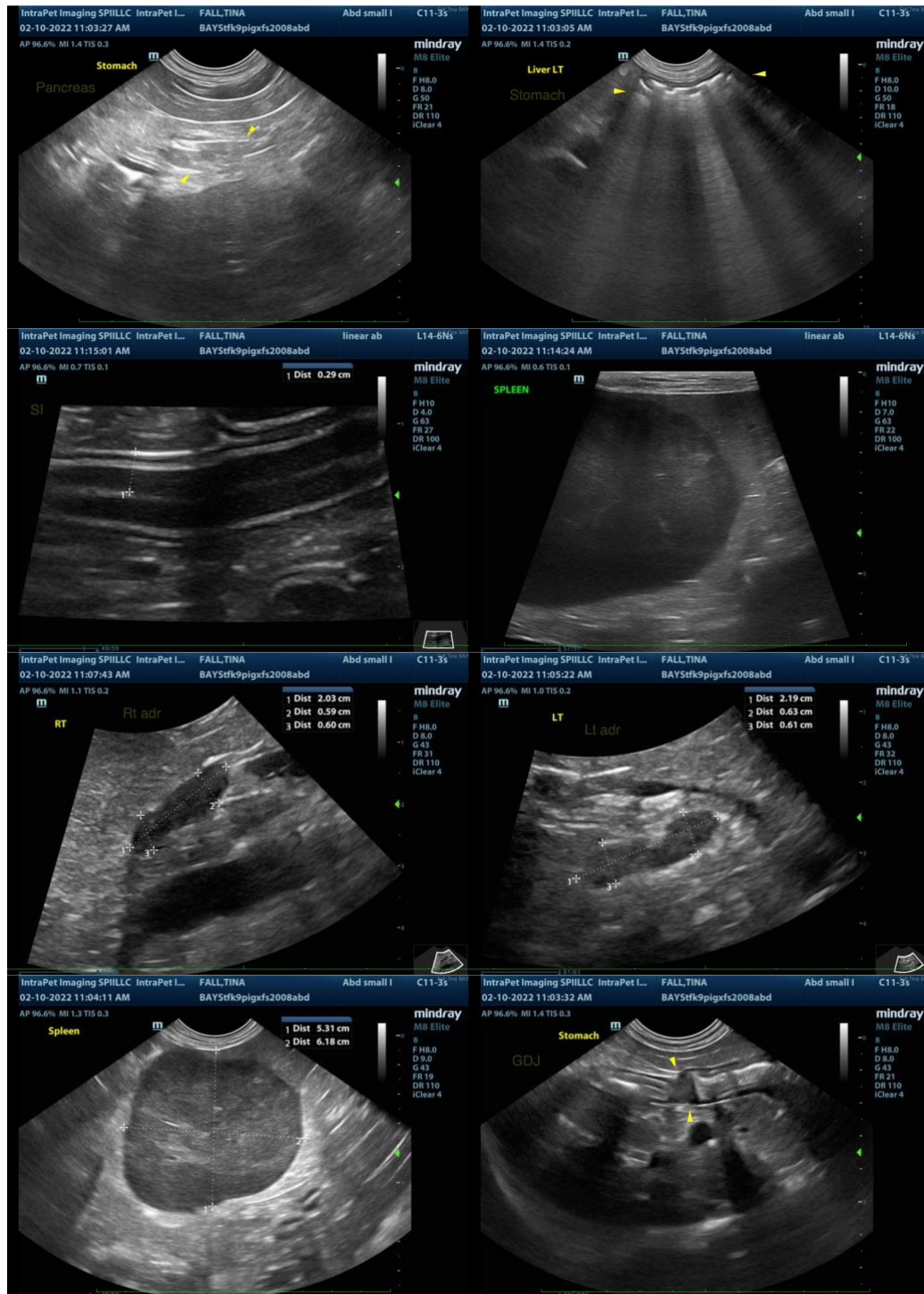
### **Secondary Findings**

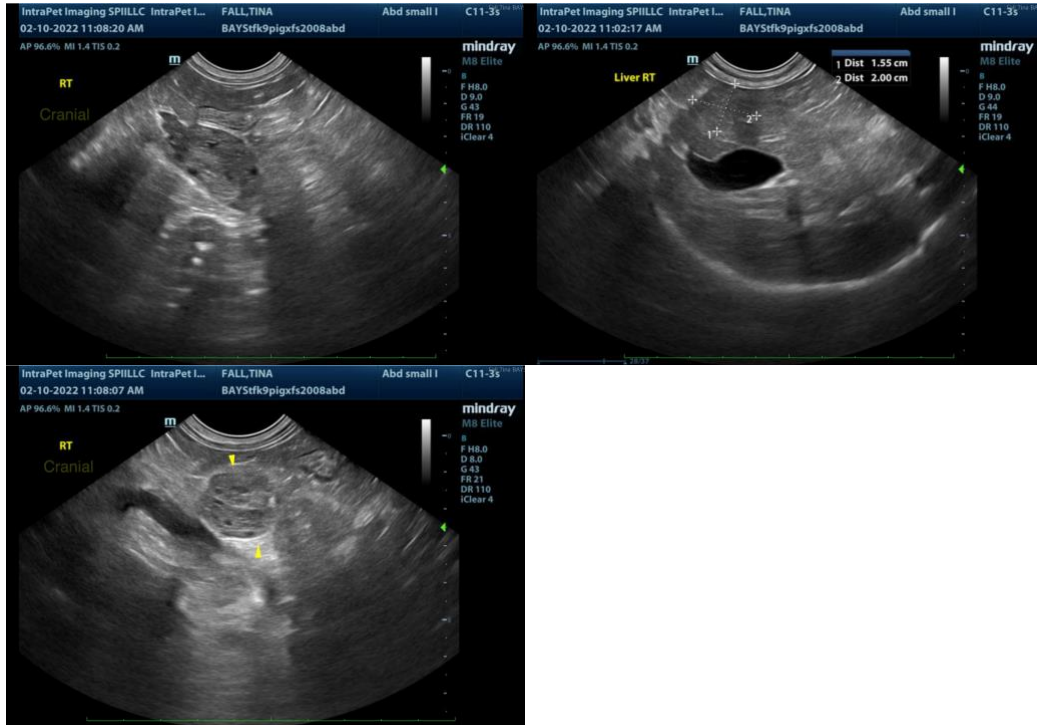
- Bilateral degenerative renal changes with pyelectasia, more pronounced on the left side.
- Urinary bladder debris

## **INTERPRETATION OF THE FINDINGS & FURTHER RECOMMENDATIONS**

- Three-view thoracic radiographs are recommended to assess for pulmonary metastases.
- Consider a fine needle aspirate of the splenic mass if clotting status is appropriate. Care should be taken to avoid major vessels during the procedure. If cytology results are inconclusive, an

abdominal exploratory with splenectomy and biopsies of the nodules in the right cranial quadrant can be considered. A liver biopsy should also be obtained with special attention to the nodule near the right medial lobe.





The information and recommendations provided are based on the images presented by the referring veterinarian/sonographer. No evaluation can be communicated regarding pathology that was not visible in the image/video clips provided.

Thank you for this referral. If the clinical or image interpretation does not parallel your findings or if I can be of any further assistance, please contact me.

**Andrea Nicastro, DVM, Diplomate DACVIM (Small Animal Internal Medicine)**  
info@SonoPath.com