**DATE PRESENTING CLINICAL SIGNS**

2/10/2022 History: Elevated Alkp.

PATIENT

Remi Dixon

Lab Results: Alkp 412.
 Date of Previous IntraPet Ultrasound: No previous IntraPet scans.
 Sedation: Patient sedated with Torbugesic.
 Stat Report: Not requested.

SPECIES

Canine

Imaging Performed By: Andi Parkinson, RDMS.

Additional history: Alk Foss 412

BREED

Mix

ULTRASONOGRAPHIC EXAMINATION OF THE ABDOMEN**SEX**

Female Spayed

Urinary System

The urinary bladder, trigone, and pelvic urethra are normal in thickness and the mucosal surface is smooth. The bladder lumen is moderately distended with anechoic urine. No masses, inflammatory changes or calculi are observed. Ureteral papillae and visualized portion of the proximal urethra, visible to a depth of 2 cm, are normal.

AGE

6-10-2018

The left kidney presented normal size (5.92 cm in length); normal shape and architecture with smooth peripheral margins. There is a normal 1:3 cortex to medulla ratio with normal corticomedullary distinction. There is no evidence of pyelectasia, nephroliths, infarcts or hydroureter.

WEIGHT

47.4 Lbs.

The right kidney presented normal size (6.28 cm in length); normal shape and architecture with smooth peripheral margins. There is a normal 1:3 cortex to medulla ratio with normal corticomedullary distinction. There is no evidence of pyelectasia, nephroliths, infarcts or hydroureter.

INTERPRETED BY

Andrea Nicastro,
 DMV, Diplomate
 DACVIM (Small Animal
 Internal Medicine)

Adrenal Glands

The left adrenal gland is normal size (0.47 cm at cranial pole) (0.58 cm at caudal pole) (1.90 cm in length); normal shape; homogenous parenchyma. The glandular echogenicity and detail are unremarkable. Capsule, cortex, and medullary definition are normal. The phrenicoabdominal vein and surrounding vasculature are normal.

HOSPITAL NAME

Banfield PH of
 Towson

The right adrenal gland is normal size (0.43 cm at cranial pole) (0.44 cm at caudal pole) (2.23 cm in length); normal shape; homogenous parenchyma. The glandular echogenicity and detail are unremarkable. Capsule, cortex, and medullary definition are normal. The phrenicoabdominal vein and surrounding vasculature are normal.

REFERRING VET

Dr. Chadha

Spleen

The spleen is normal in size (1.67 cm in width at the level of the hilus) with a normal capsular contour. There is appropriate echogenicity and echotexture. No focal lesions are observed. Splenic vasculature is normal.

INVOICE

10311

Liver

The liver is subjectively normal in size with normal contours and structure. There is appropriate echogenicity and echotexture. No overt structural evidence of inflammatory, infiltrative, or regenerative pathology is evident. Vascular and biliary tracts are of normal volume with no evidence of congestion. No pathological hepatic lymphadenopathy observed.

The gall bladder lumen is moderately distended. The wall is thin and smooth. Luminal contents are

anechoic. The cystic and common bile ducts are normal.

Gastrointestinal

The gastric lumen is mildly to moderately distended with ingesta. The gastric wall is normal in thickness with a normal layering pattern. The small intestinal lumen is segmentally gas distended. The small intestinal wall thickness is normal with a normal layering pattern and appropriate mural detail. Discreet masses are not identified. The ileocecolic junction and colonic wall are normal. There is no evidence of an obstructive pattern.

Pancreas

The region of the pancreas is isoechoic relative to surrounding omental fat. No obvious parenchymal abnormalities are observed. There is no evidence of regional inflammation or effusion.

Free Abdomen

The peritoneal cavity is normal. There is no evidence of inflammation or effusion. The abdominal lymph nodes are normal/not visible.

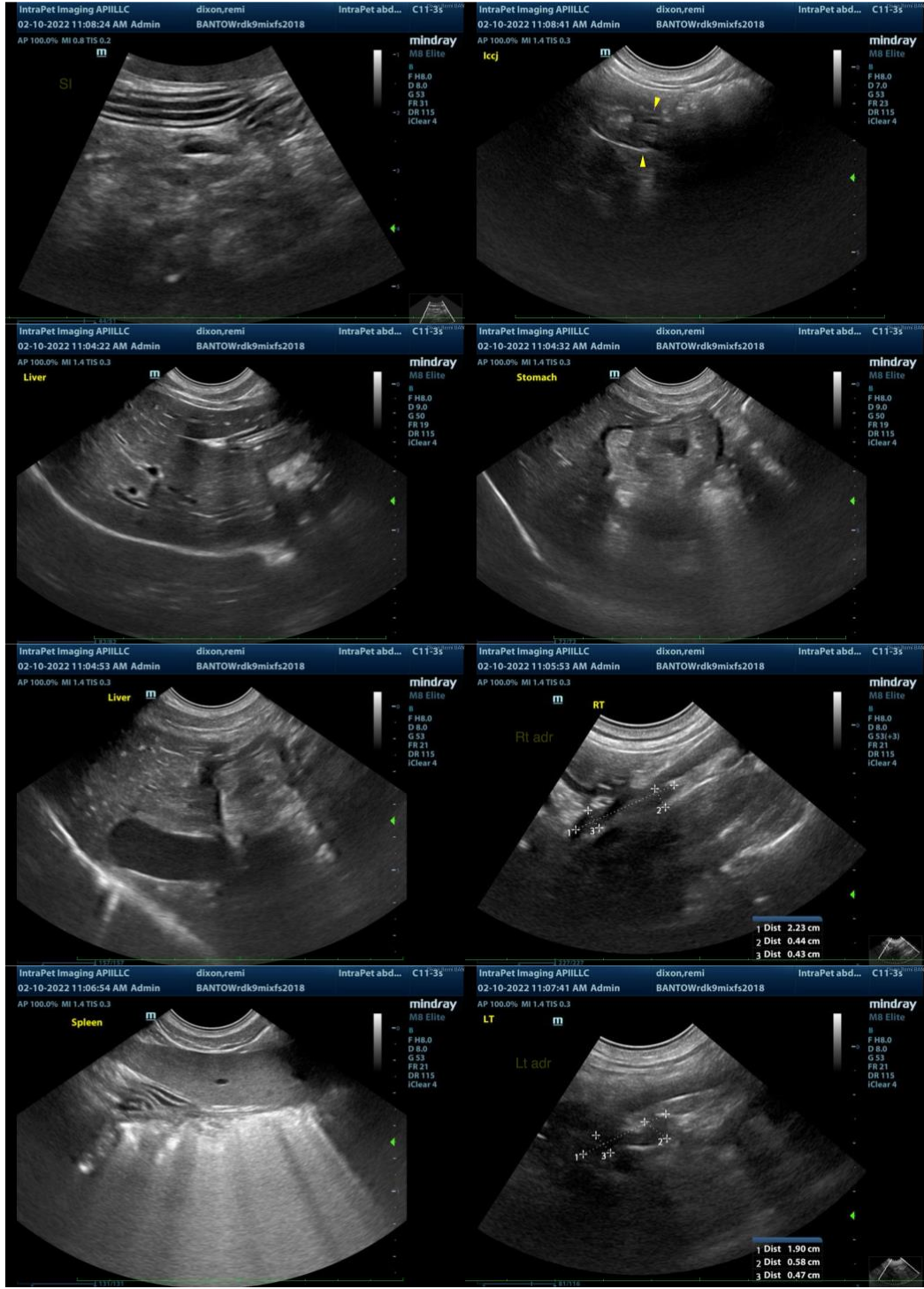
ULTRASONOGRAPHIC FINDINGS

Primary Findings

- Unremarkable abdomen. An obvious cause for the patient's elevated ALP is not identified in this study. Possible considerations include microscopic cholestasis, Leptospirosis, mild vacuolar or other hepatopathy.

INTERPRETATION OF THE FINDINGS & FURTHER RECOMMENDATIONS

- Consider Leptospirosis testing (i.e., blood and urine PCR, serology).
- Also consider initiation of a hepatic antioxidant (i.e., Denamarin +/- Ursodiol).
- Also consider pre-and postprandial serum bile acids to assess hepatic function.
- Recheck of liver values is recommended in 2-4 weeks. If values continue to increase, a repeat abdominal ultrasound +/- further workup (i.e., surgical liver biopsy), may be warranted.



The information and recommendations provided are based on the images presented by the referring veterinarian/sonographer. No evaluation can be communicated regarding pathology that was not visible in the image/video clips provided.

Thank you for this referral. If the clinical or image interpretation does not parallel your findings or if I can be of any further assistance, please contact me.

Andrea Nicastro, DVM, Diplomate DACVIM (Small Animal Internal Medicine)
info@SonoPath.com