

**DATE PRESENTING CLINICAL SIGNS**

2/10/2022 History: Acute onset of Vomiting past 12 hours. Presents as ADR/ QAR. Patient is Diabetic and has Chronic Pancreatitis for several years. Elevated liver.

PATIENT

Harrison Huber

Radiographs this Am show possible mass in abdomen. Gave Cerenia 10 mg/ml 0.4 ML SQ this am. Gave Pepcid 10 mg/ml 0.4 ML SQ this am and NPH insulin 3 units SQ. (FASTED) Patient not holding down food/ water. Fasted for scan. Additional History: Ketonuria, glucosuria and proteinuria are present. Urine Specific Gravity 1.030.

SPECIES

Canine

Current Medications: NPH insulin 4 units SQ every 12 hours (3 units given today) 2012 Denamarin 1 tab in am prior to meal. 2018

Coblequan 1 tab in am with food 2018

Soloxine 0.1 mg 1/2 tablet by mouth every 12 hours - 2018 Pancreplus powder 1 scoop with meal - 2018.

Patient is currently eating Hills WD diet canned and dry.

BREED

Yorkshire Terrier

Lab Results: Glucose high at 406, ALT high at 166, ALKP high at 332, Urine: Rods suspected.

SEX

Neutered Male

Radiographs: Cranial Abdominal mass noted on radiographs this am.

AGE

10/13/10

Date of Previous IntraPet Ultrasound: No previous.

Sedation: Not required to complete full diagnostic ultrasound.

Stat Report: Not requested.

WEIGHT

6.8 lbs.

Imaging Performed By: Andi Parkinson, RDMS.

ULTRASONOGRAPHIC EXAMINATION OF THE ABDOMEN**INTERPRETED BY**

Andrea Nicastro, DMV,
Diplomate DACVIM
(Small Animal
Internal Medicine)

Urinary System

The urinary bladder is mildly distended with anechoic urine. The wall is of appropriate thickness for the level of repletion. The mucosal surface is slightly irregular with suspected area of mineralization. No cystic calculi are observed. The region of the trigone is normal.

The prostate is not definitively visualized due to its pelvic location.

HOSPITAL NAME

Celebric Veterinary
Hospital

The left kidney is normal in size (3.66 cm in length); with a slightly irregular shape. The cortex is variably thickened and there is moderate loss of corticomedullary distinction. Hyperechoic shadowing diverticular foci +/- tiny nephroliths are present. There is no evidence of pyelectasia or hydroureter.

The right kidney is normal in size (4.28 cm in length); with a normal shape and smooth peripheral contours. The cortex is mildly thickened and there is moderate loss of corticomedullary distinction. A few small nonobstructive nephroliths are visualized. There is no evidence of pyelectasia, infarcts or hydroureter.

REFERRING VET

Dr. Garrett

Adrenal Glands

The left adrenal gland is mildly enlarged (0.58 cm at cranial pole) (0.67 cm at caudal pole) (1.92 cm in length); normal shape; homogenous parenchyma. The glandular echogenicity and detail are unremarkable. Capsule, cortex, and medullary definition are normal. The phrenicoabdominal vein and surrounding vasculature are normal.

INVOICE

13865

The right adrenal gland is mildly enlarged (0.61 cm at cranial pole) (0.64 cm at caudal pole) (1.74 cm in length); normal shape; homogenous parenchyma. The glandular echogenicity and detail are unremarkable.

Capsule, cortex, and medullary definition are normal. The phrenicoabdominal vein and surrounding vasculature are normal.

Spleen

The spleen is normal in size (0.94 cm in width at the level of the hilus) with a normal capsular contour. There is appropriate echogenicity and echotexture. No focal lesions are observed. Splenic vasculature is normal.

Liver

The liver is subjectively enlarged with swollen/rounded peripheral contours. The parenchyma is isoechoic relative to the spleen and diffusely heterogeneous in appearance. No distinct focal lesions are observed. Hepatic vasculature and intrahepatic biliary tracts are of normal volume with no evidence of congestion.

The gall bladder is moderately distended. The wall is hyperechoic to mineralized. A small to moderate amount of aggregated echogenic sludge, some of which is adhered to the luminal wall and some of which is suspended, is observed within the lumen. The cystic and common bile ducts are normal/not seen.

Gastrointestinal

The stomach and intestine are free of stasis and exhibit normal peristaltic activity. The gastric lumen is not distended. The gastric wall and pylorus are normal in thickness with a normal layering pattern. The small intestinal lumen is not dilated. The small intestinal wall is normal to mildly thickened (up to 0.38 cm) with a normal layering pattern. There is evidence of mucosal fogging and speckling +/- striations in some segments.

Discreet masses are not identified. The colonic wall is normal. There is no evidence of an obstructive pattern.

Pancreas

The right limb of the pancreas is visible with normal curvilinear peripheral contours. The parenchyma is largely isoechoic relative to surrounding omental fat and slightly mottled in appearance. The pancreatic duct is visible but not overtly dilated. There is no evidence of peripancreatic inflammation or effusion.

Free Abdomen

The peritoneal cavity is normal. There is no evidence of inflammation or effusion. The abdominal lymph nodes are normal/not visible.

ULTRASONOGRAPHIC FINDINGS

Primary Findings

- Suspected benign hepatopathy (i.e., vacuolar hepatopathy and/or regenerative nodular hyperplasia). Low-grade inflammation, however, cannot be completely excluded. Infiltrative neoplasia is possible but considered less likely.
- Mineralized ("porcelain") gallbladder. This finding is consistent with cholecystitis. However, it has been associated with biliary carcinoma in some instances.
- The small intestinal mucosal changes are suggestive of an inflammatory process +/- concurrent lymphangiectasia. However, correlation with the patient's clinical history is recommended.

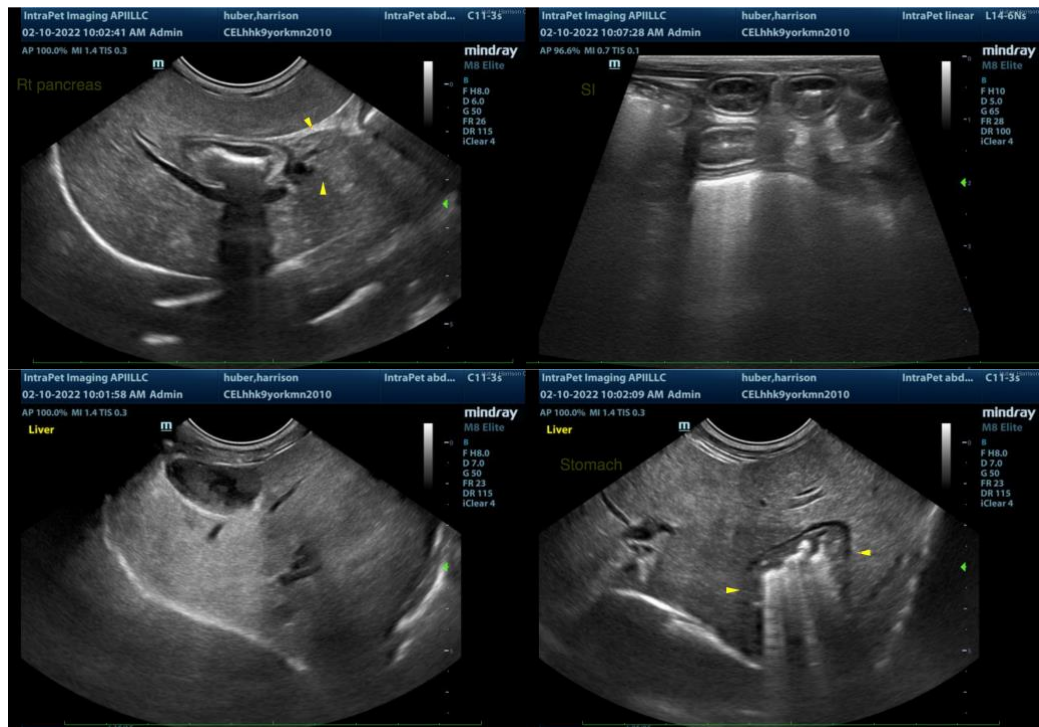
Secondary Findings

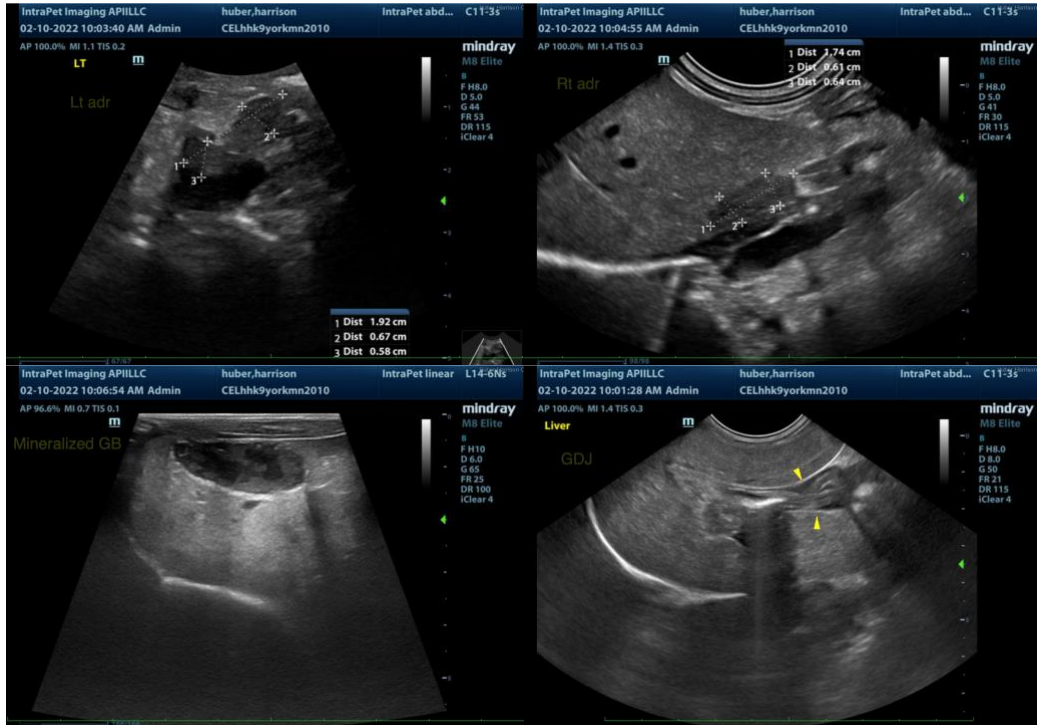
- Minor age-related pancreatic remodeling

- Mild bilateral adrenomegaly
- Bilateral nephropathy with nonobstructive nephrolithiasis

INTERPRETATION OF THE FINDINGS & FURTHER RECOMMENDATIONS

- Supportive care for diabetic ketoacidosis is recommended, including regular insulin, fluid therapy, gastric protectants and antiemetics.
- Diagnostic considerations include the following:
 1. Urine culture and sensitivity
 2. Malabsorption panel, including serum cobalamin, folate, TLI and PLI
 3. +/- fine needle aspirate of the liver (if clotting status is appropriate)
 4. Given the patients age and diabetic status, three-view thoracic radiographs are recommended to assess cardiopulmonary status and to evaluate for occult aspiration pneumonia.





The information and recommendations provided are based on the images presented by the referring veterinarian/sonographer. No evaluation can be communicated regarding pathology that was not visible in the image/video clips provided.

Thank you for this referral. If the clinical or image interpretation does not parallel your findings or if I can be of any further assistance, please contact me.

Andrea Nicastro, DVM, Diplomate DACVIM (Small Animal Internal Medicine)
 info@SonoPath.com