



**PATIENT PRESENTING CLINICAL SIGNS**

Nico Rydzewsky History: Elevated ALT and ALKP. Current meds: Amoxi 100mg; Metronidazole 62.5mg  
Abnormal PE/Chem/CBC/UA Results: ALT 179; ALKP 740

**SPECIES ULTRASONOGRAPHIC EXAMINATION OF THE ABDOMEN**

Canine **Urinary System**

The urinary bladder wall is normal in thickness and the mucosal surface is smooth. The bladder is moderately distended. A small to moderate amount of suspended, echogenic debris is observed within the lumen. No masses, inflammatory changes or calculi are observed. Ureteral papillae and visualized portion of the proximal urethra, visible to a depth of 2 cm, are normal.

**BREED**

Yorkshire Terrier

**SEX**

Neutered Male

The prostate is normal in size (0.86 cm in width) and shape. Parenchyma is homogenous. The prostatic urethra appears normal without evidence of dilation or obstruction.

**AGE**

13 years

The left kidney is normal in size (4.84 cm in length) with a normal shape, architecture and smooth peripheral margins. There is a normal 1:3 cortex to medulla ratio with minimal loss of corticomedullary distinction. There is no evidence of pyelectasia, nephroliths, infarcts or hydronephrosis. Renal vasculature is normal.

The right kidney is normal in size (4.57 cm in length) with a normal shape, architecture and smooth peripheral margins. There is a normal 1:3 cortex to medulla ratio with minimal loss of corticomedullary distinction. There is no evidence of pyelectasia, nephroliths, infarcts or hydronephrosis. Renal vasculature is normal.

**WEIGHT**

14.1 lbs

**Adrenal Glands**

The left adrenal gland is mildly enlarged (0.50 cm at cranial pole) (0.61 cm at caudal pole) (1.56 cm in length) with a normal shape and homogenous parenchyma. The glandular echogenicity and detail are unremarkable. Capsule, cortex, and medullary definition are normal. The phrenicoabdominal vein and surrounding vasculature are normal.

**INTERPRETED BY**

Andrea Nicastro, DVM,  
Diplomate ACVIM (*Small  
Animal Internal Medicine*)

The right adrenal gland is in normal size (0.42 cm at cranial pole) (0.49 cm at caudal pole) (1.76 cm in length) with a normal shape and homogenous parenchyma. The glandular echogenicity and detail are unremarkable. Capsule, cortex, and medullary definition are normal. The phrenicoabdominal vein and surrounding vasculature are normal.

**IMAGING PERFORMED BY**

Shari Reffi, CVT

**Spleen**

The spleen is normal in size (1.06 cm in width at the level of the hilus) with a normal capsular contour. There is appropriate echogenicity and echotexture. A 0.80 x 0.57 cm hypoechoic nodule is observed at the lateral aspect, approximately mid-spleen. Splenic vasculature is normal.

**HOSPITAL NAME**

Summit Dog  
& Cat Hosp

**Liver**

The liver is subjectively prominent in size with normal curvilinear peripheral contours. The parenchyma is isoechoic relative to the spleen and exhibits mild heterogeneity. No distinct focal lesions are observed. Hepatic vasculature and biliary tracts are of normal volume with no evidence of congestion. The portal vein to caudal vena cava ratio is approximately 1: 1.

**REFERRING VET**

Dr. Lepkowski

**INVOICE**

12128

**Gastrointestinal**

The lumen is moderately distended with ingesta. The gastric wall and pylorus are normal in thickness with a normal layering pattern. The pyloric outflow tract is patent. The small intestinal lumen is segmentally

**DATE**

2.1.23

dilated with chyme. The small intestinal wall thickness is normal with a normal layering pattern and appropriate mural detail. Discreet masses are not identified. The colonic wall is normal. There is no evidence of an obstructive pattern.

#### ***Pancreas***

The left limb of the pancreas is visible with normal curvilinear peripheral contours. The parenchyma is largely isoechoic relative to surrounding omental fat and slightly mottled in appearance. The pancreatic duct is visible but not overtly dilated. There is no evidence of peripancreatic inflammation or effusion.

#### ***Free Abdomen***

The peritoneal cavity is normal. There is no evidence of inflammation or effusion. The abdominal lymph nodes are normal/not visible.

#### ***Other***

A brief echocardiogram reveals no evidence of pericardial effusion or obvious right atrial/auricular mass.

### **ULTRASONOGRAPHIC FINDINGS**

#### **Primary Findings**

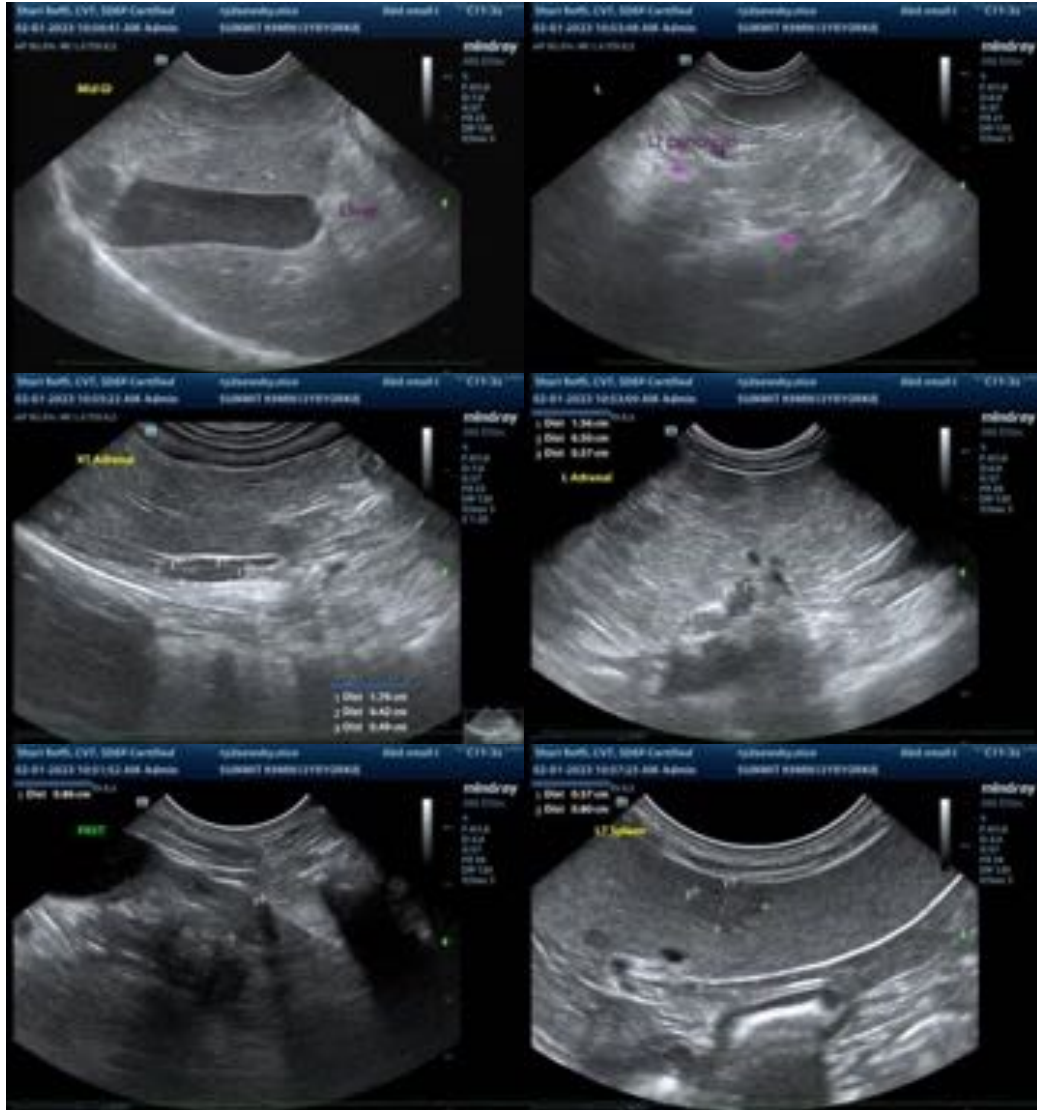
- The diffuse hepatic changes are non-specific and could be consistent with vacuolar hepatopathy, regenerative nodular hyperplasia, and/or age-related remodeling. Inflammatory and infiltrative disease are considered less likely.
- Borderline left adrenomegaly. This may be a normal variant for this patient or may represent early hyperplastic change.

#### **Secondary Findings**

- The splenic nodule trends toward the benign (i.e., focus of lymphoid hyperplasia, extramedullary hematopoiesis, or similar). However, an emerging tumor cannot be completely excluded.
- The pancreatic changes are most consistent with age-related parenchymal remodeling, potentially secondary to a prior inflammatory episode, early fibrosis or chronic pancreatitis.
- Urinary bladder debris

### **INTERPRETATION OF THE FINDINGS & FURTHER RECOMMENDATIONS**

- Serial monitoring (i.e., every 3-4 months) of the patient's liver values is recommended. If values continue to increase, a repeat abdomen ultrasound +/- a more advanced hepatic work-up (i.e., tissue sampling) may be warranted.
- Consider testing for hyperadrenocorticism with a low-dose dexamethasone suppression test or ACTH stimulation test if clinical signs (i.e., PU/PD) develop.



The information and recommendations provided are based on the images presented by the referring veterinarian/sonographer. No evaluation can be communicated regarding pathology that was not visible in the image/video clips provided.

Thank you for this referral. If the clinical or image interpretation does not parallel your findings or if I can be of any further assistance, please contact me.

**Andrea Nicastro, MPH, DVM, Diplomate DACVIM (Small Animal Internal Medicine)**  
[info@SonoPath.com](mailto:info@SonoPath.com)