

PATIENT PRESENTING CLINICAL SIGNS

Nikki Mercado

History: pu/pd, excessive panting, polyphsgic, overweight, elevated PSL, 1/13/22- panting pacing anxiety. Simpatica Trio meds q 30days Lightly Sedated for AUS scan
Abnormal PE/Chem/CBC/UA Results: ALT 133, PSL 234, PLT 507, T4 1.9, USG 1019, 1+ urine protein, pH 6.5 BP 160mmHg Urine culture negative r/o cushings, pancreatitis, hepatopathy, pheochromocytoma

SPECIES

Canine

BREED

Shih Tzu

ULTRASONOGRAPHIC EXAMINATION OF THE ABDOMEN

Urinary System

SEX

Femaale, spayed

The urinary bladder, trigone, and pelvic urethra are normal in thickness and the mucosal surface is smooth. The bladder lumen is moderately distended with anechoic urine. No masses, inflammatory changes or calculi are observed. Ureteral papillae and visualized portion of the proximal urethra, visible to a depth of 2 cm, are normal.

AGE

15.4 Years

The left kidney is normal size (4.26 cm in length); normal shape and architecture with smooth peripheral margins. There is a normal 1:3 cortex to medulla ratio with minimal to mild loss of corticomedullary distinction. Trace pyelectasia is present. There is no evidence of nephroliths, infarcts or hydroureter.

WEIGHT

20 Pounds

The right kidney is normal size (4.12 cm in length); normal shape and architecture with smooth peripheral margins. There is a normal 1:3 cortex to medulla ratio with normal corticomedullary distinction. There is no evidence of pyelectasia, nephroliths, infarcts or hydroureter. Renal vasculature is normal.

INTERPRETED BY

Andrea Nicastro, DVM,
Diplomate ACVIM
(Small Animal Internal
Medicine)

Adrenal Glands

The left adrenal gland is enlarged (0.95 cm at cranial pole) (0.67 cm at caudal pole) with a slightly irregular shape. A 1.10 x 0.71 cm hyperechoic nodule is observed at the cranial pole. The glandular echogenicity and detail at the caudal pole are unremarkable. The phrenicoabdominal vein and surrounding vasculature are normal.

IMAGING PERFORMED BY

Loetitia Saint-Jacques, RVT

The right adrenal gland is mildly enlarged (1.08 cm at cranial pole) (0.63 cm at caudal pole) (2.75 cm in length) with a slightly irregular shape. A 1.12 x 0.79 cm hyperechoic nodule is observed at the cranial pole. The glandular echogenicity and detail are unremarkable. The phrenicoabdominal vein and surrounding vasculature are normal.

HOSPITAL NAME

Truckee Meadows VH

Spleen

The spleen is normal in size (1.46 cm in width at the level of the hilus) with a normal capsular contour. There is appropriate echogenicity and echotexture. A 0.63 x 0.45 cm hypoechoic nodule is observed at the craniolateral aspect. Splenic vasculature is normal.

REFERRING VET

Dr. Kuester

Liver

The liver is subjectively normal in size with normal curvilinear peripheral contours. The parenchyma is hypoechoic relative to the spleen and subtly heterogeneous in appearance. A 0.51 cm hyperechoic nodule is visualized. Vascular and biliary tracts are of normal volume with no evidence of congestion. The gall bladder lumen is moderately distended. The wall is thin and smooth. A scant amount of echogenic debris is suspended within the lumen. The cystic and common bile ducts are normal/not seen.

INVOICE

12955

DATE

2/1/22



PATIENT *Gastrointestinal*

Nikki Mercado The stomach and intestine are free of stasis and exhibit normal peristaltic activity. The gastric lumen is minimally fluid distended. The gastric wall and pylorus are normal in thickness with a normal layering pattern. The pyloric outflow tract is patent. The small intestinal lumen is not dilated. The small intestinal wall thickness is normal with a normal layering pattern and appropriate mural detail. Discreet masses are not identified. The colonic wall is normal. No obstructive disease is noted.

SPECIES

Canine

Pancreas

BREED

Shih Tzu

The right limb of the pancreas is visible with normal curvilinear peripheral contours. The parenchyma is largely isoechoic relative to surrounding omental fat and slightly mottled in appearance. The pancreatic duct is visible but not overtly dilated. There is no evidence of peripancreatic inflammation or effusion.

SEX

Femaaale, spayed

Free Abdomen

The peritoneal cavity is normal. There is no evidence of inflammation or effusion. The abdominal lymph nodes are normal/not visible.

AGE

15.4 Years

ULTRASONOGRAPHIC FINDINGS

WEIGHT

20 Pounds

Primary Findings:

- The bilateral adrenal changes are most consistent with nodular hyperplasia with a lower possibility of emerging neoplasia.
- The hepatic parenchymal changes are non-specific and could be secondary to inflammatory disease, hepatotoxicity, infiltrative neoplasia (less likely), reactive hepatopathy +/- concurrent regenerative nodular hyperplasia and/or vacuolar hepatopathy.
- The hypoechoic splenic nodule could be consistent with emerging neoplasia or a benign process such as a focal area of extramedullary hematopoiesis or lymphoid hyperplasia.

INTERPRETED BY

Andrea Nicastro, DVM,
Diplomate ACVIM
(Small Animal Internal
Medicine)

Secondary Findings:

- Mild degenerative renal changes.
- Age-related pancreatic remodeling +/- fibrosis.

IMAGING PERFORMED BY

Loetitia Saint-Jacques, RVT

HOSPITAL NAME

Truckee Meadows VH

*It is unclear if the patient's clinical signs are secondary to primary hepatic disease or pituitary dependent hyperadrenocorticism. The lack of ALP elevation points away from Cushing's although atypical Cushing's cannot be completely excluded.

REFERRING VET

Dr. Kuester

INTERPRETATION OF THE FINDINGS & FURTHER RECOMMENDATIONS

INVOICE

12955

- An adrenal panel (send to the University of Tennessee) is recommended to further assess for Cushing's and atypical Cushing's.
- Also consider pre and post prandial serum bile acids to assess hepatic function.

DATE

2/1/22

- Given the history of panting, three-view thoracic radiographs are recommended to evaluate cardiopulmonary status.



PATIENT

Nikki Mercado

- A UPC is also recommended given the presence of proteinuria.
- A thorough neurologic evaluation is also recommended given the history of panting and anxiety.

SPECIES

Canine

- A urine culture and sensitivity should also be considered given the history of PU/PD.

BREED

Shih Tzu

SEX

Female, spayed

AGE

15.4 Years

WEIGHT

20 Pounds

INTERPRETED BY

Andrea Nicastro, DVM,
Diplomate ACVIM
(Small Animal Internal
Medicine)

IMAGING PERFORMED BY

Loetitia Saint-Jacques, RVT

HOSPITAL NAME

Truckee Meadows VH

REFERRING VET

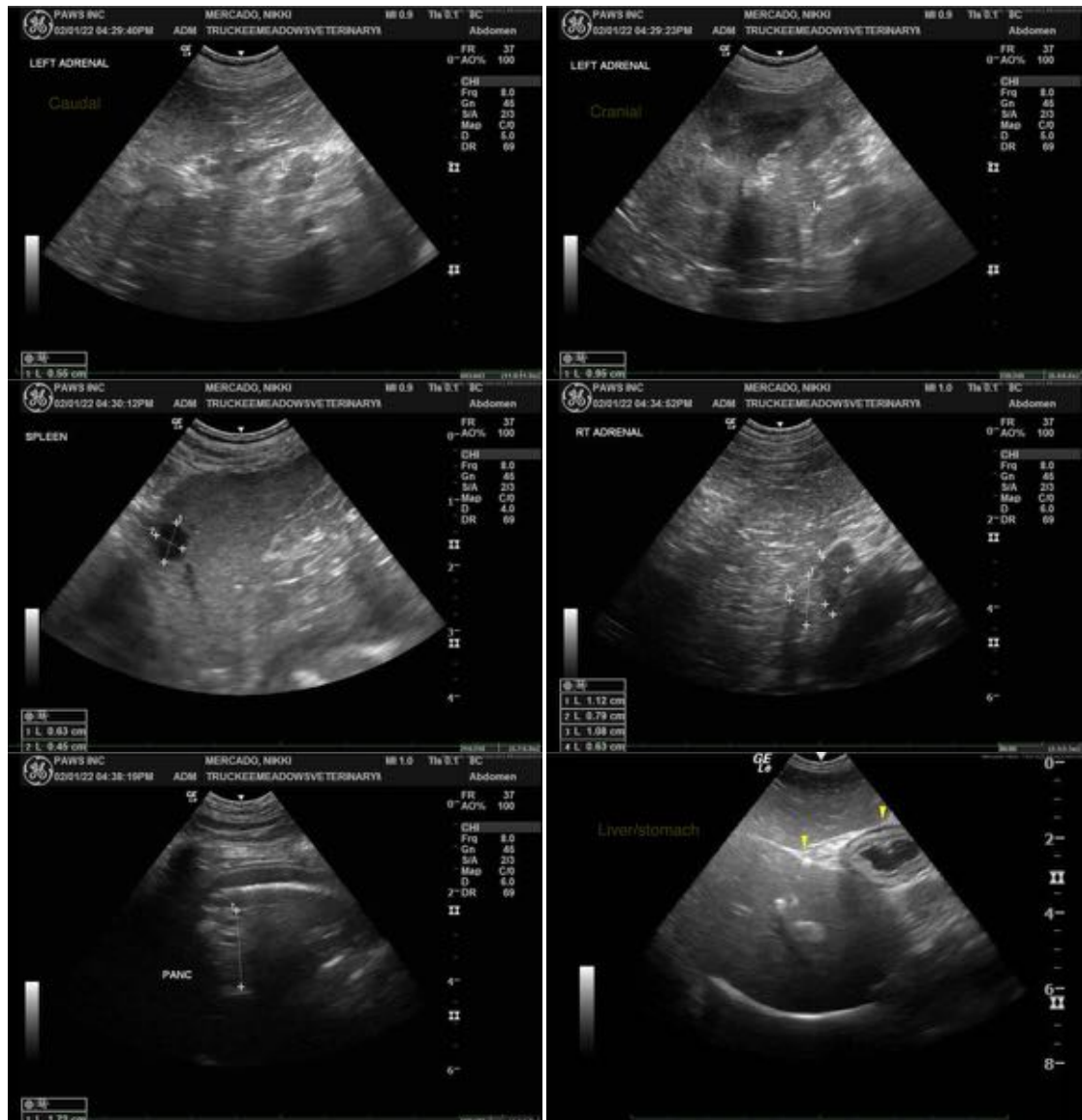
Dr. Kuester

INVOICE

12955

DATE

2/1/22





PATIENT

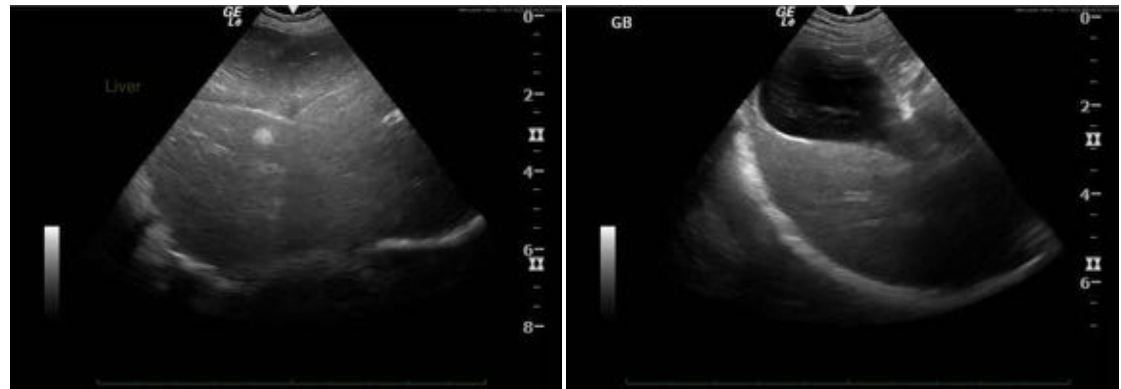
Nikki Mercado

SPECIES

Canine

BREED

Shih Tzu



SEX

Female, spayed

The information and recommendations provided are based on the images presented by the referring veterinarian/sonographer. No evaluation can be communicated regarding pathology that was not visible in the image/video clips provided.

AGE

15.4 Years

Thank you for this referral. If the clinical or image interpretation does not parallel your findings or if I can be of any further assistance, please contact me.

Andrea Nicastro, DVM, Diplomate ACVIM (*Small Animal Internal Medicine*)

WEIGHT

20 Pounds

andrea.nicastro@sonopath.com

INTERPRETED BY

Andrea Nicastro, DVM,
Diplomate ACVIM
(*Small Animal Internal
Medicine*)

IMAGING PERFORMED BY

Loetitia Saint-Jacques, RVT

HOSPITAL NAME

Truckee Meadows VH

REFERRING VET

Dr. Kuester

INVOICE

12955

DATE

2/1/22