



**PATIENT**

Max Oquendo Cardona

**SPECIES**

Canine

**BREED**

Mini Schnauzer

**SEX**

Male, neutered

**AGE**

14 Yrs.

**WEIGHT**

10.1 lbs.

**INTERPRETED BY**

Andrea Nicastro, DVM,  
Diplomate ACVIM  
(Small Animal Internal  
Medicine)

**IMAGING  
PERFORMED BY**

Dr. Ferrer

**HOSPITAL NAME**

Paseos VC

**REFERRING VET**

Dr. Maria Martes

**INVOICE**

12934

**DATE**

2/1/22

**PRESENTING CLINICAL SIGNS**

**History:** Presented for an abdominal ultrasound. Patient was presented for evaluation of hyporexia. Patient has not had vomiting but had 2 episodes of diarrhea with hematochezia yesterday. Patient is not interested in recovery diet or chicken. He has been eating ham with egg for the last 2 days. Owner considers he has lost more weight. Patient was hospitalized with IVF, Cerenia IV and famotidine IV decreased Enalapril dose to 2.5 mg 1/2 tablet BID and furosemide to 0.5 ml BID azotemia - enalapril/furosemide vs pre-renal vs renal gastritis vs IBD vs GI lymphoma  
**Abnormal PE/Chem/CBC/UA Results:** BCS 3/9 severe amount of calculus accumulation grade V/I heart murmur - no crackles or wheezes CBC - lymphopenia and eosinopenia chemistry - azotemia with creatinine at 2.3 and BUN 69, hypophosphatemia 2, hypernatremia > 180, hypoproteinemia 4.5 and hyperglobulinemia 1.1

**ULTRASONOGRAPHIC EXAMINATION OF THE ABDOMEN**

*Urinary System*

The urinary bladder is moderately distended with anechoic urine. The wall is normal in thickness with a smooth mucosal surface. The trigone is prominent. No cystic calculi are observed.

The prostate is prominent to mildly enlarged (1.02 cm in width) with a slightly irregular shape. The parenchyma is subtly heterogeneous in appearance. No distinct focal lesions are observed. The prostatic urethra is not overtly dilated.

The left kidney is normal in size (4.10 cm in length) with a normal shape, smooth peripheral margins and normal internal architecture. There is mild loss of corticomedullary distinction. Several hyperechoic shadowing diverticular foci are observed. Mild pyelectasia is present (0.26 cm in the transverse plane). There is no evidence of infarcts or hydronephrosis.

The right kidney is normal size (3.84 cm in length); normal shape and architecture with smooth peripheral margins. There is a normal 1:3 cortex to medulla ratio with mild loss of corticomedullary distinction. Hyperechoic shadowing diverticular foci are visualized. Trace pyelectasia is present (0.16 cm in the transverse plane) but there is no evidence of infarcts or hydroureter.

*Adrenal Glands*

The left adrenal gland is normal size (0.43 cm at cranial pole) (0.39 cm at caudal pole) (1.57 cm in length); normal shape; homogenous parenchyma. The glandular echogenicity and detail are unremarkable. Capsule, cortex, and medullary definition are normal. The phrenicoabdominal vein and surrounding vasculature are normal.

The right adrenal gland is normal size (0.92 cm at cranial pole) (0.53 cm at caudal pole) (1.38 cm in length); normal shape; homogenous parenchyma. The glandular echogenicity and detail are unremarkable. Capsule, cortex, and medullary definition are normal. The phrenicoabdominal vein and surrounding vasculature are normal.

*Spleen*

The spleen is normal in size (0.86 cm in width at the level of the hilus) with a normal capsular contour. There is appropriate echogenicity and echotexture. No focal lesions are observed. Splenic vasculature is normal.



**PATIENT**

**Liver**

Max Oquendo Cardona

**SPECIES**

Canine

**BREED**

Mini Schnauzer

**SEX**

Male, neutered

**AGE**

14 Yrs.

**WEIGHT**

10.1 lbs.

**INTERPRETED BY**

Andrea Nicastro, DVM,  
Diplomate ACVIM  
(Small Animal Internal  
Medicine)

**IMAGING  
PERFORMED BY**

Dr. Ferrer

**HOSPITAL NAME**

Paseos VC

**REFERRING VET**

Dr. Maria Martes

**INVOICE**

12934

**DATE**

2/1/22

The liver is subjectively normal in size with normal curvilinear peripheral contours. The parenchyma is hypoechoic relative to the spleen and subtly heterogeneous in appearance. At least 2 small hyperechoic nodules are observed. Vascular and biliary tracts are of normal volume with no evidence of congestion. The gall bladder lumen is moderately distended. The wall is thin and smooth. A small to moderate amount of suspended aggregated echogenic debris is observed within the lumen. The cystic and common bile ducts are normal/not seen.

**Gastrointestinal**

The gastric lumen is minimally distended with ingesta. The gastric wall is normal in thickness with a normal layering pattern. The small intestinal lumen is segmentally dilated with chyme. The small intestinal wall thickness is normal with a normal layering pattern and appropriate mural detail. Discreet masses are not identified. The ileocecal colic junction and colonic wall are normal. No obstructive disease is noted.

**Pancreas**

The right limb of the pancreas is visible with normal curvilinear peripheral contours. The parenchyma is largely isoechoic relative to surrounding omental fat and slightly mottled in appearance. The pancreatic duct is visible but not overtly dilated. There is no evidence of peripancreatic inflammation or effusion.

**Free Abdomen**

The peritoneal cavity is normal. There is no evidence of inflammation or effusion. A 1.02 x 0.36 cm sublumbar lymph node is visualized. In addition, 1-2 prominent mesenteric lymph nodes are seen, the largest measuring 1.79 cm in length.

**ULTRASONOGRAPHIC FINDINGS**

**Primary Findings:**

- Bilateral, degenerative renal changes with dystrophic mineralization and mild pyelectasia bilaterally.
- The prominent urinary bladder trigone may be a normal variant for this patient or may represent emerging neoplasia.
- The mild prostatomegaly may also be normal for this patient or although emerging neoplasia is also possible. Correlation with the patient's clinical findings is recommended.

**Secondary Findings:**

- Suspected benign hepatopathy (i.e., regenerative nodular hyperplasia).
- Gallbladder debris, non-mucocele.
- Age-related pancreatic remodeling.
- The lymph node changes are most consistent with reactive lymphadenitis or lymphoid hyperplasia.



**PATIENT**

Max Oquendo Cardona

**SPECIES**

Canine

**BREED**

Mini Schnauzer

**SEX**

Male, neutered

**AGE**

14 Yrs.

**WEIGHT**

10.1 lbs.

**INTERPRETED BY**

Andrea Nicastro, DVM,  
Diplomate ACVIM  
(Small Animal Internal  
Medicine)

**IMAGING  
PERFORMED BY**

Dr. Ferrer

**HOSPITAL NAME**

Paseos VC

**REFERRING VET**

Dr. Maria Martes

**INVOICE**

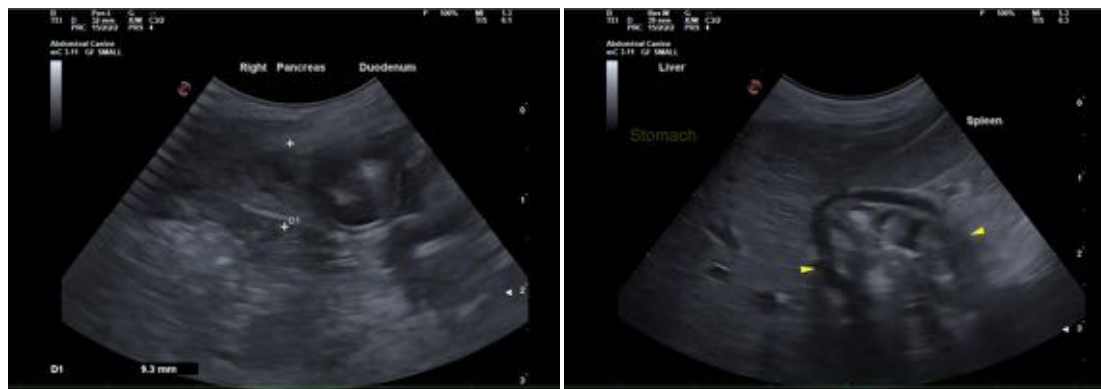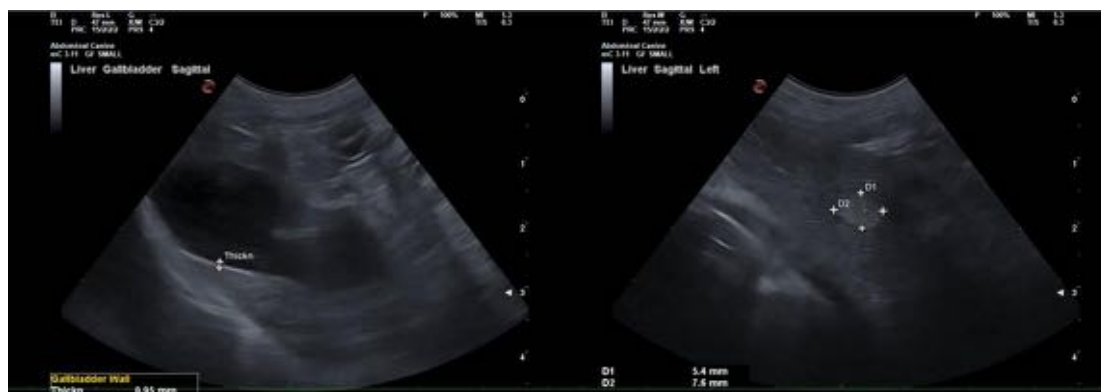
12934

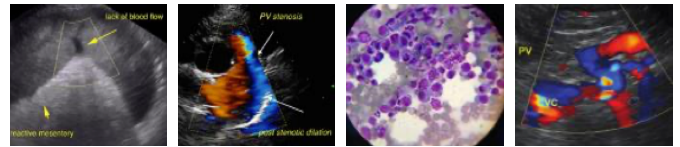
**DATE**

2/1/22

**INTERPRETATION OF THE FINDINGS & FURTHER RECOMMENDATIONS**

- Given the azotemia, consider the following:
  1. Urine culture and sensitivity
  2. UPC (if proteinuria is present)
  3. Baseline blood pressure measurement
- Regarding the prostatomegaly/prominent trigone, consider a urine BRAF test to further assess for lower urinary tract neoplasia.
- Given the GI signs, consider the following:
  1. A fecal evaluation for ova/Giardia
  2. GI panel (sent to Texas A&M)
  3. Ultimately, GI biopsies may be necessary to get a definitive diagnosis. However, the patient's cardiac and renal status must be taken into account when deciding whether the anesthetic risk is worth the benefit of biopsies.





**PATIENT**

Max Oquendo Cardona

**SPECIES**

Canine

**BREED**

Mini Schnauzer

**SEX**

Male, neutered

**AGE**

14 Yrs.

**WEIGHT**

10.1 lbs.

**INTERPRETED BY**

Andrea Nicastro, DVM,  
Diplomate ACVIM  
(Small Animal Internal  
Medicine)

**IMAGING PERFORMED BY**

Dr. Ferrer

**HOSPITAL NAME**

Paseos VC

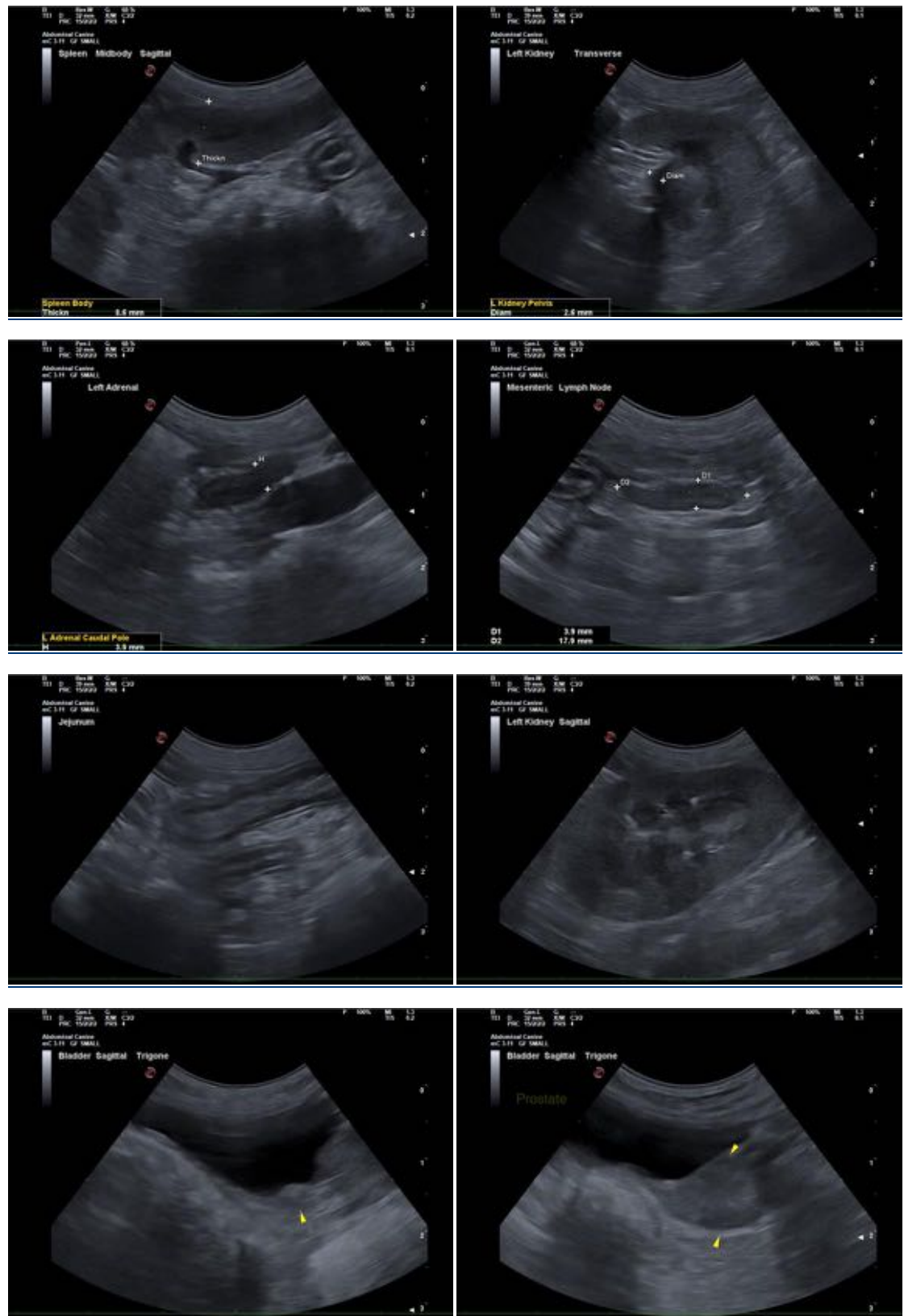
**REFERRING VET**

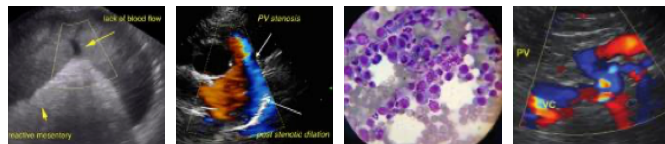
Dr. Maria Martes

**INVOICE**

12934

**DATE**  
2/1/22





**PATIENT**

Max Oquendo Cardona

**SPECIES**

Canine

**BREED**

Mini Schnauzer

**SEX**

Male, neutered

**AGE**

14 Yrs.

**WEIGHT**

10.1 lbs.

**INTERPRETED BY**

Andrea Nicastro, DVM,  
Diplomate ACVIM  
(*Small Animal Internal  
Medicine*)

**IMAGING  
PERFORMED BY**

Dr. Ferrer

**HOSPITAL NAME**

Paseos VC

**REFERRING VET**

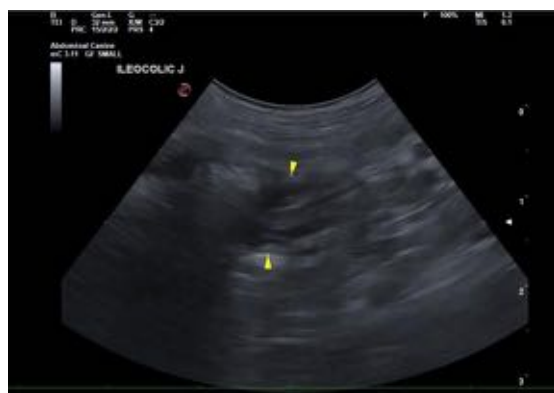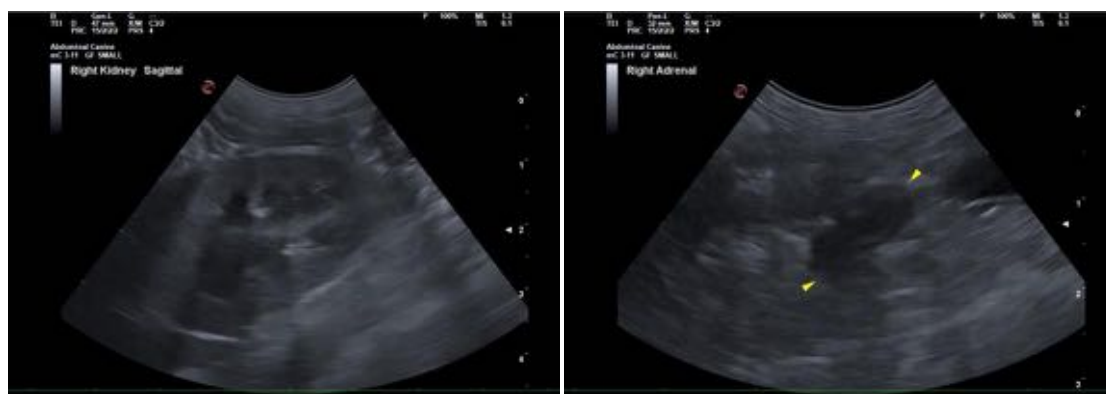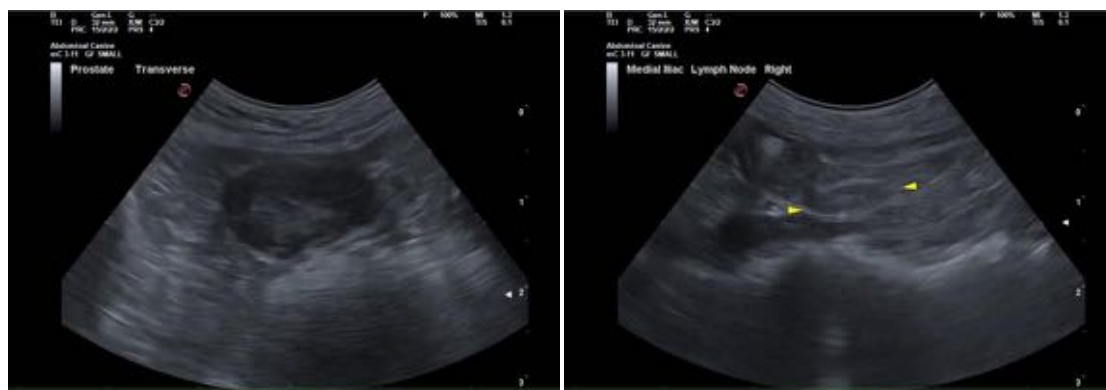Dr. Maria Martes

**INVOICE**

12934

**DATE**

2/1/22



The information and recommendations provided are based on the images presented by the referring veterinarian/sonographer. No evaluation can be communicated regarding pathology that was not visible in the image/video clips provided.

Thank you for this referral. If the clinical or image interpretation does not parallel your findings or if I can be of any further assistance please contact me.

Andrea Nicastro, DVM, Diplomate ACVIM (*Small Animal Internal Medicine*)

Andrea.nicastro@sonopath.com