



**PATIENT**

Harley Scott

**SPECIES**

Canine

**BREED**

Maltese

**SEX**

Male, neutered

**AGE**

11 Yrs

**WEIGHT**

12.7 lbs.

**INTERPRETED BY**

Andrea Nicastro, DVM,  
Diplomate ACVIM  
(Small Animal Internal  
Medicine)

**IMAGING  
PERFORMED BY**

Dr. Mengine

**HOSPITAL NAME**

Stoney CreekVH

**REFERRING VET**

Dr. Mingein

**INVOICE**

12937

**DATE**

2/1/22

**PRESENTING CLINICAL SIGNS**

History: Diagnosed with diabetes mellitus in 6/21, treated with 5.5U Insulin - client did not come back for follow up until today, as she was monitoring urine at home. Presented today with 1 week of anorexia, 24 hours of vomiting & diarrhea, marked icterus & fever. CBC/ Chem - WBC 18.5 (mature neutrophilia). ALT >1000, ALP >2000 TBili >27.9 all exceed the high end of our analyzer range. Chol 485. (in June ALT was 153, ALP 1000, client declined low-dose-dex testing at that time). U/A - inaccurate due to bilirubinuria, sediment unremarkable

**ULTRASONOGRAPHIC EXAMINATION OF THE ABDOMEN**

*Urinary System*

The urinary bladder and visible portion of the pelvic urethra are normal for the degree of luminal distension. The urine is anechoic with no evidence of debris. Cystic calculi and discrete masses are not observed.

The prostate is normal in size (0.85 cm in width) and shape. Parenchyma is homogenous. The prostatic urethra appears normal without evidence of dilation or obstruction.

The left kidney is normal in size (4.50 cm in length) with a normal shape, smooth peripheral margins and normal internal architecture. There is moderate loss of corticomedullary distinction. Several hyperechoic shadowing diverticular foci are observed. There is no evidence of pyelectasia, infarcts or hydronephrosis. Renal vasculature is normal.

The right kidney is normal size (5.04 cm in length) with a normal shape, smooth peripheral margins and normal internal architecture. There is moderate loss of corticomedullary distinction. Several hyperechoic shadowing diverticular foci are observed. There is no evidence of pyelectasia, infarcts or hydronephrosis. Renal vasculature is normal.

*Adrenal Glands*

The left adrenal gland is mildly enlarged (0.61 cm at cranial pole) (0.69 cm at caudal pole) (1.66 cm in length); normal shape; homogenous parenchyma. The glandular echogenicity and detail are unremarkable. Capsule, cortex, and medullary definition are normal. The phrenicoabdominal vein and surrounding vasculature are normal.

The right adrenal gland is normal size (0.48 cm at cranial pole) (0.36 cm at caudal pole) (1.47 cm in length); normal shape; homogenous parenchyma. The glandular echogenicity and detail are unremarkable. Capsule, cortex, and medullary definition are normal. The phrenicoabdominal vein and surrounding vasculature are normal.

*Spleen*

The spleen is subjectively prominent in size (1.37 cm in width at the level of the hilus) with slightly swollen peripheral contours. The parenchyma is mottled in appearance. Using a high frequency probe, the parenchyma is bordering on "moth-eaten". No distinct focal lesions are observed. Splenic vasculature appears normal with no evidence of thrombosis.

*Liver*

The liver is subjectively enlarged with swollen peripheral contours. The parenchyma is isoechoic relative to the spleen and subtly heterogeneous in appearance. No distinct focal lesions are observed. Vascular and biliary tracts are of normal volume with no evidence of congestion. The gall bladder lumen



**PATIENT**

Harley Scott

is moderately distended. The wall is diffusely thickened (up to 0.27 cm) and slightly irregular. A moderate amount of suspended echogenic debris/sludge in a questionably partial stellate pattern is observed within the lumen. The mesentery effacing the serosal surface is hyperechoic. The cystic and common bile ducts appear dilated with thickened walls.

**SPECIES**

Canine

**Gastrointestinal**

The gastric lumen is minimally distended with ingesta. The gastric wall is normal to borderline thickened (up to 0.54 cm) with retention of the normal layering pattern. The pyloric outflow tract is patent. The small intestinal lumen is not dilated. The small intestinal wall thickness is normal with a normal layering pattern and appropriate mural detail. Discreet masses are not identified. The colonic wall is normal. No obstructive disease is noted.

**BREED**

Maltese

**Pancreas**

**SEX**

Male, neutered

The left limb of the pancreas is prominent in size with minimal deviation from the normal peripheral contours. The parenchyma is hypoechoic relative to surrounding omental fat and subtly mottled in appearance. No distinct focal lesions are observed. The pancreatic duct is visible but not overtly dilated (0.25 cm in diameter).

**AGE**

11 Yrs

**Free Abdomen**

There is no evidence of free fluid. A 1.20 x 0.52 cm medial iliac lymph node is visualized. The node is normal in shape and echogenicity.

**WEIGHT**

12.7 lbs.

**ULTRASONOGRAPHIC FINDINGS**

**INTERPRETED BY**

Andrea Nicastro, DVM,  
Diplomate ACVIM  
(Small Animal Internal  
Medicine)

**Primary Findings:**

- The gallbladder/bile duct wall changes are most consistent with cholecystitis/cholangitis and possible developing mucocele. Regional peritonitis is present.
- Non-specific diffuse hepatopathy. Differentials include inflammatory/immune mediated disease, hepatotoxicosis (i.e., copper), infiltrative neoplasia (i.e., lymphoma), other hepatopathy +/- concurrent benign, age-related change (i.e., vacuolar hepatopathy, regenerative nodular hyperplasia).
- The splenic parenchymal changes could be consistent with infiltrative neoplasia (i.e., lymphoma). Alternatively, a benign process such as lymphoid hyperplasia or extramedullary hematopoiesis may be present.

**IMAGING PERFORMED BY**

Dr. Mengine

**Secondary Findings:**

- Bilateral degenerative renal changes with dystrophic mineralization.
- Mild left adrenomegaly.
- The pancreatic changes are suggestive chronic pancreatitis.

**HOSPITAL NAME**

Stoney CreekVH

**REFERRING VET**

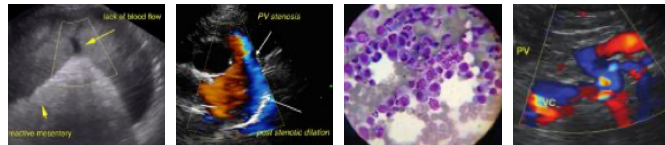
Dr. Mingein

**INVOICE**  
12937

**INTERPRETATION OF THE FINDINGS & FURTHER RECOMMENDATIONS**

- Three-view thoracic radiographs are recommended to assess cardiopulmonary status, particularly given the patient's age.

**DATE**  
2/1/22



**PATIENT**

Harley Scott

**SPECIES**

Canine

**BREED**

Maltese

**SEX**

Male, neutered

**AGE**

11 Yrs

**WEIGHT**

12.7 lbs.

**INTERPRETED BY**

Andrea Nicastro, DVM,  
Diplomate ACVIM  
(Small Animal Internal  
Medicine)

**IMAGING PERFORMED BY**

Dr. Mengine

**HOSPITAL NAME**

Stoney Creek VH

**REFERRING VET**

Dr. Mingein

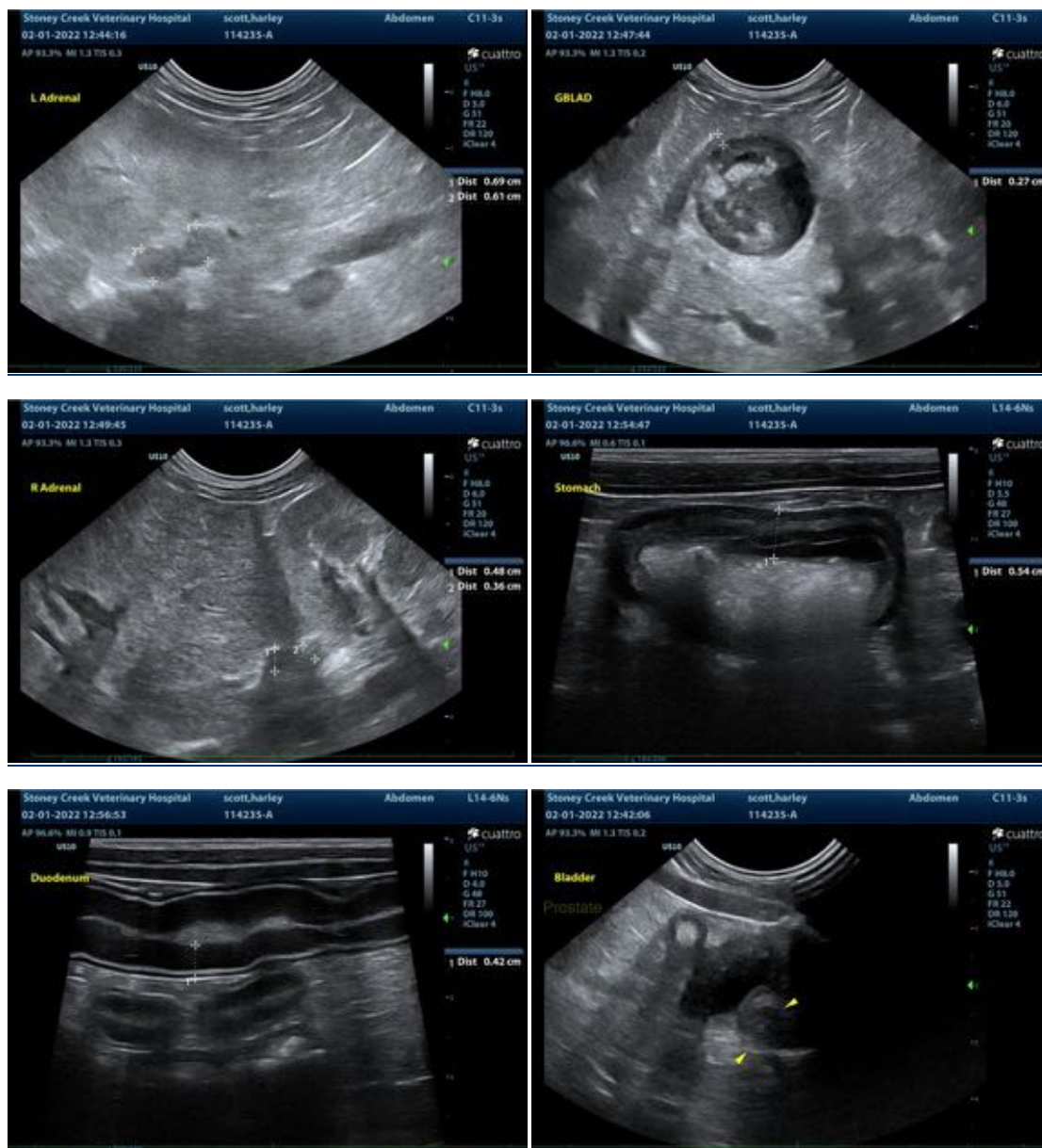
**INVOICE**

12937

**DATE**

2/1/22

- Fine needle aspirates of the liver and spleen should be considered, if clotting status is appropriate. 25-gauge needles should be used. While awaiting test results, empirical treatment for cholecystitis/choolangitis/choolangiohepatitis should be considered along with initiation of Ursodiol therapy. If cytology results are inconclusive, an abdominal exploratory with hepatic biopsies, aerobic and anaerobic bile cultures +/- cholecystectomy and acquisition of additional hepatic tissue samples for potential copper quantitation may be warranted. If a non-surgical approach is pursued, serial sonographic monitoring (i.e., every 4-6 weeks) of the gall bladder is recommended to assess for progression, as mucoceles can rupture at any point, resulting in bile/septic peritonitis.
- Also consider Leptospirosis testing (i.e., blood and urine PCR, serology).





**PATIENT**

Harley Scott

**SPECIES**

Canine

**BREED**

Maltese

**SEX**

Male, neutered

**AGE**

11 Yrs

**WEIGHT**

12.7 lbs.

**INTERPRETED BY**

Andrea Nicastro, DVM,  
Diplomate ACVIM  
(Small Animal Internal  
Medicine)

**IMAGING  
PERFORMED BY**

Dr. Mengine

**HOSPITAL NAME**

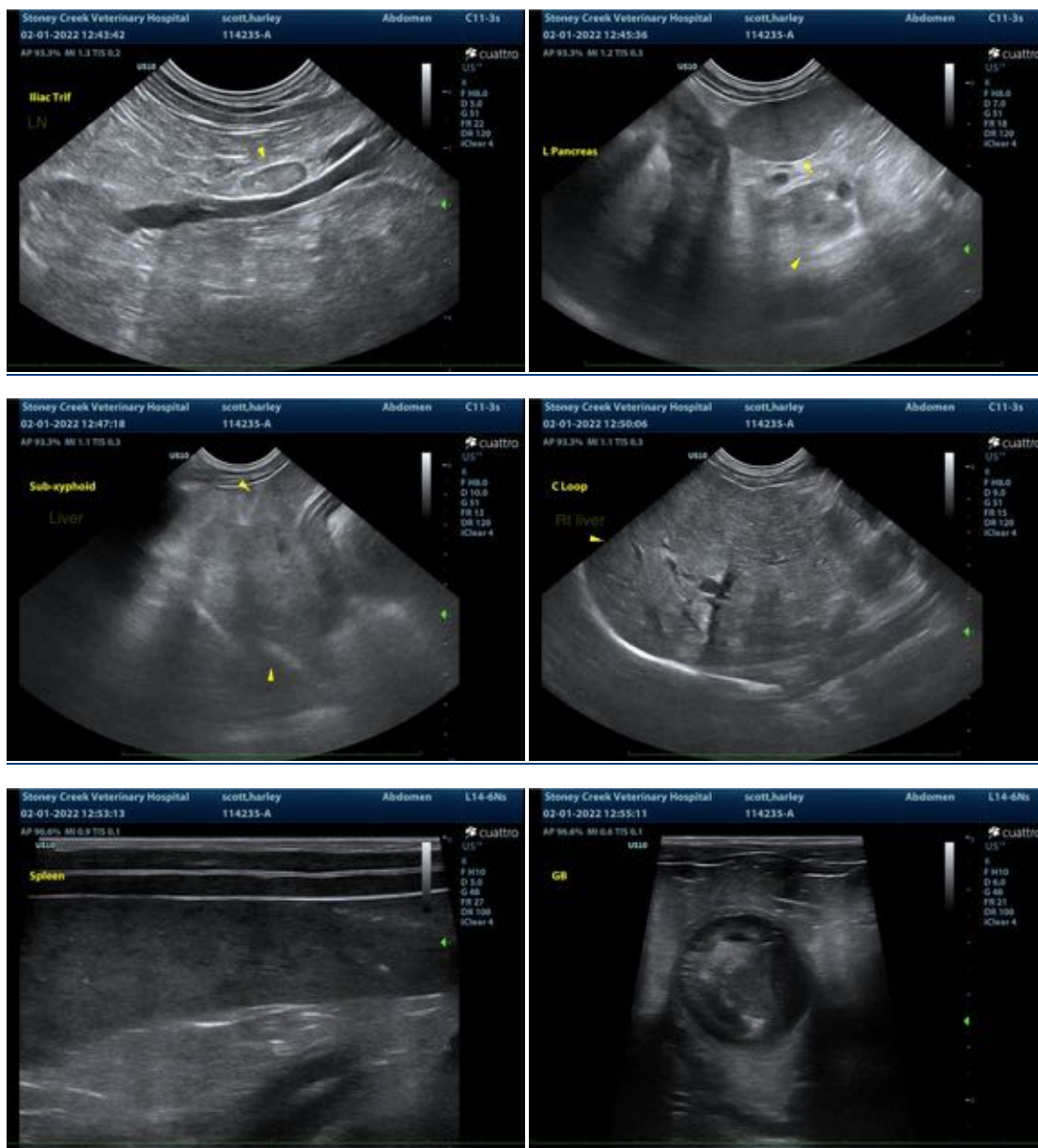
Stoney Creek VH

**REFERRING VET**

Dr. Mingein

**INVOICE  
12937**

**DATE  
2/1/22**



The information and recommendations provided are based on the images presented by the referring veterinarian/sonographer. No evaluation can be communicated regarding pathology that was not visible in the image/video clips provided.

Thank you for this referral. If the clinical or image interpretation does not parallel your findings or if I can be of any further assistance please contact me.

Andrea Nicastro, DVM, Diplomate ACVIM (Small Animal Internal Medicine)

Andrea.nicastro@sonopath.com