

**DATE PRESENTING CLINICAL SIGNS**

12/9/21

History: No clinical signs; recent and prior exam reveals mild to mod. Splenomegaly.

PATIENT

Lab Results: none; CBC & Chem. done in Jan. 2021 wnl.

Date of Previous IntraPet Ultrasound: No previous IntraPet scans.

Cobey Rawls

Sedation: Not required to complete full diagnostic ultrasound.

Stat Report: Not requested.

SPECIES

Canine

ULTRASONOGRAPHIC EXAMINATION OF THE ABDOMEN**BREED****Urinary System**

Greater Swiss Mtn.

The urinary bladder, trigone, and pelvic urethra are normal in thickness and the mucosal surface is smooth. The bladder lumen is moderately distended with anechoic urine. No masses, inflammatory changes or calculi are observed. Ureteral papillae and visualized portion of the proximal urethra, visible to a depth of 2 cm, are normal.

Dog

SEX

Intact Male

The prostate is enlarged (3.75 cm in width) with a normal shape and smooth peripheral contours. The parenchyma is hypoechoic. No focal lesions are observed. The prostatic urethra is not overtly dilated.

AGE

8/19/19

The left kidney presented normal size (8.06 cm in length); normal shape and architecture with smooth peripheral margins. There is a normal 1:3 cortex to medulla ratio with normal corticomedullary distinction. There is no evidence of pyelectasia, nephroliths, infarcts or hydroureter.

WEIGHT

138 Lbs.

The right kidney presented normal size (8.68 cm in length); normal shape and architecture with smooth peripheral margins. There is a normal 1:3 cortex to medulla ratio with normal corticomedullary distinction. There is no evidence of pyelectasia, nephroliths, infarcts or hydroureter.

INTERPRETED BY

Andrea Nicastro, DMV,
Diplomate DACVIM
(Small Animal
Internal Medicine)

Adrenal Glands

The left adrenal gland is normal in length (0.55 cm at cranial pole) (0.44 cm at caudal pole) (3.61 cm in length); with a flattened contour. The glandular echogenicity and detail are unremarkable. Capsule, cortex, and medullary definition are normal. The phrenicoabdominal vein and surrounding vasculature are normal.

IMAGING PERFORMED BY

Andi Parkinson RDMS

The right adrenal gland is normal size (0.80 cm at caudal pole) (2.54 cm in length); normal shape; homogenous parenchyma. The glandular echogenicity and detail are unremarkable. Capsule, cortex, and medullary definition are normal. The phrenicoabdominal vein and surrounding vasculature are normal.

HOSPITAL NAME

Essex Middle River
VH

Spleen

The spleen is normal in size (1.75 cm in width at the level of the hilus) with a normal capsular contour. There is appropriate echogenicity and echotexture. No focal lesions are observed. Splenic vasculature is normal.

REFERRING VET

Dr. Zulty

Liver

The liver is subjectively normal in size with normal contours and structure. The parenchymal echotexture appears coarse. No overt structural evidence of inflammatory, infiltrative or regenerative pathology is evident. Vascular and biliary tracts are of normal volume with no evidence of congestion. No pathological hepatic lymphadenopathy observed.

INVOICE

12887

The gall bladder lumen is moderately distended. The wall is thin and smooth. Luminal contents are anechoic. The cystic and common bile ducts are normal.

Gastrointestinal

The gastric lumen is not distended. The gastric wall is normal in thickness with a normal layering pattern. The small intestinal lumen is not dilated. The small intestinal wall thickness is normal with a normal layering pattern and appropriate mural detail. Discreet masses are not identified. The colonic wall is normal. No obstructive or overt infiltrative disease is noted.

Pancreas

The region of the pancreas is isoechoic relative to surrounding omental fat. No obvious parenchymal abnormalities are observed. There is no evidence of regional inflammation or effusion.

Free Abdomen

The peritoneal cavity is normal. There is no evidence of inflammation or effusion. The abdominal lymph nodes are normal/not visible.

Other

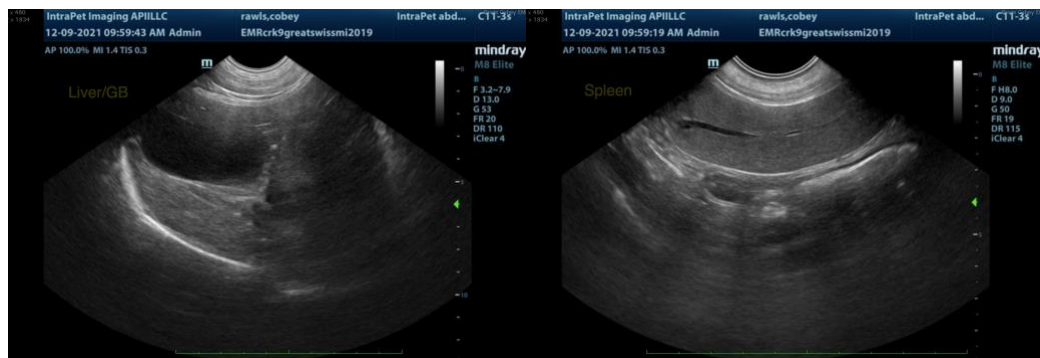
The testicles are subjectively normal in size and symmetrical with homogeneous parenchyma. No focal lesions are observed.

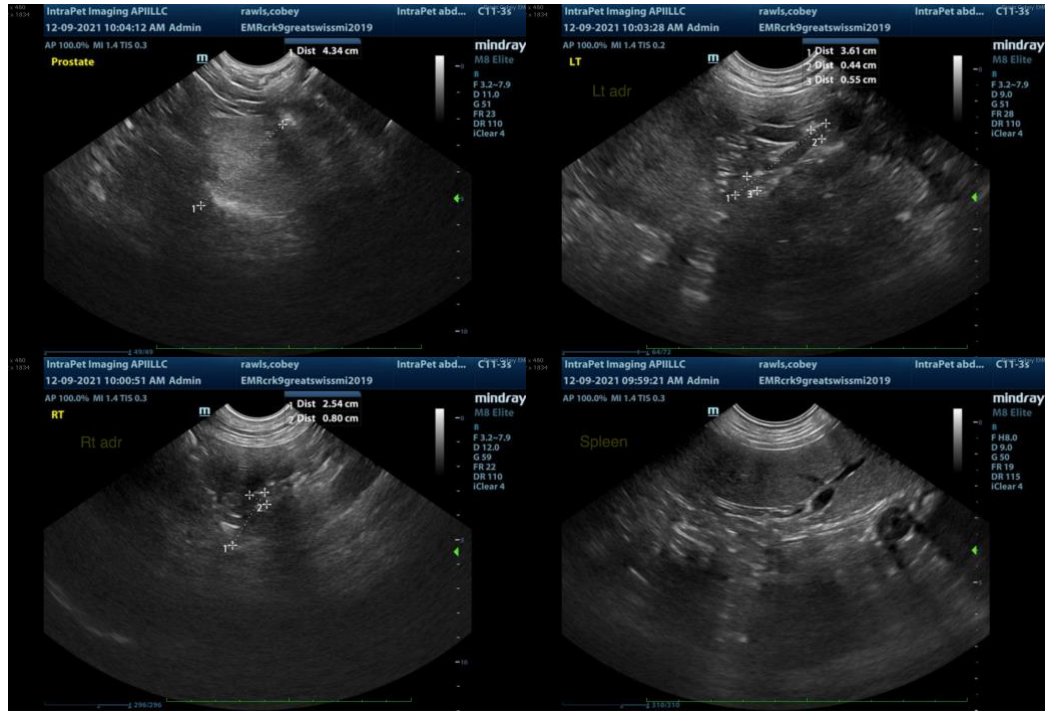
ULTRASONOGRAPHIC FINDINGS

The flattened left adrenal gland may be a normal variant for this patient or may represent early atrophy (i.e., secondary to hypoadrenocorticism). The remainder of the abdomen is unremarkable. There is no obvious evidence of splenomegaly.

INTERPRETATION OF THE FINDINGS & FURTHER RECOMMENDATIONS

- Consider repeating baseline lab work, including a CBC/Chemistry panel, urinalysis and T4 to assess overall metabolic function. If lab work is normal, no further follow up is needed, unless problems arise.





The information and recommendations provided are based on the images presented by the referring veterinarian. No evaluation can be communicated regarding pathology that was not visible in the image/video clips provided.

Thank you for this referral. If the clinical or image interpretation does not parallel your findings or if I can be of any further assistance please contact me.

Andrea Nicastro, DVM, Diplomate DACVIM (Small Animal Internal Medicine)
info@SonoPath.com