

**DATE PRESENTING CLINICAL SIGNS**

12/9/21 History: Was seen 11-26 and lab testing was done, high ALP and RG advised to do Ultrasound to determine if there are any underlying issues due to the fact that it have elevated by 100 % since last lab testing.

PATIENT

BB Rocco

Lab Results: increased ALP.

Date of Previous IntraPet Ultrasound: No previous IntraPet scans.

Sedation: Not required to complete full diagnostic ultrasound.

Stat Report: Not requested.

SPECIES

Canine

ULTRASONOGRAPHIC EXAMINATION OF THE ABDOMEN**BREED**

English Bulldog

Urinary System

The urinary bladder is mildly distended with mostly anechoic urine. The wall is thickened (up to 0.73 cm), particularly in the region of the apex and is irregular. No cystic calculi are observed. The trigone area is prominent, but no obvious mass effect is present. The visible portion of the proximal urethra is normal.

SEX

Spayed Female

The left kidney is normal in size (6.46 cm in length); with a slightly irregular shape. There is a normal 1:3 cortex to medulla ratio with mild loss of corticomedullary distinction. Pinpoint hyperechoic foci are observed within the cortex as well as a few small cortical cysts. Hyperechoic shadowing diverticular foci are present. There is moderate pyelectasia (0.79 cm) in the longitudinal plane. There is no evidence of hydroureter. Renal vasculature is normal.

AGE

8/29/10

WEIGHT

61.7 Lbs.

The right kidney is normal in size (6.25 cm in length); with a normal shape and smooth peripheral contours. There is a normal 1:3 cortex to medulla ratio with mild loss of corticomedullary distinction. Pinpoint hyperechoic foci are observed within the cortex as well as a few small cortical cysts. Hyperechoic shadowing diverticular foci are present. There is moderate pyelectasia (0.42 cm) in the longitudinal plane. There is no evidence of hydroureter. Renal vasculature is normal.

INTERPRETED BY

Andrea Nicastro, DMV,
Diplomate DACVIM
(Small Animal
Internal Medicine)

Adrenal Glands

The left adrenal gland is normal size (0.71 cm at cranial pole) (0.77 cm at caudal pole) (2.95 cm in length); normal shape; homogenous parenchyma. The glandular echogenicity and detail are unremarkable. Capsule, cortex, and medullary definition are normal. The phrenicoabdominal vein and surrounding vasculature are normal.

IMAGING PERFORMED BY

Andi Parkinson RDMS

The right adrenal gland is upper limits of normal size (0.70 cm at cranial pole) (0.85 cm at caudal pole) (2.72 cm in length); with a normal shape and homogenous parenchyma. The glandular echogenicity and detail are unremarkable. Capsule, cortex, and medullary definition are normal. The phrenicoabdominal vein and surrounding vasculature are normal.

HOSPITAL NAME

Everhart VC

Spleen

The spleen is subjectively normal in size (1.73 cm in width at the level of the hilus) with normal curvilinear peripheral contours. The parenchyma is appropriate echogenicity and echotexture. Numerous pinpoint to small linear hyperechoic foci are observed throughout the organ. Splenic vasculature is normal with no evidence of thrombosis.

REFERRING VET

Not Provided

INVOICE

12888

Liver

The liver is subjectively prominent to enlarged with swollen peripheral contours. The parenchyma is isoechoic relative to the spleen. Several ill-defined hypoechoic nodules are observed throughout the organ. Hepatic vasculature and intrahepatic biliary tracts are of normal volume with no evidence of congestion.

The gall bladder lumen is moderately distended. The wall is normal in thickness. A small amount of echogenic debris is suspended within the lumen. The cystic and common bile ducts are dilated. The common bile duct measures 0.51 cm proximally and 0.40 cm distally. It can be followed to the level of the duodenal papilla. There is no obvious evidence of an intraluminal obstruction. The duodenal papilla is normal in size (0.43 cm in width).

Gastrointestinal

The stomach and intestine are free of stasis and exhibit normal peristaltic activity. The gastric lumen is gas distended. The gastric wall and pylorus are normal in thickness with a normal layering pattern. The small intestinal lumen is not dilated. The small intestinal wall thickness is normal with a normal layering pattern and appropriate mural detail. Discreet masses are not identified. The colonic wall is normal. No obstructive or overt infiltrative disease is noted.

Pancreas

The region of the pancreas is isoechoic relative to surrounding omental fat. No obvious parenchymal abnormalities are observed. There is no evidence of regional inflammation or effusion.

Free Abdomen

The peritoneal cavity is normal. There is no evidence of inflammation or effusion. The abdominal lymph nodes are normal/not visible.

ULTRASONOGRAPHIC FINDINGS

Primary Findings

- The diffuse hepatic changes are non-specific and could be consistent with vacuolar hepatopathy, regenerative nodular hyperplasia, and/or age-related remodeling. Inflammatory and infiltrative disease are considered unlikely.
- The urinary bladder wall changes are most consistent with cystitis. However, emerging neoplasia cannot be completely excluded. Correlation with clinical findings is recommended.

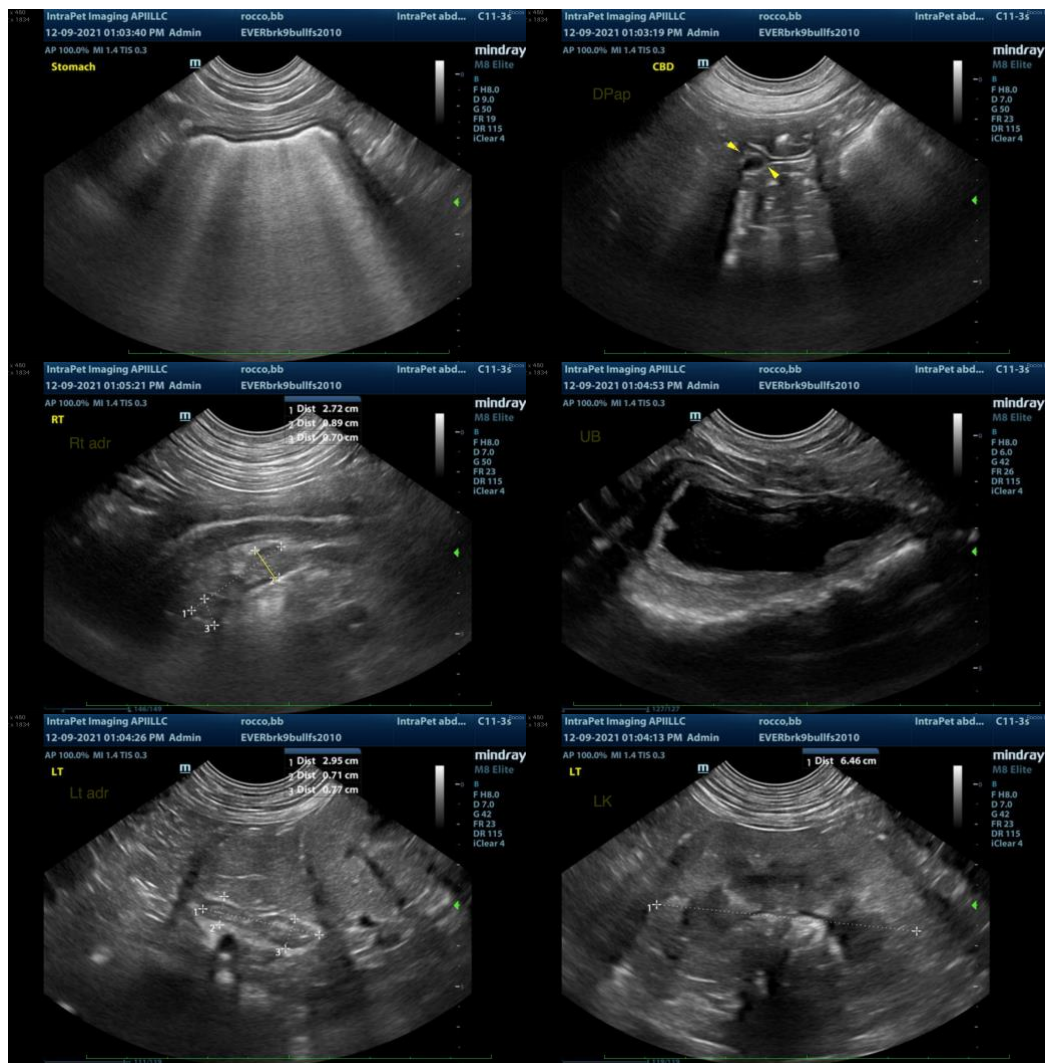
Secondary Findings

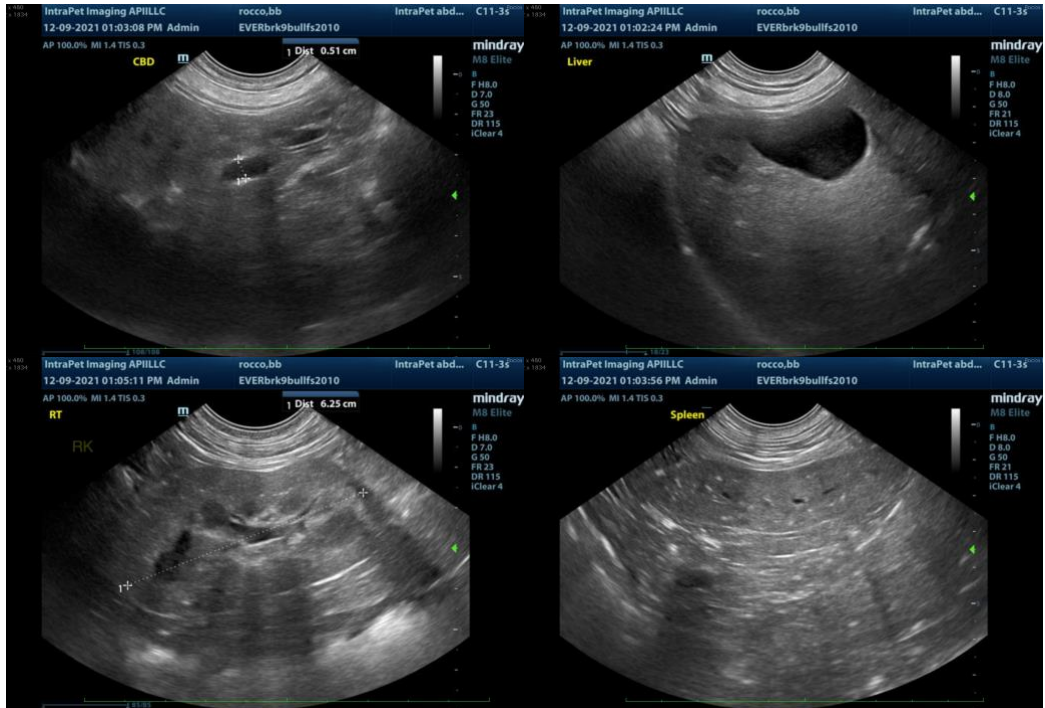
- Splenic dystrophic mineralization. This finding is often seen with endocrinopathies (i.e., Cushing's disease).
- Bilateral age-related renal changes with dystrophic mineralization and pyelectasia

INTERPRETATION OF THE FINDINGS & FURTHER RECOMMENDATIONS

- Consider testing for hyperadrenocorticism with a low-dose dexamethasone suppression test or ACTH stimulation test if clinical signs (i.e., PU/PD) develop in the future.

- Given the urinary bladder wall changes, a urinalysis +/- urine culture and sensitivity are recommended.
- Serial monitoring (i.e., every 3-4 months) of the patients' liver values is recommended. If values continue to increase, repeat abdominal ultrasound +/- hepatic tissue sampling may be warranted.
- Given the patients age, three-view thoracic radiographs should be considered to assess cardiopulmonary status.





The information and recommendations provided are based on the images presented by the referring veterinarian. No evaluation can be communicated regarding pathology that was not visible in the image/video clips provided.

Thank you for this referral. If the clinical or image interpretation does not parallel your findings or if I can be of any further assistance please contact me.

Andrea Nicastro, DVM, Diplomate DACVIM (Small Animal Internal Medicine)
info@SonoPath.com